

**Title:****Endoscopic therapy in disconnected duct syndrome: re-connecting the duct****Authors:**

Luísa Martins Figueiredo, Luis Lourenço, David Horta, Alexandra Martins

DOI: 10.17235/reed.2020.6650/2019

Link: [PubMed \(Epub ahead of print\)](#)

**Please cite this article as:**

Figueiredo Luísa Martins, Lourenço Luis, Horta David, Martins Alexandra. Endoscopic therapy in disconnected duct syndrome: re-connecting the duct. Rev Esp Enferm Dig 2020. doi: 10.17235/reed.2020.6650/2019.



*This is a PDF file of an unedited manuscript that has been accepted for publication. As a service to our customers we are providing this early version of the manuscript. The manuscript will undergo copyediting, typesetting, and review of the resulting proof before it is published in its final form. Please note that during the production process errors may be discovered which could affect the content, and all legal disclaimers that apply to the journal pertain.*

**IPD 6650**

**Endoscopic therapy in disconnected duct syndrome: re-connecting the duct**

Luísa Martins Figueiredo, Luís Lourenço, David Horta and Alexandra Martins

Gastroenterology Department. Hospital Professor Doutor Fernando Fonseca.  
Amadora, Portugal

**Correspondence:** Luísa Martins Figueiredo

e-mail: maria.figueiredo@hff.min-saude.pt

A 61-year-old male patient with a history of acute necrotizing biliary pancreatitis with extensive walled off necrosis was admitted for endoscopic ultrasound-guided transgastric drainage, using a luminal apposing metal stent (LAMS). He underwent a magnetic resonance cholangiopancreatography (MRCP) that showed a 21 x 12 x 13 cm bulky collection in the pancreatic body and tail. The main pancreatic duct was in continuity with the collection described above, suggestive of a disconnected duct syndrome (DDS) (Fig. 1). He underwent three sessions of endoscopic transgastric necrosectomy with complete resolution of the necrosis. A pancreatic fistula was identified during pancreatography before the LAMS was removed. Pancreatic sphincterotomy was performed and a pancreatic plastic stent (7 Fr in diameter; 12 cm length) was placed in order to manage the DDS endoscopically. The tip of the pancreatic stent could be seen inside the pancreatic collection right before removing the LAMS (Fig. 2). Two months later, a computed tomography (CT) showed the resolution of the collection with the pancreatic stent in place. The pancreatic stent was removed and the patient was referred for cholecystectomy. He has remained asymptomatic ever since.

**REFERENCES**

1. Chen Y, Jiang Y, Qian W, et al. Endoscopic transpapillary drainage in disconnected pancreatic duct syndrome after acute pancreatitis and trauma: long-

term outcomes in 31 patients. BMC Gastroenterol 2019;19:54. DOI: 10.1186/s12876-019-0977-1

2. Alsaad AA, Dhannoon SM, Phillips MB. Disconnected pancreatic duct syndrome: a multidisciplinary management dilemma. BMJ Case Rep 2016;2016:bcr2016217099. DOI: 10.1136/bcr-2016-217099

Accepted Article

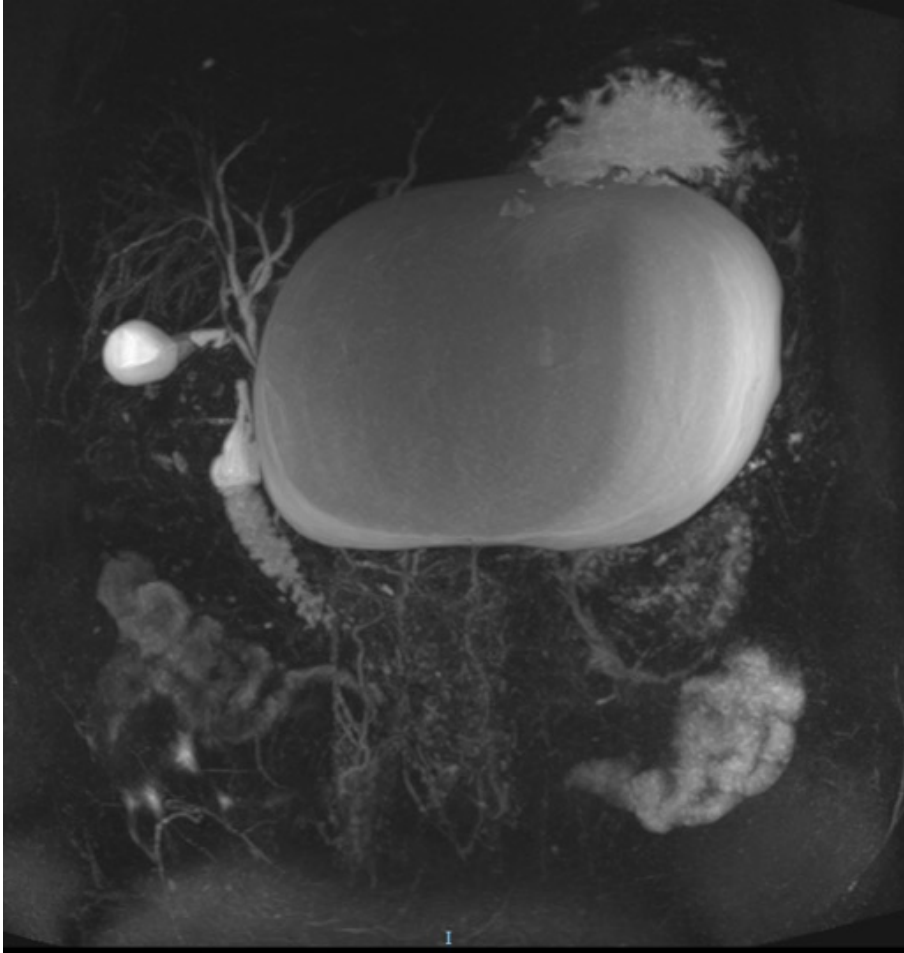


Fig. 1. MRCP showing a massive collection of 21 x 12 x 13 cm replacing the pancreatic body and tail. The main pancreatic duct is in continuity with the collection described above, suggestive of a DDS.

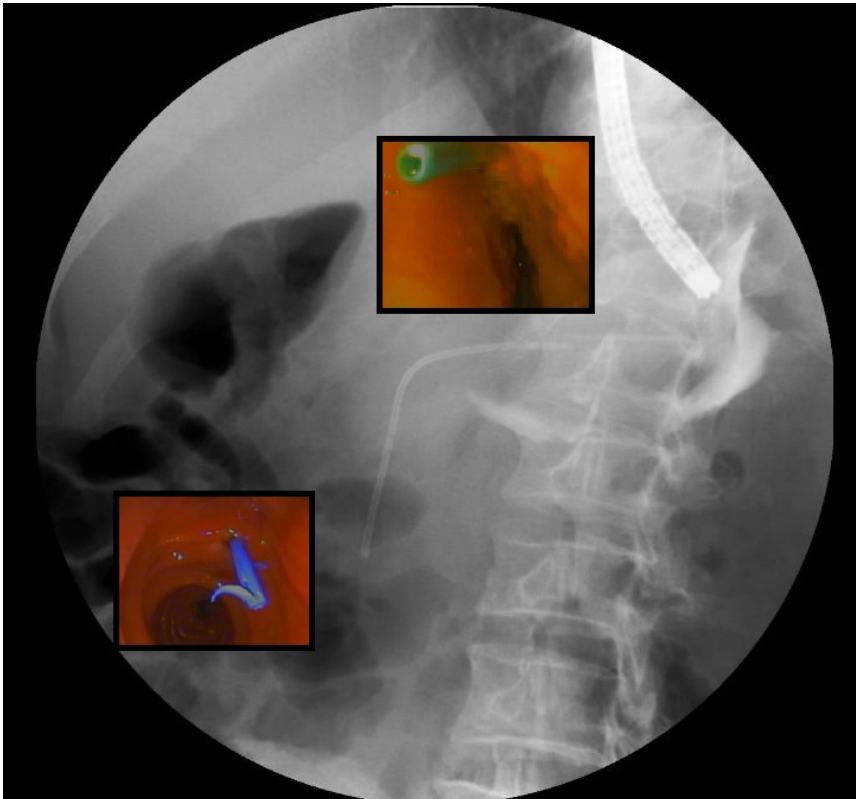


Fig. 2. Image from endoscopic retrograde cholangiopancreatography (ERCP) showing the drainage of contrast through a pancreatic fistula to the necrotic collection (DDS). It was possible to visualize the tip of the pancreatic stent placed by ERCP with an endoscope placed inside the collection.