

CASE REPORTS

Miniprobe endoscopic ultrasonography for the diagnosis of colon hemangiolympangioma

Fernando M. Castro-Poças^{1,2}, Sónia Bernardo¹, Olinda M.G. Lima³ and Marisa D. Santos^{2,4}

¹Ultrasound Unit. Department of Gastroenterology. Santo António Hospital. Porto Hospital Center. Porto, Portugal. ²Institute of Biomedical Sciences Abel Salazar. University of Porto. Porto, Portugal. Departments of ³Pathology and ⁴Surgery. Santo António Hospital. Porto Hospital Center. Porto, Portugal

Received: 26/12/2018 · **Accepted:** 05/02/2019

Correspondence: Sónia Bernardo. Department of Gastroenterology. Santo António Hospital. Porto Hospital Center. Largo do Prof. Abel Salazar. 4099-001 Porto, Portugal. **e-mail:** soniamcb@hotmail.com

ABSTRACT

Hemangiolympangioma is a very rare benign vascular tumor that affects the gastrointestinal tract in less than 1% of cases. We present the case of an asymptomatic 52-year-old female referred for endoscopic colorectal cancer screening. A sub-epithelial pediculated polypoid lesion in the splenic angle of the colon was identified. An endoscopic ultrasonography with a miniprobe was performed, which identified an anechoic lesion in the submucosal layer. Surgery was performed and the histologic findings were compatible with two hemangiolympangioma lesions. This is one of the few cases reported in the literature of hemangiolympangioma diagnosed by miniprobe endoscopic ultrasonography and the first to describe two lesions in the same patient.

Key words: Colon hemangiolympangioma. Endoscopic ultrasonography. Miniprobe.

INTRODUCTION

Hemangiolympangioma is a very rare benign vascular tumor with an incidence of 1.2-2.8/1,000 newborns (1). It occurs predominantly in young patients and less than 1% affect the gastrointestinal tract (1,2). The lack of effective noninvasive diagnostic techniques has led to surgical or endoscopic resection. Endoscopic ultrasonography (EUS) may play a role in the correct diagnosis and management of these lesions. Some authors have suggested that classical and asymptomatic lesions of < 2 cm in size do not require any intervention due to their benign nature (3). We report a case of hemangiolympangioma in the splenic angle of the colon in an asymptomatic patient, diagnosed noninvasively using a miniprobe EUS.

CASE REPORT

An asymptomatic 52-year-old female was referred for endoscopic colorectal cancer screening. A colonoscopy identified a pediculated polypoid lesion in the splenic angle of

the colon and the lesion was covered with normal appearing mucosa (Fig. 1). A miniprobe high frequency (12-MHz) EUS was performed and an anechoic lesion located in the submucosal layer was identified. The lesion was 23 x 13 mm, had well-defined margins with regular borders and an intact *muscularis propria*. It appeared to have one septum, without solid components (Fig. 2A and B) and no adenopathies were identified. The first diagnostic possibility was a colon hemangiolympangioma. A left hemicolectomy was performed due to the size of the lesion and the potential complications such as gastrointestinal bleeding and the fact that the patient required a definitive diagnosis. There were no complications related to the procedure. The macroscopic examination of the excised specimen showed a circumscribed polypoid lesion of 2.5 x 1 x 1 cm that was covered by a normal appearing mucosa. A submucosal nodular area of 0.5 cm was also identified two centimeters above the lesion. This lesion was not detected by colonoscopy and was therefore not evaluated by EUS. The histological examination revealed capillary and lymphatic type blood vessels in the submucosa of both lesions, including thin-walled dilated lymphatic vessels lined by flattened endothelium with an empty lumen (Fig. 3A). Immunohistochemical staining was positive for CD34⁺, CD31⁺ and factor VIII in the endothelial cells of the lymphatic vessels (Fig. 3B-D). There was no evidence of malignancy. A definitive diagnosis of colon hemangiolympangioma was made.

DISCUSSION

Hemangiolympangioma is defined as a proliferation or network of vascular spaces or vessels of a varied nature (from capillaries to lymphatics), which are lined by benign endo-

Castro-Poças FM, Bernardo S, Lima OMG, Santos MD. Miniprobe endoscopic ultrasonography for the diagnosis of colon hemangiolympangioma. *Rev Esp Enferm Dig* 2019;111(6):488-490.

DOI: 10.17235/reed.2019.6144/2018

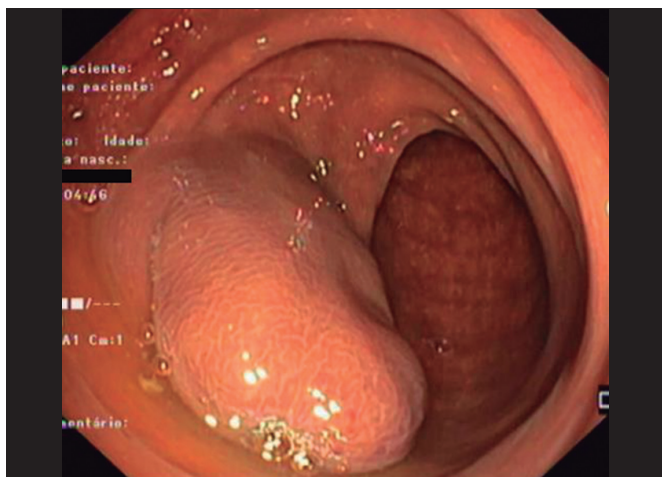


Fig. 1. Colonoscopy showing a sub-epithelial pediculated polypoid lesion that is covered by a normal appearing mucosa.

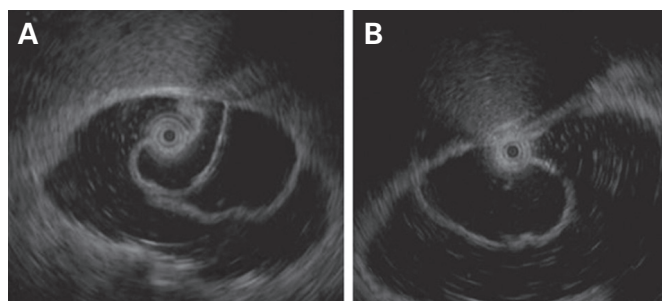


Fig. 2. Endoscopic ultrasonography. A and B. An anechoic lesion located in the submucosal layer, with one septum, well-defined margins and regular borders.

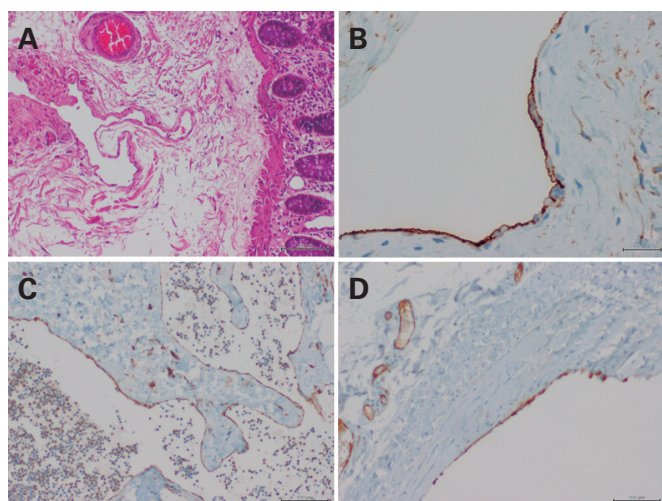


Fig. 3. Histological examination. A. Thin-walled dilated lymphatic vessels lined with flattened endothelium with an empty lumen (HE stain, $\times 100$). B-D. Immunostaining with CD34+ ($\times 400$), CD31+ ($\times 100$) and factor VIII ($\times 100$), respectively, for endothelial cells.

thelial cells and supported by connective tissue (4). Therefore, hemangiolympangiomas are composed of blood and lymphatic vessels with both hemangioma and lymphangioma characteristics (4). These lesions can be classified as primary or secondary. The first are considered as a congenital malformation of the vascular system and can be explained by obstruction of the veno-lymphatic communication (1). Secondary hemangiolympangiomas are usually caused by an injury of lymphatic vessels, which induces inappropriate lymph fluid drainage and abnormal dilatation and mass-like proliferation of lymphatic channels (1,5). The most commonly involved sites are the neck and head in 75% of cases, followed by the axilla in 20% of cases (6). Less than 1% affect the gastrointestinal tract and they are more frequently found in the stomach and small intestine; colonic and rectal lesions are extremely rare (5). However, the routine use of colonoscopy has led to a higher diagnosis rate. Colon hemangiolympangiomas most commonly affect the transverse colon followed by the ascending colon, cecum and descending colon. The colonic lesions are solitary in 95% of the cases (3). To our knowledge, this is the first case described with two lesions. Previously reported cases of colonic hemangiolympangiomas were diagnosed during middle age, as in our patient, with both genders being equally affected (2). The clinical presentation is variable, depending on the size and consequent mass effect or complications. The majority of cases are asymptomatic, according to the scarce literature on the subject (7). However, nonspecific symptoms or signs such as abdominal pain, vomiting, anemia and gastrointestinal bleeding can be present in some cases (2,7). Gastrointestinal obstruction has also been described (8). In our case, the identification of this lesion was an incidental finding, which is in agreement with most reported cases. The diagnosis of hemangiolympangioma can be difficult and there are different diagnostic possibilities such as duplication cysts, benign multicystic peritoneal mesothelioma, lipoma, leiomyoma, gastrointestinal stromal tumors and other submucosal tumors (9,10). It is now possible to perform a non-invasive diagnosis due to the development of EUS. EUS imaging can clearly identify the layer of origin, echogenicity, the presence of septa and the integrity of subjacent layers. This helps to differentiate these lesions from other subepithelial lesions and make a precise diagnosis. Classic EUS findings of hemangiolympangioma in the colon are submucosal anechoic cystic spaces, with or without septations, intact *muscularis propria* and no solid components (3). These characteristics allowed us to make the diagnosis in our case. Miniprobe EUS with higher frequencies also have an important role in the diagnosis, as they allow the accurate differentiation of all the layers of colon wall and the evaluation of small lesions. We used a 12MHz frequency EUS in our case. This is one of the few cases reported in the literature of hemangiolympangioma diagnosed by miniprobe EUS. Some studies have suggested that asymptomatic lesions with a classical appearance and < 2 cm in size can be managed without any intervention due to the benign nature of these lesions (3). However, symptomatic or larger lesions that can result in complications should be resected, either by endoscopic polypectomy or surgery. Surgery was performed in our case, which was agreed with the patient. This was due to the lesion size, the lack of knowledge of the potential malignancy and the frequency and method of surveillance. The histological findings confirmed our diagnosis.

CONCLUSION

The diagnosis of colon hemangiolympangioma can be a challenge. However, miniprobe EUS can be helpful to

achieve a correct diagnosis and for the management of these lesions. The anechoic cystic appearance of a submucosal colonic lesion with septations and intact *muscularis propria* may be sufficient to diagnose this rare entity. Furthermore, EUS can prevent surgical treatment in asymptomatic patients with small lesions.

REFERENCES

1. Chen G, Cui W, Ji Xi-Qing, et al. Diffuse hemolymphangioma of the rectum: a report of a rare case. *World J Gastroenterol* 2013;19:1494-7. DOI: 10.3748/wjg.v19.i9.1494
2. Badipatla K, Chandrala C, Ayyadurai P, et al. Cystic lymphangioma of the colon: endoscopic removal beyond the frontiers of size. *Case Rep Gastroenterol* 2017;11:178-83. DOI: 10.1159/000462966
3. Manoop B, Srinadh A, Pramoda K, et al. Diagnosis of cystic lymphangioma of the colon by endoscopic ultrasound: biopsy is not needed! *Endosc Ultrasound* 2016;5:335-8.
4. Handra-Luca A, Montgomery E. Vascular malformations and hemangiolympangiomas of the gastrointestinal tract: morphological features and clinical impact. *Int J Clin Exp Pathol* 2011;4:430-43.
5. Sylla P, Deutsch G, Luo J, et al. Cavernous, arteriovenous, and mixed hemangioma-lymphangioma of the rectosigmoid: rare causes of rectal bleeding - Case series and review of the literature. *Int J Colorectal Dis* 2008;23:653-8. DOI: 10.1007/s00384-008-0466-4
6. Chung S, Park Y, Jo Y, et al. Asymptomatic lymphangioma involving the spleen and retroperitoneum in adults. *World J Gastroenterol* 2009;15:5620-3. DOI: 10.3748/wjg.15.5620
7. Castro-Poças F, Lobo L, Amaro T, et al. Colon hemangiolympangioma: a rare case of subepithelial polyp. *Int J Colorectal Dis* 2014;1-2.
8. Khade PW, Kalekar T, Shetty D, et al. Lymphangioma causing duodenal obstruction in adult, rare presentation. *Med J DY Patil Univ* 2016;374-6.
9. Gottlieb K, Elkharwily A. Endoscopic ultrasound evaluation of a cystic lymphangioma of the colon. *J Ultrasound Med* 2007;26:1803-4. DOI: 10.7863/jum.2007.26.12.1803
10. Al-Obeed O, Abdulla M. Lymphangioma of the ileocecal valve clinically masquerading as a submucosal small intestinal GIST: report of a case and literature review. *Saudi J Gastroenterol* 2014;262-4.