

Received: 24 March 2020

Revised: 4 August 2020

Accepted: 5 August 2020

DOI: 10.1111/vop.12819

ORIGINAL REPORT

WILEY

Comparison of two rebound tonometers in healthy horses

Minna P. Mustikka¹  | Elina M. Pietilä²  | Anna K. Mykkänen¹ | Thomas S. C. Grönthal¹ 

¹Department of Equine and Small Animal Medicine, University of Helsinki, Helsinki, Finland

²Veterinary Clinic Apex, Helsinki, Finland

Correspondence

Minna P. Mustikka, Department of Equine and Small Animal Medicine, University of Helsinki, P.O. Box 57, Helsinki, FI-00014, Finland.

Email: minna.mustikka@helsinki.fi

Abstract

Objective: To obtain a reference range for evaluation of intraocular pressure (IOP) in horses using Tonovet Plus[®], to compare the IOP readings obtained with Tonovet[®] and Tonovet Plus[®], and to evaluate the repeatability of readings.

Animals studied and Procedures: Intraocular pressure of 30 client-owned horses (60 eyes) with no signs of illness or ocular disease was evaluated using Tonovet[®] and Tonovet Plus[®] rebound tonometers. Horses' mean age was 10.7 (range 6-17) years. Triplicate measurements were performed without using sedatives or local anesthetics, with minimal restraint.

Results: Calculated reference intervals (the CLSI robust method) were 14.4-27.2 mmHg for Tonovet[®] and 16.0-26.1 mmHg for Tonovet Plus[®]. Mean values (\pm standard deviation, SD [\pm coefficient of variation, CV]) obtained with Tonovet Plus[®] (21.6 ± 2.45 mmHg [11.3%]) were on average 0.6 mmHg higher than with Tonovet[®] (21.0 ± 3.14 mmHg [15.0%]), and a negligible statistical difference between the devices was found using the paired sample t test ($P = .049$). The correlation coefficient for the averaged triplicate measurements was 0.73. The average CV was 4.6% and 4.4% for Tonovet[®] and Tonovet Plus[®], respectively.

Conclusions: The repeatability of measurements was very good with both devices. The readings between the two devices differed statistically significantly, but the correlation was considered good and the variation was numerically small, and thus, the difference was considered clinically irrelevant. When monitoring disease process or treatment response in an individual patient, repeated readings are best performed using a similar device to avoid false interpretation of results.

KEY WORDS

equine, intraocular pressure, rebound tonometer, tonometry, Tonovet Plus[®], Tonovet[®]

1 | INTRODUCTION

Assessment of intraocular pressure (IOP) using tonometry is an essential part of a complete ophthalmic examination in horses. Tonometry allows differentiation, diagnostics, and

monitoring of diseases affecting IOP such as uveitis and glaucoma.^{1,2} Alongside the clinical signs associated with these disease entities, tonometry is needed in assessing patients with orbital trauma, blunt force trauma to the globe, lens luxation, suspected decrease in visual function, or blindness.³⁻⁵

This is an open access article under the terms of the Creative Commons Attribution-NonCommercial License, which permits use, distribution and reproduction in any medium, provided the original work is properly cited and is not used for commercial purposes.

© 2020 The Authors. Veterinary Ophthalmology published by Wiley Periodicals LLC on behalf of American College of Veterinary Ophthalmologists

Manometry is the most accurate way to record IOP, but it is invasive and not feasible in clinical settings.¹ Indirect tonometry is a noninvasive method of evaluating IOP by measuring corneal tension.¹ Both applanation and rebound tonometry have been validated in horses, and light hand-held devices are commercially available.⁶⁻⁸ Repeatability plays a major role in accurate interpretation of IOP results when evaluating response to treatment. Previously published reference ranges for IOP in healthy horses are device-specific, and thus, consistency in device used is strongly recommended when monitoring clinical cases.^{1,3,6,7,9,10} Tonovet[®] rebound tonometer (Icare Finland) has been shown to provide accurate results with low interobserver variability in both human and animal patients,¹¹⁻¹³ while Tono-Pen[®] applanation tonometer is more prone to inaccuracy due to incorrect technique.¹² A recent study showed significantly lower inter-user and intra-user variation in unsedated horses and lower intra-user variation in sedated horses with Tonovet[®] than with Tono-Pen[®].¹⁴ In dogs and cats, Tono-Pen[®] has been found to provide accurate readings in the physiological range of IOP, but has a tendency to underestimate IOP in the high range and to overestimate IOP in the low range.^{12,15} On the other hand, Tonovet[®] has shown accuracy outside the physiological range, particularly in the high IOP range.¹²

Rebound tonometry is a noninvasive and clinically applicable method in which the hand-held tonometer device propels a small probe with a round plastic tip to bounce from the surface tension of the cornea and evaluates IOP by the velocity with which the probe bounces back.⁶ Six successful probe-cornea contacts are needed for obtaining one reading. The device automatically discards the highest and the lowest values and calculates the result from the four remaining values using calibration curves set in the software by the manufacturer. Rebound tonometry does not require topical anesthesia and the device is very light, making it an excellent tool in equine ophthalmology, including ambulatory equine practice.⁶

Recently, an updated model of Tonovet[®] rebound tonometer has been introduced to the market. The new Tonovet Plus[®] utilizes similar principles of rebound tonometry as the previous model, but offers improved ease of use with automated sensors ensuring that suitable distance from the cornea and correct plane and position of the device are achieved prior to obtaining readings. The device gives simple indicative messages on a color screen instead of the error codes featured in Tonovet[®]. It also allows the examiner to obtain the six measurements needed for one reading with a single press of the measure button, thus speeding up the measurement process. The software in both Tonovet[®] and Tonovet Plus[®] has a calibration setting for horses.

To the authors' knowledge, no published studies on the use of Tonovet Plus[®] in horses are available to date. A single study performed in rabbits states the accuracy of Tonovet[®]

Plus to be improved compared with Tonovet[®].¹⁶ In addition, a recent study compared the two devices in healthy dogs and found 4.2 mm Hg higher average readings with Tonovet Plus[®] than with Tonovet[®].¹⁷ The objectives of this study were to obtain a reference range for evaluation of IOP in horses using Tonovet Plus[®], to compare the IOP readings obtained with Tonovet[®] and Tonovet Plus[®], and to evaluate the repeatability of readings.

2 | MATERIALS AND METHODS

The study protocol was approved by the Viikki Campus Research Ethics Committee in accordance with legislation concerning animal welfare and research. The animals studied were examined with permission of the owners.

The sample size needed was calculated with Sealed Envelope[™] calculator, setting significance level at 5% and power at 90%. Thirty-two privately owned horses with no signs of illness were examined in their normal stable surroundings with minimal restraint, reducing stress related to the examination and, thus, diminishing the effect of anxiety on IOP.¹³ No sedatives, local anesthetic blocks, or topical ocular anesthesia were used. Two of the horses did not tolerate handling of the head without apparent stress and misbehavior and were thus discarded from the study. A complete ophthalmic examination was performed by a board-certified ophthalmologist (EP) using biomicroscopy (Kowa SL-15, Kowa Company Ltd.) and direct ophthalmoscopy (Heine Beta 200 ophthalmoscope, HEINE Optotechnik GmbH & Co. KG). None of the 30 horses had findings consistent with active ocular disease or other ocular abnormalities potentially affecting the results, and thus were included in the study. Incidental findings interpreted as insignificant regarding the tonometry readings consisted of the following lesions: congenital focal pigment spot in anterior lens capsule ($n = 3$), minor peripheral corneal scar ($n = 2$), minor cystic changes in corpora nigra ($n = 2$), minimal lens opacities ($n = 2$), "bullet hole" chorioretinal lesions ($n = 2$), and focal iris naevi ($n = 1$).

The IOP was evaluated with both Tonovet[®] (Icare Finland Oy) and Tonovet Plus[®] (Icare Finland Oy) tonometers from both eyes in all enrolled horses. The order of performing measurements between the left and right eye and the order of operating the devices were randomly assigned with Latin square design. The head of the horse was maintained in an upright position above heart level for two minutes prior to measurement, avoiding the potential effects of posture on IOP.¹⁸ During the measurement, the upper eyelid was held gently open to avoid interference with the ciliae, unless the horse spontaneously had the eyelids wide open without blinking. Care was taken to avoid digital pressure on the globe and the resulting IOP-elevating effect of eyelid manipulation.¹⁹ A minimum interval of five minutes was maintained between

operating the two devices to minimize any tonographic effect on the results described after repeated rebound tonometry.²⁰ Three consistent IOP readings were recorded in each eye with each tonometer using the species-specific calibration setting for horses. Results showing the display sign of great standard deviation were discarded in accordance with the manufacturer instruction manual, and the measurement was repeated. The disposable probe was replaced between every horse and change of device, and within measurements when such was indicated by a device error message. All measurements were performed by a single observer (MM) and were taken between 9 AM and 3 PM.

The repeatability of each tonometer was assessed by calculating the average of the coefficient of variation (CV) for the triplicate results. For other statistical analyses, triplicate measurements were averaged for each eye and device. Mean values (\pm SD [\pm CV]) were calculated. The measurements from the devices were compared using a Bland-Altman plot. The method differences were plotted against the means of both methods, and the line of equality and 95% confidence intervals for the limits of agreement were calculated. The correlation coefficient was calculated, and the measurement results were plotted in a scatter diagram. A simple linear regression was calculated to predict IOP based on age for each device separately. The paired sample *t* test was used to assess differences between the measurements of the Tonovet[®] and Tonovet Plus[®] devices. The Mann-Whitney U test was used to evaluate differences between the right and left eye measurements. Normal distribution of the differences between

the devices was assessed using the Shapiro-Wilk test. A *P*-value <0.05 was considered significant in all tests. Also, reference interval calculations were performed for both devices using the CLSI robust method (*n* = 60). The Bland-Altman, reference interval calculations, and scatter diagram were performed using MedCalc (v. 19.1. MedCalc software). All other tests were done using IBM SPSS Statistics (v. 25, IBM Corp).

3 | RESULTS

Of the 30 horses included in the study, 26 were warm-blooded and 4 cold-blooded breeds. Nineteen were geldings and 11 mares. The median age of the horses was 10 (range 6-17) years. Data for the difference between the devices were normally distributed (*P* = .774, Shapiro-Wilk; Figure 1). The average CV was 4.6% and 4.4% for the Tonovet[®] and Tonovet Plus[®] devices, respectively.

The correlation coefficient for the averaged triplicate measurements was 0.73 (CI_{95%} 0.58-0.82). The agreement between the two devices is demonstrated in Figure 2. There was a negligible statistical difference between the readings obtained with Tonovet[®] (mean = 21.0 \pm 3.14 mmHg [CV \pm 15.0%]) and Tonovet Plus[®] (mean = 21.6 \pm 2.45 mmHg [CV \pm 11.3%]) devices using the paired sample *t* test (*t*(59) = -2.01, *P* = .049). When the results were analyzed with Wilcoxon signed-rank test, separating the readings from the right and left eye, a

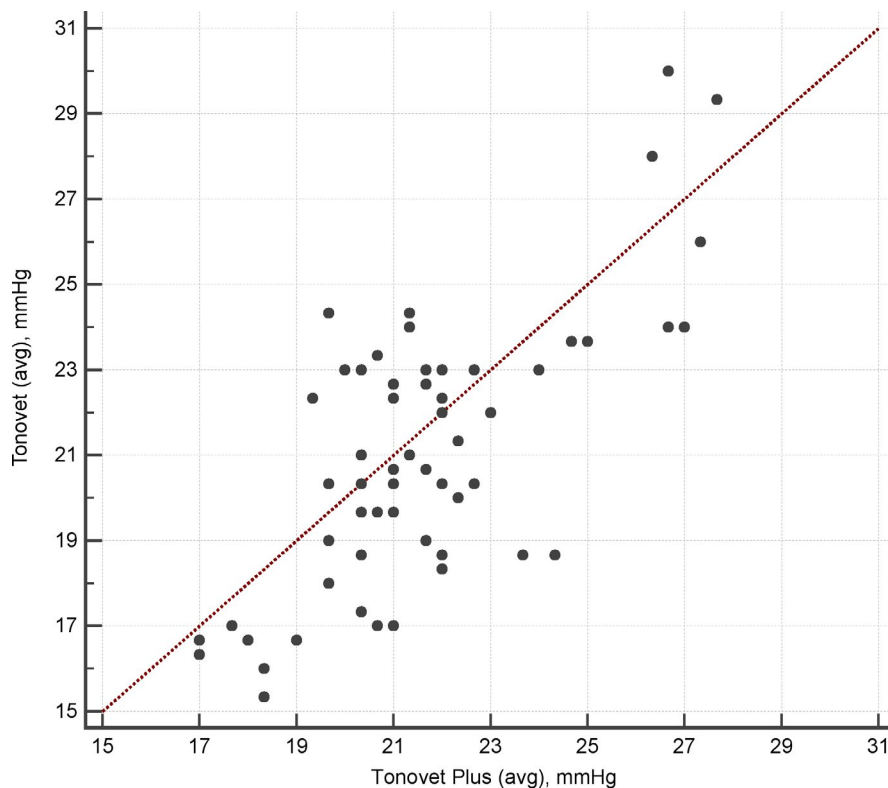


FIGURE 1 Scatter diagram (with line of equality) of the averaged triplicate intraocular pressure readings obtained with Tonovet[®] and Tonovet Plus[®] rebound tonometers

FIGURE 2 Bland-Altman plot of the averaged triplicate intraocular pressure readings obtained with Tonovet® and Tonovet Plus® rebound tonometers

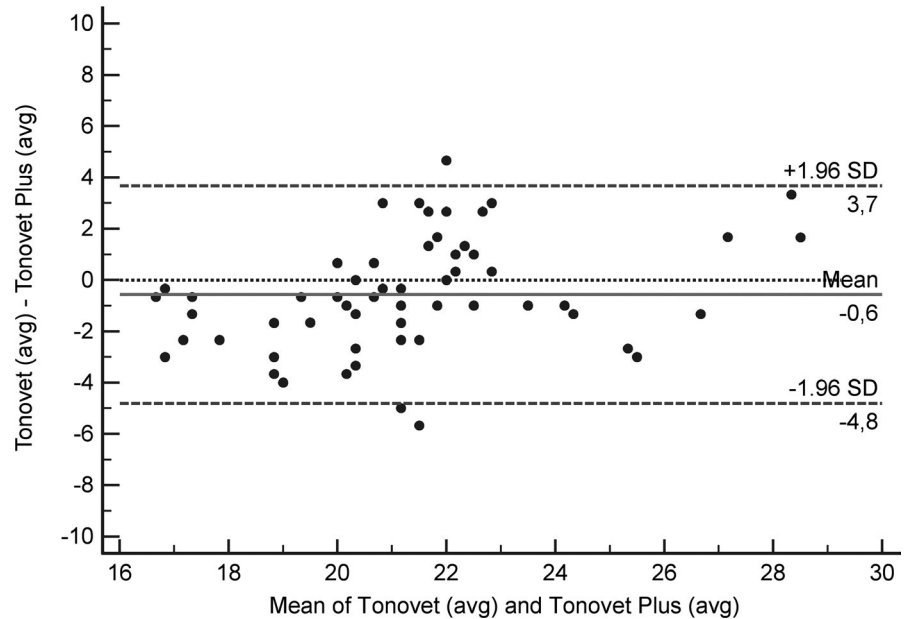


TABLE 1 Intraocular pressure readings (mmHg) obtained with Tonovet® and Tonovet Plus® rebound tonometers (n = 60 eyes total)

Eye	Tonovet® Median (min to max)	Tonovet Plus® Median (min to max)	Tonovet® Mean ± SD	Tonovet Plus® Mean ± SD	P-value*
Right eye	20.3 (15.3-30.0)	21.0 (17.0-26.7)	20.7 ± 3.1	21.4 ± 2.4	.057
Left eye	22.0 (16.0-29.3)	21.3 (17.7-27.7)	21.7 ± 3.2	21.7 ± 2.5	.346

*Wilcoxon signed-rank test, $P \leq .05$.

TABLE 2 Calculated reference intervals (mmHg) for Tonovet® and Tonovet Plus® rebound tonometers using the CLSI robust method

Device	Lower limit (90% CI)	Upper limit (90% CI)
Tonovet®	14.4 (13.3-15.7)	27.2 (25.9-28.4)
Tonovet Plus®	16.0 (15.2-17.1)	26.1 (25.1-27.1)

statistical difference was no longer observed (Table 1). No significant difference existed between measurements from the right and left eyes for either Tonovet® ($P = .233$) or Tonovet Plus® ($P = .656$) device (Mann-Whitney U test). Calculated reference intervals for both tonometers are presented in Table 2. IOP was not associated with age with either device according to linear regression (Tonovet® $P = .347$ ($F(1,28) = 0.914$, $R^2 = .032$); Tonovet Plus® $P = .655$ ($F(1,28) = 0.204$, $R^2 = .007$)).

4 | DISCUSSION

Proper evaluation and care of an ophthalmic patient necessitate the ability to interpret IOP readings correctly. Previous studies have demonstrated variation in tonometrically

evaluated normal IOP range values in horses and in other animals, and thus, it is mandatory for the clinician to consider the information available for the device used.^{6-8,13,21-24}

In this study, the readings between the two devices differed significantly when all 60 eyes were evaluated as a whole, but significance was no longer observed when readings between the devices were evaluated by analyzing the right eyes and the left eyes separately, and a strong linear relationship ($R = .73$) of the readings between the two devices was found. Although statistically significant, the difference was very small, with Tonovet Plus® presenting on average 0.6 mmHg higher readings than Tonovet®. Only healthy horses were enrolled in this study, and thus, the overall variation of readings was not great. Very small numerical changes resulted in differences that are statistically significant, although clinically irrelevant. An average difference of 0.6 mmHg is not likely to have much clinical significance in patient care, as slight inherent variability can never be completely eliminated. Repeated IOP readings tend to differ by 2-3 mmHg or more in humans even when the gold standard method of tonometry is used.²⁵ In our data, the average CV of repeated readings was considered very good for both devices. The tonographic effect of repeated rebound tonometry in equids is unknown and can possibly influence the results. This effect has earlier been detected in mice, but not in children.^{20,26}

The mean readings of 21.0 ± 3.14 mmHg (CV \pm 15.0%) obtained with Tonovet[®] were only slightly lower than readings reported by Knollinger et al⁶ of 22.1 ± 5.9 mmHg (CV \pm 26.7%) in horses without sedation or auriculopalpebral (AP) block, and somewhat lower than readings reported by Holve et al⁹ of 24.3 ± 3.09 mmHg (CV \pm 12.7%) and Lewin et al¹⁴ of 25.4 ± 7 mmHg (CV \pm 27.6%) in horses without sedation but with AP block. The mean readings of 21.6 ± 2.45 mmHg (CV \pm 11.3%) obtained with Tonovet Plus[®] were very close to those reported by Knollinger et al.⁶

Intraocular pressure is known to be lower in infants than in adults and to decrease again with age in humans, dogs, cats, and lions.^{2,25} A recent study suggested that IOP may decrease with age also in miniature donkeys.²² Newborn foals have been reported to have IOP readings similar to adult horses.^{27,28} While in this study, IOP was not found to be associated with age, all of the horses were adults and only two were older than 15 years (data not shown). A larger number of individuals with a wider age range is needed to further evaluate the relationship between age and IOP in horses. The low number of horses and the lack of individuals with abnormal IOP were the major limitations of this study. Future studies are needed to evaluate the function of rebound tonometers in horses in the lower and higher ranges of IOP, as in uveitis and glaucoma.

A previous study in dogs indicates substantial under- and overestimation of IOP with rebound tonometer in patients with corneal pathology. At the same time, this study describes the small diameter of the rebound tonometer probe to enable avoiding suspected falsification of IOP readings caused by focal corneal abnormalities by simply targeting an area of normal cornea.²³ A similar benefit of this property of rebound tonometry has been described in human patients.²⁹ Keeping in mind that misalignment of the rebound tonometer probe will affect the IOP readings,^{23,30} we included two patients with one eye each having a minor peripheral scar in the study, as these lesions were not located in the central part targeted when performing the tonometry. The IOP readings between the two eyes in both of these horses were very symmetrical with both tonometers used, and thus, the minor peripheral corneal scars were considered unlikely to have impacted the readings.

The amplitude of the IOP circadian rhythm in the horse has been found to be approximately 4-5 mmHg, with IOP peaking at the end of the light phase of the day.³¹ In this study, the IOP readings were performed between 9 AM and 3 PM. The horses were living in normal stable surroundings with large windows allowing access of outdoor light. During the time of performing this study, the sun rose at approximately 4 AM and set at approximately 11 PM. Considering the previously stated amplitude of variation³¹ and the fact that the readings were obtained over a 6-hour period during the

light phase of the day, circadian rhythm probably had little influence on the results.

In this study, we chose to perform tonometry without the use of any pharmacological agents, thus avoiding their potential effects on the readings and aiming to describe the readings in healthy eyes in circumstances as natural as possible. Often cooperative horses without any ocular pain allow the clinician to obtain readings without the use of sedation or AP block. It has been initially suggested that AP block could result in more reliable IOP readings in horses by minimizing tension on the globe caused by the eyelids.^{7,32} However, more recent studies have repeatedly found AP block to cause no significant effect on the results or have observed a negligible statistical difference assumed to have no clinical relevance.^{10,22,33} Nevertheless, in an unsedated horse, holding the upper eyelid open to avoid tonometer probe contact with the eyelid cilia is often required. Careless eyelid manipulation has been established to influence the IOP readings, and thus, care should be taken when handling the eyelid.¹⁹ Some individuals tolerate even gentle eyelid manipulation poorly, and the attempts of the horse to squint will cause a similar effect on the IOP. Also, the pull with the strong retractor bulbi muscle in horses may cause a significant transient increase in IOP. These effects are marked in a horse with a painful eye, and in these cases, the use of AP block is recommended.^{1,3,34} On the other hand, not all individuals allow performing the AP block without sedation. Sedation efficiently eases the handling, as it minimizes the head movements and relaxes the patient, decreasing reactivity to eyelid manipulation, but several sedatives have a strong effect on IOP. Acepromazine, detomidine, romifidine, and xylazine have all been shown to decrease IOP significantly, and this should be taken into account in clinical cases.^{9,10,35-37} Sedation also relaxes the horse and results in lowering of the head. Lowering of the head below heart level has been reported to significantly increase the IOP readings in 87% of horses, and thus, supporting the head is necessary when performing tonometry on a sedated horse.¹⁸

The position and attitude of the horse were taken into consideration while performing tonometry in this study. Although it was a priority to make the handling and examination as comfortable as possible, the surroundings and behavior of the horses were impossible to control completely. Thus, demeanor, alertness, and attitude most likely had some impact on IOP readings at different time points. It has been previously noted that physiological variables, such as blood pressure, pulse, respiration, and anxiety, can cause major changes in IOP over short periods and can at least be partially diminished with sedation.¹³ The variation in readings caused by changes in the alertness and attitude of the animal could have been minimized by an acclimation period, during which the horses would have become adapted to rebound tonometry using positive reinforcement as described by Von Zup et al.³⁸

In dogs, misalignment of the rebound tonometer during measurement has been found to result in underestimation of IOP.^{24,30} The equine cornea is larger, and thus, central placement is easy to achieve, but in an unsedated horse, the height of the patient relative to the height of the examiner can occasionally pose challenges and lead to misalignment of the device. While performing this study, Tonovet Plus[®] was subjectively easier than Tonovet[®] for obtaining accurate readings in unsedated horses without AP block, as the improved features for guiding the device position and measuring with a single button press facilitated a faster procedure. Right-handedness appears to make the IOP measurement more difficult on the left eye, presumably due to the position of the left hand holding the eyelids open in relation to the equine head conformation. This could explain the difference between mean and median readings of the right and left eye, observed especially while using Tonovet[®]. A similar difference, albeit to a greater degree, was suspected to be examiner-related in a previous report of Tonovet[®] in cattle, sheep, and goats.³⁹

In conclusion, Tonovet Plus[®] is an updated model of Tonovet[®] with some new features aimed at increasing comfort during use. The difference in readings between the two devices is not likely to be significant in a clinical setting. Nevertheless, in order to avoid false interpretation of results, the device used should always be taken into consideration and a similar device preferred when monitoring the disease process or treatment response in an individual patient.

ACKNOWLEDGMENTS

The authors thank the Riding School of Kauniainen for allowing the examinations included in this study to be performed on its horses.

CONFLICT OF INTERESTS

The authors thank Icare Finland Oy for providing the Tonovet Plus[®] device and the probes needed to perform this study. Icare Finland did not influence study design or the collection, analysis, or interpretation of data. None of the authors has a financial relationship with Icare Finland Oy that could influence or bias the study content.

ORCID

Minna P. Mustikka  <https://orcid.org/0000-0002-7180-1660>

Elina M. Pietilä  <https://orcid.org/0000-0002-6281-163X>

Thomas S. C. Grönthal  <https://orcid.org/0000-0001-8339-5818>

REFERENCES

1. Stoppini R, Gilger BC. Equine ocular examination basic techniques. In: Gilger BC, ed. *Equine Ophthalmology*, 3rd edn. Ames, IA: John Wiley & Sons; 2017:1-39.
2. Featherstone HJ, Heinrich CL. Ophthalmic examination and diagnostics. In: Gelatt KN, Gilger BC, Kern TJ, eds. *Veterinary Ophthalmology*, 5th edn. Ames, IA: John Wiley & Sons; 2013:533-702.
3. Michau TM. Equine glaucoma. *Vet Clin North Am Equine Pract.* 2017;33:519-540.
4. Gilger BC. Equine ophthalmology. In: Gelatt KN, Gilger BC, Kern TJ, eds. *Veterinary Ophthalmology*, 5th edn. Ames, IA: John Wiley & Sons; 2013:1561-1609.
5. Wilkie DA, Gemensky-Metzler AJ, Lassaline M, Brooks DE. Glaucoma. In: Gilger BC, ed. *Equine Ophthalmology*, 3rd edn. Ames, IA: John Wiley & Sons; 2017:453-468.
6. Knollinger AM, La Croix NC, Barrett PM, Miller PE. Evaluation of a rebound tonometer for measuring intraocular pressure in dogs and horses. *J Am Vet Med Assoc.* 2005;227:224-248.
7. Miller PE, Pickett JP, Majors LJ. Evaluation of two applanation tonometers in horses. *Am J Vet Res.* 1990;51:935-937.
8. Dziezyc J, Millichamp NJ, Smith WB. Comparison of applanation tonometers in dogs and horses. *J Am Vet Med Assoc.* 1992;201:430-433.
9. Holve DL. Effect of sedation with detomidine on intraocular pressure with and without topical anesthesia in clinically normal horses. *J Am Vet Med Assoc.* 2012;240:308-311.
10. van der Woerd A, Gilger BC, Wilkie DA, Strauch SM. Effect of auriculopalpebral nerve block and intravenous administration of xylazine on intraocular pressure and corneal thickness in horses. *Am J Vet Res.* 1995;56:155-158.
11. Abraham LM, Epasinghe NCR, Selva D, Casson R. Comparison of the ICare[®] rebound tonometer with the Goldmann applanation tonometer by experienced and inexperienced tonometrists. *Eye.* 2008;22:503-506.
12. McLellan GJ, Kemmerling JP, Kiland JA. Validation of the TonoVet[®] Rebound tonometer in normal and glaucomatous cats. *Vet Ophthalmol.* 2013;16:111-118.
13. Görig C, Coenen RTI, Stades FC, Djajadiningrat-Laanen SC, Boevé MHB. Comparison of the use of new handheld tonometers and established applanation tonometers in dogs. *Am J Vet Res.* 2006;67:134-144.
14. Lewin AC, Liu C-C, Camacho-Luna P, Alling C, Carter RT. Inter-user and intra-user variation of two tonometers in horses. *Equine Vet J.* 2019;00:1-5.
15. Priehs DR, Glenwood GG, Whitley RD, Moore LE. Evaluation of three applanation tonometers in dogs. *Am J Vet Res.* 1990;51:1547-1550.
16. Gloe S, Rothering A, Kiland JA, McLellan GJ. Validation of the Icare[®] TONOVET plus rebound tonometer in normal rabbit eyes. *Exp Eye Res.* 2019;185:107698.
17. Ben-Shlomo G, Muirhead SF. Estimation of intraocular pressure in normal canine eyes utilizing the newly introduced TonoVet Plus and TonoPen Avia, and their comparison to the established TonoVet. *Vet Ophthalmol.* 2020. <https://doi.org/10.1111/vop.12747>
18. Komaromy AM, Garg CD, Ying GS, Liu C. Effect of head position on intraocular pressure in horses. *Am J Vet Res.* 2006;67:1232-1235.
19. Klein HE, Krohne SG, Moore GE, Mohamed AS, Stiles J. Effect of eyelid manipulation and manual jugular compression on intraocular pressure measurement in dogs. *J Am Vet Med Assoc.* 2011;238:1292-1295.
20. Morris CA, Crowston JG, Lindsey JD, Danias J, Weinreb RN. Comparison of invasive and non-invasive tonometry in the mouse. *Exp Eye Res.* 2006;82:1094-1099.

21. Andrade SF, Palozzi RJ, Giuffrida R, de Campos RJ, Santos Gde C, Fukui RM. Comparison of intraocular pressure measurements between the Tono-Pen XL® and Perkins® applanation tonometers in dogs and cats. *Vet Ophthalmol.* 2012;15:14-20.
22. Hibbs CD, Barrett PM, Dees DD. Intraocular pressure reference intervals in eyes of clinically normal miniature donkeys (*Equus africanus asinus*). *Vet Ophthalmol.* 2019;22:24-30.
23. Von Spiessen L, Karck J, Rohn K, Meyer-Lindenberg A. Clinical comparison of the TonoVet® rebound tonometer and the Tono-Pen Vet® applanation tonometer in dogs and cats with ocular disease: glaucoma or corneal pathology. *Vet Ophthalmol.* 2015;18:20-27.
24. Tofflemire KL, Wang C, Jens JK, Ellinwood NM, Whitley RD, Ben-Shlomo G. Evaluation of three hand-held tonometers in normal canine eyes. *Vet J.* 2017;224:7-10.
25. Allingham RR, Damji KF, Freedman SF, Rhee DJ, Shields MB. Intraocular pressure and tonometry. In: RR Allingham, MB Shields, eds. *Shields Textbook of Glaucoma*, 6th edn. Philadelphia, PA: Wolters Kluwer/Lippincott Williams & Wilkins Health cop; 2011:24-40.
26. Dosunmu EO, Marcus I, Tung I, Thiamthat W, Freedman SF. The effect of repeated measurements and the use of topical anesthetic on rebound tonometry values in children. *J AAPOS.* 2014;18:619-621.
27. Labelle AL, Hamor RE, Townsed WM, et al. Ophthalmic lesions in neonatal foals evaluated for nonophthalmic disease at referral hospitals. *J Am Vet Med Assoc.* 2011;239:486-492.
28. Leiva M, Pena T, Monreal L. Ocular findings in healthy newborn foals according to age. *Equine Vet Educ.* 2010;23:40-45.
29. Rosentreter A, Athanasopoulos A, Schild A, Lappas A, Cursiefen C, Dietlein T. Rebound, applanation, and dynamic contour tonometry in pathologic corneas. *Cornea.* 2013;32:313-318.
30. De Oliveira JK, Montiani-Ferreira F, Williams DL. The influence of the tonometer position on canine intraocular pressure measurements using the Tonovet® rebound tonometer. *Open Vet J.* 2018;8:68-76.
31. Bertolucci C, Giudice E, Fazio F, Piccione G. Circadian intraocular pressure rhythms in athletic horses under different lightning regime. *Chronobiol Int.* 2009;26:348-358.
32. Trim CM, Colbern GT, Martin CL. Effect of xylazine and ketamine on intraocular pressure in horses. *Vet Rec.* 1985;117:442-443.
33. Diehl K, Bowden AC. Effect of auriculopalpebral nerve block on equine intraocular pressure measured by rebound tonometry (TonoVet®). *Vet Ophthalmol.* 2020;23(2):368-373.
34. Wilkie DA, Gilger BC. Equine glaucoma. *Vet Clin North Am Equine Pract.* 2004;20:381-391.
35. McClure JR Jr, Gelatt KN, Gum GG, Manning JP. The effect of parenteral acepromazine and xylazine on intraocular pressure in the horse. *Vet Med Small Anim Clin.* 1976;32:1727-1730.
36. Stine JM, Michau TM, Williams MK, Kuebelbeck KL, Stengard ME. The effects of intravenous romifidine on intraocular pressure in clinically normal horses and horses with incidental ophthalmic findings. *Vet Ophthalmol.* 2014;17:134-139.
37. Marzok MA, El-Khodery SA, Oheida AH. Effect of intravenous administration of romifidine on intraocular pressure in clinically normal horses. *Vet Ophthalmol.* 2014;17:149-153.
38. Von Zup M, Lassaline M, Kass PH, Miller PE, Thomas SM. Effects of 0.2% brimonidine and 0.2% brimonidine-0.5% timolol on intraocular pressure and pupil size in normal equine eyes. *Equine Vet J.* 2017;49:810-814.
39. Peche N, Eule JC. Intraocular pressure measurements in cattle, sheep, and goats with 2 different types of tonometers. *Can J Vet Res.* 2018;82:208-215.

How to cite this article: Mustikka MP, Pietilä EM, Mykkänen AK, Grönthal TSC. Comparison of two rebound tonometers in healthy horses. *Vet Ophthalmol.* 2020;23:892-898. <https://doi.org/10.1111/vop.12819>