


Contents lists available at [ScienceDirect](http://www.sciencedirect.com)

JPRAS Open

journal homepage: <http://www.journals.elsevier.com/jpras-open>

## Original Article

# Preoperative estimation of cosmetic outcomes after immediate breast reconstruction with extended latissimus dorsi flap: A simple prediction model

T. Manie <sup>a,\*</sup>, A. Farahat <sup>a</sup>, T. Hashem <sup>a</sup>, M.M.G. Youssef <sup>a</sup>,  
A.R. Abdalwahab <sup>a</sup>, I. Elattar <sup>b</sup>, T.S. El-Baradie <sup>c</sup><sup>a</sup> Unit of Breast Surgery, National Cancer Institute, Cairo University, Cairo, Egypt<sup>b</sup> Department of Biostatistics and Cancer Epidemiology, National Cancer Institute, Cairo University, Cairo, Egypt<sup>c</sup> Department of Surgical Oncology, National Cancer Institute, Cairo University, Cairo, Egypt

## ARTICLE INFO

*Article history:*

Received 20 May 2017

Accepted 23 September 2017

Available online 13 October 2017

*Keywords:*

Mastectomy

Reconstruction

Cosmetic outcomes

Prediction

## ABSTRACT

**Background:** The extended latissimus dorsi (ELD) flap can provide adequate volume for breast reconstruction without an implant. The aim of this study was to identify a simple method to estimate preoperatively if the ELD flap would provide enough volume for breast reconstruction and good cosmetic outcome. The proposed model was based on correlating the preoperative body mass index (BMI) and breast cup size.

**Methods:** This retrospective cohort study included 64 patients who underwent immediate breast reconstruction with ELD at the National Cancer Institute, Cairo University, between January 2014 and January 2016. Preoperative breast cup size and patients' BMI were recorded. The primary end point was cosmetic outcome score assessed by three independent breast surgeons and the patients. Correlation analysis was performed between the preoperative factors and final cosmetic outcome.

**Results:** Sixty-four patients underwent immediate reconstruction following skin-sparing mastectomy. BMI range was 23–38 kg/m<sup>2</sup> with a median of 28. All patients with cup size A had aesthetically

\* Corresponding author. Unit of Breast Surgery, National Cancer Institute, Cairo University, Fom El Khalig Square, 11796, Cairo, Egypt.

E-mail address: [tamer.manie@nci.cu.edu.eg](mailto:tamer.manie@nci.cu.edu.eg) (T. Manie).

<https://doi.org/10.1016/j.jpra.2017.09.005>

2352-5878/© 2017 The Author(s). Published by Elsevier Ltd on behalf of British Association of Plastic, Reconstructive and Aesthetic Surgeons. This is an open access article under the CC BY-NC-ND license (<http://creativecommons.org/licenses/by-nc-nd/4.0/>).

pleasing results. As the breast cup size increased, the favorable cosmetic outcomes were noted with lower BMI. All patients with BMI higher than 33 had unfavorable results.

**Conclusion:** Favorable cosmetic outcomes are expected after ELD reconstruction in patients with cup size A regardless of the BMI. As the breast cup size increases, favorable cosmetic outcomes are expected in patients with lower BMI than in those with higher BMI. At a BMI of 34, no favorable cosmetic outcomes are expected. The prediction model will be validated in a prospective study.

© 2017 The Author(s). Published by Elsevier Ltd on behalf of British Association of Plastic, Reconstructive and Aesthetic Surgeons. This is an open access article under the CC BY-NC-ND license (<http://creativecommons.org/licenses/by-nc-nd/4.0/>).

## Introduction

Immediate breast reconstruction following mastectomy improves the patient's quality of life and psychological well-being.<sup>1</sup> Skin- and nipple-sparing mastectomies are associated with superior aesthetic results and increased patient satisfaction.<sup>2,3</sup> Breast reconstruction with autologous tissue leads to a higher degree of patient satisfaction than implant-based reconstruction.<sup>4,5</sup>

A common method of autologous reconstruction is the pedicled latissimus dorsi flap. It is a versatile flap with reliable blood supply and small rate of complications.<sup>6,7</sup> When the latissimus muscle alone is insufficient to provide adequate volume, it is combined with an implant. The many risks associated with breast implants include capsular contracture, infection, migration, and implant loss.<sup>8,9,10</sup>

To avoid implants and associated complications, the extended latissimus dorsi (ELD) flap is used. This was first described by Hokin in 1983 and included addition of fat from the lumbar region to the flap.<sup>11</sup> Several modifications have been described for the ELD to help increase its volume.<sup>12,13,14,15</sup>

In low- and middle-income countries, such as Egypt, the ELD remains the main workhorse for breast reconstruction as a cheaper but viable alternative to costly implants and acellular dermal matrices (ADMs).

It is important for the surgeon planning for breast reconstruction to be able to predict the cosmetic outcomes with different methods.

To the best of our knowledge, few studies have addressed the question of preoperative prediction of cosmetic outcomes associated with the ELD.

The aim of this study was to determine if preoperative BMI and preoperative bra cup size were predictors of cosmetic outcomes following immediate ELD breast reconstruction.

## Methods

This was a retrospective cohort study that included 64 female breast cancer patients who underwent skin- or nipple-sparing mastectomy with immediate reconstruction using ELD flap at the National Cancer Institute, Cairo University (Egypt), between January 2014 and January 2016.

The BMI was calculated preoperatively by dividing the body weight in kilograms by the square of the height in meters. The breast cup size information was obtained from the patients.

All patients had given a written informed consent after explaining the procedure to be done.

All patients had skin- or nipple-sparing mastectomy and immediate reconstruction with ELD.

Medical photography was obtained preoperatively, immediately postoperatively, and again after 2 months.

At 2 months post-operatively, the cosmetic outcome was assessed using the photographs by three different breast surgeons independently, and a score was given according to the Harris scale.<sup>16</sup> Similarly, the patients were asked to give a similar score independently. A mean score was calculated for each case. The scores were obtained before the patient underwent adjuvant radiotherapy.

### Statistical methods

Data management and analysis were performed using Statistical Package for Social Sciences (SPSS) vs. 23.

Numerical data were explored for normality using Kolmogorov-Smirnov test and Shapiro-Wilk test. Exploration of data revealed that the collected values were not normally distributed. Comparisons between the two groups were done by Mann-Whitney test. All p-values are two-sided. P-values < 0.05 were considered significant.

Harris scale included the following scoring points:

1. Excellent: Treated breast nearly identical to untreated breast
2. Good: Treated breast slightly different than untreated
3. Fair: Treated breast clearly different from untreated but not seriously distorted
4. Poor: Treated breast seriously distorted

### Results

Sixty-four patients underwent immediate breast reconstruction with ELD flap at the National Cancer Institute, Cairo University, between January 2014 and January 2016.

The median patient age was 47 years (range 32–56).

Thirty-three patients underwent skin-sparing mastectomy, while 31 had nipple-sparing mastectomy. Patient's data for both procedures are listed in [Table 1](#). The mean operating time was 4.6 h, and the mean hospital stay was 3.4 days.

The median patient BMI was 28 kg/m<sup>2</sup> (range 23–38). The patient breast cup sizes included size A (5 patients), size B (30 patients), size C (18 patients), and size D (11 patients). [Table 2](#).

The mean cosmetic outcome scores for each cup size are shown in [Table 3](#).

Scores of 1 and 2 were grouped and labeled as “favorable,” while scores of 3 and 4 were labeled “unfavorable” for ease of statistical analysis.

Preoperative breast cup size A was associated with the highest percentage of favorable cosmetic outcomes scores (100%). The favorable scores were 72% with breast cup C, 67% with cup B, and 36% with cup D.

**Table 1**  
Characteristics of the patients.

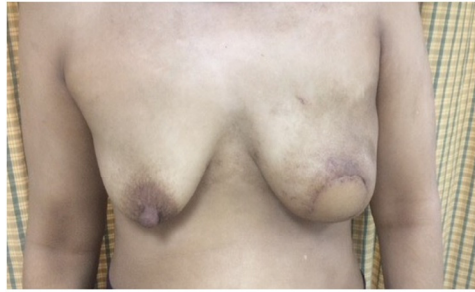	SSM (n = 33)	NSM (n = 31)
Mean age	50 (36–56)	44 (32–52)
Incision	Periareolar 33	Periareolar 16 Inferolateral 10 Lateral radial 5
Mean BMI	31 (25–38)	27 (23–33)
Cup size		
A	1	4
B	10	20
C	12	6
D	10	1

**Table 2**  
Breast cup sizes of the patients.

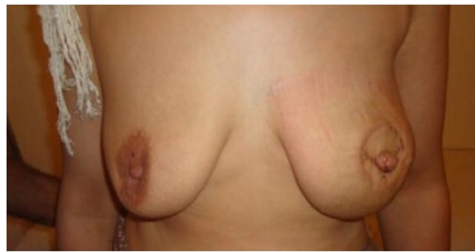	Cup A	Cup B	Cup C	Cup D
Number of patients	5	30	18	11
BMI range and median	23–28 (24)	23–34 (27)	26–35 (31)	31–38 (34)

**Table 3**  
Mean cosmetic score for each cup size.

		Cup A	Cup B	Cup C	Cup D
Mean score	1	4	6	5	2
	2	1	14	8	2
	3	0	9	4	2
	4	0	1	1	5



**Figure 1.** Favorable outcome in a patient with BMI 27 and cup A.



**Figure 2.** Favorable outcome in a patient with BMI 28 and cup B.

With breast cup size A, the BMI did not affect the cosmetic outcome score. All the patients had favorable scores. [Figure 1](#).

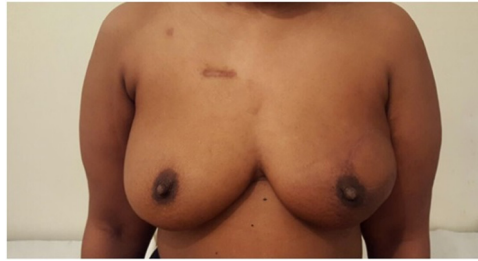However, with breast cup size B, favorable scores were observed when the BMI ranged between 27 and 31. Similarly, favorable scores were observed with breast cup size C at a BMI of 29–32 and with cup size D at BMI of 31–33. [Figures 2 and 3](#).

At a BMI higher than 33, regardless of the cup size, unfavorable scores were observed. [Figure 4](#).

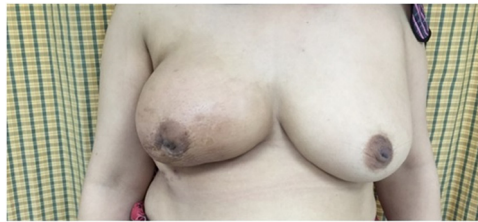There was a significant differences in the BMI between favorable and unfavorable cosmetic outcome scores in patients with preoperative breast cup size C,  $p$ -value = 0.019. [Table 4](#).

### Complications

The most common complication encountered was donor site seroma, which occurred in 43 patients (67%) and was treated with repeated aspirations. Donor site superficial wound infection occurred in 6 patients (9.3%) and was treated conservatively with antibiotics. Donor site wound necrosis occurred in 4 patients (6.25%). All had a BMI more than 33. All were taken back to theatre for debridement and closure. Four patients who underwent nipple-sparing mastectomy (6.25%) had NAC necrosis, but



**Figure 3.** Favorable outcome in a patient with BMI 32 and cup C.



**Figure 4.** Unfavorable outcome in a patient with BMI 35 and cup D.

**Table 4**  
BMI and cup size correlation to cosmetic score.

	Mean evaluation						P-value
	Favorable score (1–2)			Unfavorable score (3–4)			
	n	Mean BMI	SD	n	Mean BMI	SD	
<b>Cup A</b>	5	25.3	2.2				
<b>Cup B</b>	20	27.5	1.6	10	27.4	3.2	0.328
<b>Cup C</b>	13	29.3	2.9	5	33.4	1.2	0.019
<b>Cup D</b>	4	33.3	3.2	7	36.1	5.1	

none required re-operation. There were no mastectomy flap necrosis or ELD flap loss. No patient had fat necrosis.

## Discussion

The ELD is one of the most common methods for immediate breast reconstruction. It is a large versatile flap that can be molded under the breast skin envelope to replace excised breast tissue, making it suitable for the reconstruction of ptotic and non-ptotic breasts.

It is the most widely used method for autologous breast reconstruction in our institute.

In addition to its economic feasibility in low- and middle-income countries compared to implants and ADMs, it can provide the necessary volume to achieve symmetry in patients with large breasts.

According to data from the World Health Organization, the mean BMI of Egyptian females is 30, with 76% of the population overweight and 48% obese.<sup>17</sup> The patients in this study had a mean BMI of 29. The presence of additional fat increases the muscle volume and makes our patients good candidates for ELD reconstruction. The increase in the volume from the additional dorsal fat improves the appearance and natural feel of the reconstructed breast.

The ELD reconstruction avoids the complications associated with implants and ADMs and decreases the rate of secondary and revision surgery. In a study by Tarantino et al, half of the 68 patients that underwent immediate breast reconstruction by using a latissimus flap combined with an implant had to undergo another operation to change or remove the implant.<sup>18</sup>

Most of the patients in our population do not want to have more than one surgical procedure and would rather prefer to have one operation with the best possible cosmetic outcomes. This renders the ELD option a more attractive method of reconstruction for the population of our study.

In this study, we aimed to identify a simple method to predict preoperatively if the ELD muscle flap can provide enough volume for total breast reconstruction following skin- or nipple-sparing mastectomy. The prediction method is based on the correlation between the BMI and breast cup size.

We acknowledge that the Breast Q questionnaire is now the standard tool for evaluating results after breast reconstruction.<sup>19</sup> However, we chose to use the simpler Harris scale in our study as it was more suitable for our study population. We provided a simplified translated version of the Harris scale whenever patients could not understand English.

Cup size A was associated with good cosmetic outcomes regardless of the BMI. As the breast cup size increased, good cosmetic outcomes were obtained with a smaller BMI.

The ELD is a suitable method of reconstruction for patients with breast cup size A. It can also be used with good cosmetic outcomes in patients with larger breast cup sizes. However, the cosmetic outcomes are inversely proportional to the patient's BMI. The higher the BMI, the less favorable the cosmetic outcomes are expected to be.

No favorable cosmetic outcomes were observed in patients with BMI higher than 33 regardless of the breast cup size.

This simple method of preoperative prediction can help improving the selection of patients who would be expected to achieve favorable cosmetic outcomes with totally autologous method after immediate breast reconstruction.

To the best of our knowledge, this is one of the first studies looking at such a prediction method.

Few other studies have tried to preoperatively estimate the adequacy of the autologous latissimus dorsi flap for immediate breast reconstruction.

Fujiwara et al proposed a specific formula that can be used by surgeons to predict preoperatively if the latissimus flap will be adequate alone for breast reconstruction.<sup>20</sup>  $FW (g) = 13.50 * BMI (kg/m^2) + 1.67 * SPA (cm^2) - 163.26$ . FW: Flap weight, BMI: Body mass index, SPA: Skin paddle area.

They suggested that if the flap volume is estimated to be inadequate, a larger skin paddle is needed if possible, otherwise another reconstructive option should be used. However, their study was conducted only on women with small-sized breasts, and the mean BMI was 21.

Lee et al compared the intraoperative weight of the LD flap to the mastectomy weight.<sup>21</sup> Their results showed that a ratio of 70% or higher was a significant indicator of favorable aesthetic results.

Tomita et al evaluated the factors affecting cosmetic outcomes after LD reconstruction following skin-sparing mastectomy.<sup>22</sup> BMI and breast cup size were analyzed among other factors. However, each factor was analyzed separately. Factors associated with favorable outcomes included small breast cup size, mainly size A. BMI did not have an effect on the aesthetic outcomes. However, this may have been due to the fact that 47 out of 53 patients had a BMI below 25.

We recognize the limitations in our study, mainly the small number of patients and the fact that it is a retrospective cohort study. This can affect the statistical significance of the results.

The breast cup size information was obtained from the patients. This is a significant limitation to our study as patients are known not to be accurate about their bra cup size.<sup>23</sup> In our planned prospective study, we will be measuring the patient's cup size independently in the clinic prior to surgery.

Similarly, the photographs we obtained in the study were not standardized. This limits the interpretation of our results. We plan to obtain standard photos in our prospective study.

Another limitation is the short duration of follow-up for analyzing the results. Because most of our patients received postoperative radiation, we did not analyze the initial results after radiotherapy to avoid its confounding effect on the aesthetic results in those patients.

We continue to follow our patients for oncologic and cosmetic outcomes as time progresses. The latissimus dorsi flap atrophies with time, and radiotherapy and other factors can change the

cosmetic outcome in the future. The effects of radiation therapy on the cosmetic outcome of immediate breast reconstruction will be the subject of a further prospective study.

In our study, we did not include the mastectomy weight among the predicting factors. Despite its importance, it is not a preoperative parameter. Our main focus was to create a simple preoperative prediction model for the final cosmetic outcomes.

A prospective trial is needed to validate this prediction model. Once validated, it could be of assistance to patients and surgeons by providing an objective way for planning the most suitable method for breast reconstruction in each individual patient.

## Conclusion

The ELD is a reliable method for immediate breast reconstruction following skin- and nipple-sparing mastectomy.

This study aimed to establish a preoperative prediction model for cosmetic outcomes depending on the patients' BMI and breast cup size.

Favorable cosmetic outcomes are expected to be obtained in patients with breast cup size A regardless of the BMI. As the breast cup size increases, favorable cosmetic outcomes are expected in patients with lower BMI than in those with higher BMI. At a BMI of 34, no favorable cosmetic outcomes can be expected.

Prospectively conducted trials are needed to validate this prediction model.

## Conflict of interest statement

Authors declare there is no conflict of interest in this article.

## Funding source

The funding of this work was done through a grant from the Science and Technology Development Fund (STDF) of the Egyptian Ministry of Scientific Research. The funding source had no involvement in the study design, the collection, analysis and interpretation of data; in the writing of the manuscript; and in the decision to submit the manuscript for publication.

## Ethical approval

Ethical approval was not required for this study.

## Acknowledgment

The authors would like to thank Professor Roy Devita, Director of the Plastic Unit at the National Cancer Institute in Rome, Italy, for giving the opportunity to the first author to learn and master the technical aspects of this study and transfer the experience to the Egyptian NCI where the study took place. This opportunity was funded by grant number 6129 from the Science and Technology Development fund (STDF) of the Egyptian Ministry of Scientific Research.

## References

1. Al Ghazal SK, Sully L, Fallowfield L, Blamey RW. The psychological impact of immediate rather than delayed breast reconstruction. *EJSO*. 2000;26:17–19.
2. Agrawal A, Grewal M, Sibbering DM, Courtney C-A. Surgical and oncological outcome after skin-sparing mastectomy and immediate breast reconstruction. *Clin Breast Cancer*. 2013;13:478–481.
3. Didier F, Arnaboldi P, Gandini S, et al. Why do women accept to undergo a nipple sparing mastectomy or to reconstruct the nipple areola complex when nipple sparing mastectomy is not possible? *Breast Cancer Res Treat*. 2012;132:1177–1184.
4. Kroll SS, Baldwin B. A comparison of outcomes using three different methods of breast reconstruction. *Plast Reconstr Surg*. 1992;90:455–462.
5. Saulis AS, Mustoe TA, Fine NA. A retrospective analysis of patient satisfaction with immediate postmastectomy breast reconstruction: comparison of three common procedures. *Plast Reconstr Surg*. 2007;119:1669–1676.

6. Hammond DC. Postmastectomy reconstruction of the breast using the latissimus dorsi musculocutaneous flap. *Cancer J*. 2008;14:248–252.
7. Hankins CL, Friedman J. A 7-year experience in utilizing the latissimus dorsi myocutaneous flap for bilateral breast reconstruction. *Ann Plast Surg*. 2008;60:134–140.
8. Spear SL, Boehmler JH, Taylor NS, Prada C. The role of the latissimus dorsi flap in reconstruction of the irradiated breast. *Plast Reconstr Surg*. 2007;119:1–9.
9. Chang DW, Barnea Y, Robb GL. Effects of an autologous flap combined with an implant for breast reconstruction: an evaluation of 1000 consecutive reconstructions of previously irradiated breasts. *Plast Reconstr Surg*. 2008;122:356–362.
10. Pinsolle V, Grinfeder C, Mathoulin-Pelissier S, Faucher A. Complications analysis of 266 immediate breast reconstructions. *J Plast Reconstr Aesthet Surg*. 2006;59:1017–1024.
11. Hokin JA. Mastectomy reconstruction without a prosthetic implant. *Plast Reconstr Surg*. 1983;72:810–818.
12. Delay E, Gounot N, Bouillot A, Zlatoff P, Rivoire M. Autologous latissimus breast reconstruction: a 3-year clinical experience with 100 patients. *Plast Reconstr Surg*. 1998;102:1461–1478.
13. Papp C, McCraw JB. Autogenous latissimus breast reconstruction. *Clin Plast Surg*. 1998;25:261–266.
14. Heitmann C, Pelzer M, Kuentscher M, Menke H, Germann G. The extended latissimus dorsi flap revisited. *Plast Reconstr Surg*. 2003;111:1697–1701.
15. Chang DW, Youssef A, Cha S, Reece GP. Autologous breast reconstruction with the extended latissimus dorsi flap. *Plast Reconstr Surg*. 2002;110:751–759.
16. Harris JR, Levene MB, Svensson G, Hellman S. Analysis of cosmetic results following primary radiation therapy for stages I and II carcinoma of the breast. *Int J Radiat Oncol Biol Phys*. 1979;5:257–261.
17. WHO Global Infobase Team: The SuRF report 2. Surveillance of chronic disease risk factors: country-level data and comparable estimates Geneva: World Health Organization; 2005.
18. Tarantino I, Banic A, Fischer T. Evaluation of late results in breast reconstruction by latissimus dorsi flap and prosthesis implantation. *Plast Reconstr Surg*. 2006;117:1387–1394.
19. Pusic AL, Klassen AF, Scott AM, Klok JA, Cordeiro PG, Cano SJ. Development of a new patient-reported outcome measure for breast surgery: the BREAST-Q. *Plast Reconstr Surg*. 2009;124:345–353.
20. Fujiwara T, Yano K, Tanji Y, Kanazawa S, Hosokawa K. Preoperative estimation of pedicled latissimus dorsi flap weight for breast reconstruction. *J Plast Reconstr Aesthet Surg*. 2014;67:579–581.
21. Lee J-W, Chang T-W. Extended latissimus dorsi musculocutaneous flap for breast reconstruction: experience in oriental patients. *Br J Plast Surg*. 1999;52:365–372.
22. Tomita K, Yano K, Matsuda K, Takada A, Hosokawa K. Esthetic outcome of immediate reconstruction with Latissimus Dorsi myocutaneous flap after breast-conservative surgery and skin-sparing mastectomy. *Ann Plast Surg*. 2008;61:19–23.
23. Bengtson BP, Clicksman CA. The standardization of bra cup measurements: redefining bra sizing language. *Clin Plast Surg*. 2015;42:405–411.