



# A COMPARISON OF HIGH VISCOSITY AND LOW VISCOSITY BONE CEMENT VERTEBROPLASTY FOR SEVERE OSTEOPOROTIC VERTEBRAL COMPRESSION FRACTURES

- Sinan KARACA<sup>1</sup>
- Ahmet OZTERMELI<sup>1</sup>
- Ahmet Onur AKPOLAT<sup>1</sup>
- Mehmet Nuri ERDEM<sup>2</sup>
- Mehmet AYDOGAN<sup>3</sup>

<sup>1</sup>Department of Orthopaedics and Traumatology, Fatih Sultan Mehmet Training and Research Hospital, İstanbul, Turkey

<sup>2</sup>İşık University, Vocational School of Health Services, Operating Room Services Department, İstanbul, Turkey.

<sup>3</sup>Department of Orthopaedics and Traumatology Bosphorus Spine Center, İstanbul, Turkey

#### ORCID Numbers:

**Sinan KARACA:**

0000-0002-2493-8728

**Ahmet OZTERMELI:**

0000-0002-0296-2559

**Ahmet Onur AKPOLAT:**

0000-0001-7773-5476

**Mehmet Nuri ERDEM:**

0000-0001-7377-6393:

**Mehmet AYDOGAN:**

0000-0003-4963-8382

**Address:** Dr. Sinan KARACA, Fatih Sultan Mehmet Training and Research Hospital, Orthopaedics and Traumatology Clinic, 34856 Ataşehir, İstanbul, Turkey.

**Tel:** +90 532 151 07 90

**Email:** mdsnn@hotmail.com

**Received:** 17<sup>th</sup> August, 2018.

**Accepted:** 24<sup>th</sup> September, 2018.

#### ABSTRACT

**Introduction:** Our aim in this clinical trial was to compare the safety and efficacy of high-viscosity cement (HVC) with low-viscosity cement (LVC) for the treatment of osteoporotic vertebrae fractures in terms of pain, functional capacity and cement leakage in the percutaneous vertebroplasty procedure (PVP).

**Methods:** From March 2013 to February 2015, 76 patients with vertebrae compression fracture who were admitted into hospital and treated with PVP were reviewed. Pre- and postoperative clinical characteristics of each patient were obtained by using The Visual Analog Scale (VAS) score to evaluate back pain, Oswestry Disability Index (ODI) as a functional assessment. Cement leakage, injected cement volume and the complications assessed due to medical records.

**Results:** VAS and ODI scores improved ( $P < 0.05$ ) significantly in the two groups postoperatively on the other hand there was no significant change between two groups ( $P > 0.05$ ). Paravertebral cement leakage was significantly higher in the LVC group ( $P < 0.05$ ). Pulmonary cement embolism was also significantly higher in LVC group ( $P < 0.05$ ).

**Conclusion:** HVC had lower complication rates with similar clinical results in the comparison with LVC.

**Keywords:** Vertebroplasty, cement leakage, bone cement, viscosity, pulmonary embolism, vertebral fracture, osteoporosis

**Level of evidence:** Retrospective clinical study, Level III

#### INTRODUCTION

The most common systemic disorder worldwide is osteoporosis and it is characterized by decreased bone mass quality, transformed bone micro architecture and increased fracture risk<sup>(3,13)</sup>. An estimated 22 million women and 5.5 million men are afflicted with osteoporosis at the European Union. When the treatment cost of fractures related to osteoporosis is added to the cost, it has been reached to 37.0 billion euro and is assumed to increase by 25 % in 2025<sup>(9)</sup>.

With the aging of the population, osteoporotic vertebral compression fractures (OVCFs) incidence has been increased and it is becoming a serious socio-economic problem. Despite generally believed hypothesis is good prognosis for most of these fractures; OVCF worsens the long term patient's health<sup>(18)</sup>.

During the last decade, with the increased popularity at the minimally invasive surgery and development of new approaches and methods, percutaneous vertebroplasty (PVP) which includes percutaneously cement injection into the fractured vertebral body is an accepted technique for the treatment of the patients with painful OVCFs<sup>(6,11)</sup>. For this purpose, multiple types of injectable bone cements like PolyMethylMetAcrylate (PMMA), calcium phosphate and composite cements are currently being used in PVP. PMMA is the most widely used cement type due to its good handling properties, strength, long time experience, and low costs.

Severe complications like spinal cord compression, nerve damage, blood vessels thermal damage and pulmonary embolism could be caused by leakage of the cement into vessels or intramedullary channel of

the spine. On the other hand, little amount of cement leakage could be without clinical manifestation<sup>(15)</sup>. The detection of cement leakage on plain roentgenograms is ranging from 43 % to 45 % on the other hand on the computed tomography (CT) scan rates are changing between 78 % and 91.9 %. Due to these rates, leakage of the cement is a severe problem that spine surgeons have attempted to find a solution<sup>(5,19)</sup>.

The risk for extravasation could be effectively decreased by using high viscosity cement (HVC) and thereby clinical safety could be improved. In an experimental study Baroud et al. demonstrated that cement leakage could be stopped completely with HVC<sup>(4)</sup>. Also in a prospective comparative clinical study Georgy and Anselmetti confirmed that HVC is safe in application and may decrease cement leakage at PVP procedure compared with low viscosity cements(LVC)<sup>(7,14)</sup>.

HVC directly reaches an optimum injectable viscosity after mixing, without a waiting period of few minutes as in LVC's, and before the cement solidification it conserves the injectable form for 8–10 minutes.

Also in a retrospective study it has been shown that using HVC may have a role in decreasing the risk of cement leakage in PVP procedure and may result in leakage rates comparable with that of balloon kyphoplasty<sup>(2)</sup>.

Our aim in this clinical trial was to compare the safety and efficacy of high-viscosity cement vertebroplasty (HVCV) with low-viscosity cement vertebroplasty (LVCV) for the treatment of OVCFs in terms of pain, functional capacity and cement leakage.

## MATERIALS AND METHODS

### General data

From March 2013 to February 2015, 76 patients with vertebrae compression fracture who were admitted into hospital and treated with PVP were reviewed. 12 patient excluded from the study due to the exclusion criteria's and 1 patient from the group HVC died because of a cancer 1 patient from the group LVC died in a traffic accident during the follow-up. In 62 patients there were 22 in male and 40 in female.

Patients were included in the study if they<sup>(1)</sup> were aged above 50 years, <sup>(2)</sup> had severe OVCFs vertebrae or lumbar fracture without symptom and signs of spinal cord damage or pedicle damage (part of the vertebral body collapsed to less than one-third of their original height), <sup>(3)</sup> had focal back pain without definite radicular signs and symptoms unresponsive to at least 8 weeks of appropriate conservative treatment, <sup>(4)</sup> had back pain related to the location of the OVCF on spinal radiographs, <sup>(5)</sup> Vertebrae compression fracture confirmed by

international recognized imaging (X plain film, CT, MRI T2-weighted short tau inversion recovery sequences) and clinical examination, and <sup>(6)</sup> Osteoporosis diagnosed by bone mineral density (BMD), BMD was less than 2.5 SD suggested the possibility of osteoporosis.

Patients were excluded if they<sup>(1)</sup> had ordinary OVCFs (vertebral body collapsed to more than one-third of their original height), <sup>(2)</sup> had spinal cord compression or stenosis of the vertebral canal > 30 % of the local canal diameter, <sup>(3)</sup> Injury of neural function including spinal cord damage or cauda equina injury, <sup>(4)</sup> Unable to undergo related examinations, <sup>(5)</sup> had systemic or local spine infections, and <sup>(6)</sup> had severe comorbidity in the heart, liver, kidney, and lung intolerance to surgery. <sup>(7)</sup> Blood coagulation dysfunction with bleeding <sup>(8)</sup> Poor compliant patients or loss to follow up during follow-ups.

The study population consisted of 29 patients in the group HVC (mean age, 75.4 ± 9.3 years) and 33 patients in the group LVC (mean age, 75.8 ± 9.1 years). All procedures were performed by the same surgeon (MA).

All patients had low back pain and pain when turning over and were unable to stand up. Besides, pain released when patient was in supine position and worsened when bending over. Physical examination showed that there were obvious tenderness and percussion pain at thoracic vertebrae or lumbar fracture site.

Magnetic resonance imaging (MRI), thin slice computerized tomography (CT), dual-energy X-ray absorptiometry (DEXA), and anteroposterior (A/P) and lateral radiographs were evaluated before CT and AP-LAT radiographs after the surgery to determine the appropriateness of the procedure and plan the treated levels.

Cement leakage, defined as the presence of any extravertebral cement, was assessed independent of the treating physician by 2 investigators using a computed tomography (CT) scan made after PVP. Differences were re-examined until consensus was obtained.

All procedures were carried out with sterile equipment. Patients were placed in a prone position on operating table, and sedation was achieved with 1.5 cc intravenous midazolam. The entry point was confirmed by C-arm X-ray machine and marked local anesthesia with 2% prilocaine hydrochloride (8 cc) was administered from the pedicle of fractured vertebra to subcutaneous tissue. An 11-gauge needle was inserted into the pedicle via fluoroscopy. Using anteroposterior and lateral imaging, the pedicle was passed through the body to reach the corpus vertebrae. A biopsy has been taken for identifying if the fracture is due to the osteoporosis or not. Then, cementing

was performed, and a lateral X-ray showed the distribution of the cement inside the corpus. The amount of cement added was determined via lateral imaging. After the procedure, the patients remained motionless in a prone position until the cement polymerized. The patients underwent a neurological examination at every stage of the procedure. All of the patients stayed in the hospital for 1 day, and none of them had to wear a cast after discharge.

Pre- and postoperative clinical characteristics of each patient were obtained by using The Visual Analog Scale (VAS) score to evaluate back pain, Oswestry Disability Index (ODI) as a functional assessment. Routine standing anteroposterior and lateral radiographs of the spine were made 6 weeks and 1 year after PVP and on indication, e.g., sudden new onset of back pain suspect for a new OVCF.

### Statistical analysis

IBM SPSS statistic 22.0 was applied in statistical analysis. All data were showed by mean  $\pm$  SD. Intergroup comparisons were made using the Student's paired t-test or Man Whitney U test. Comparisons between before and after operation were made using the paired simple t-test and Wilcoxon signed Ranks. P-values < 0.05 were considered statistically significant.

## RESULTS

### Demographic data

There were no significant differences between group HVC and group LVC in the gender ratios, age, and vertebral bodies involved according to the statistical results (Table-1).

The time of follow-ups in group HVC and group LVC were 1.0 - 2.1year (mean 1.6  $\pm$  0.5) and 1.1 - 2.0 year (1.5  $\pm$  0.6) respectively. Sixty-two surgeries were carried on 137 vertebrae.

### Surgery time

The average surgery time was 20,97 $\pm$ 3,24minutes on average for LVC, and 10,07 $\pm$ 1,21minutes for HVC, There was statistical difference between the two groups according to the mean surgery time/vertebrae (P:0.001; P<0.05).

### Amount of cement

All surgeries were completed successfully. The injected volume of HVC and LVC were 3,52  $\pm$  1,09 ml and 3,39  $\pm$  1,2 ml respectively. There was no statistical difference about injected volume of bone cement (p:0,551).

### VAS ODI

The two groups reported immediate postoperative pain relief, and none had subjective complaints of worsening pain at any time point of follow-up. Group HVC the mean VAS score before PV of 8.41  $\pm$  1.16 improved significantly, to a mean of 1.31  $\pm$  0.69 at the end point after the procedure (*Mann Whitney U test, Wilcoxon Sign test, p<0.05*). In Group LVC the mean VAS of 8.36  $\pm$  0.99 pre-procedure dropped to 1.36  $\pm$  0.83 post-procedure respectively (*P<0.05*) 12 months follow-up (Table-2).

**Table-1.** Table showing demographic data of patients included in this study

|                        | GROUP HVC                         | GROUP LVC                    | P-value       |
|------------------------|-----------------------------------|------------------------------|---------------|
| Number of Participants | 29                                | 33                           |               |
| MEN/WOMEN              | 10/19                             | 12/21                        | 1.00          |
| Vertebral Bodies (n)   | 61                                | 66                           |               |
| Mean Age               | 72,46 $\pm$ 8,03                  | 74,84 $\pm$ 5,84             | <b>0,191</b>  |
| Mean Follow up (years) | 1.0-2.1 year (mean 1.6 $\pm$ 0.5) | 1.1-2.0 year (1.5 $\pm$ 0.6) | 0.86          |
| Surgery Time           | 10,07 $\pm$ 1,21                  | 20,97 $\pm$ 3,24             | <b>0,001*</b> |
| Cement Volume          | 3,52 $\pm$ 1,09 (3)               | 3,39 $\pm$ 1,2 (3)           | <b>0,551</b>  |

**Table-2.** Comparison of VAS between two groups

| VAS                                       | GROUP LVC       | GROUP HVC       | p <sup>1</sup> |
|---|-----------------|-----------------|----------------|
|   | Mean $\pm$ SD   | Mean $\pm$ SD   |                |
| PREOPERATIVE                              | 8,36 $\pm$ 0,99 | 8,41 $\pm$ 1,16 | 0,878          |
| POSTOPERATIVE                             | 1,36 $\pm$ 0,83 | 1,31 $\pm$ 0,69 | 0,821          |
| Preoperative-Postoperative p <sup>2</sup> | 0,001*          | 0,001*          |                |

<sup>1</sup>Mann Whitney U test

<sup>2</sup>Wilcoxon Sign test

\*p<0.05

ODI scores also improved (*P<0.05*) significantly in the two groups, from a mean index of 43.88%  $\pm$  3.97 to 6.94%  $\pm$  2.63% (Group HVC) and from 42.82%  $\pm$  6.2% to 6.71%  $\pm$  2% (Group LVC). No differences in clinical outcome were noted between the two groups (p > 0.05) (Table-3).

**Table-3.** Comparison of ODI between two groups

| ODI                                       | GROUP LVC       | GROUP HVC        | p <sup>1</sup> |
|---|-----------------|------------------|----------------|
|   | Mean $\pm$ SD   | Mean $\pm$ SD    |                |
| PREOPERATIVE                              | 42,82 $\pm$ 6,2 | 43,88 $\pm$ 3,97 | 0,444          |
| POSTOPERATIVE                             | 6,71 $\pm$ 2    | 6,94 $\pm$ 2,63  | 0,715          |
| Preoperative-Postoperative p <sup>2</sup> | 0,001*          | 0,001*           |                |

<sup>1</sup>Student t test

<sup>2</sup>Paired Samples test

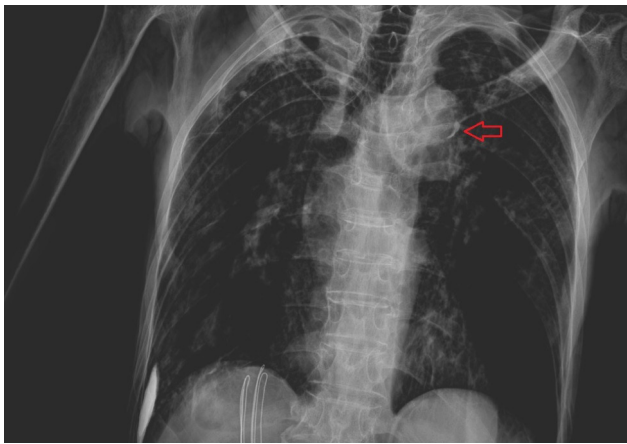
\*p<0.05

## Complication

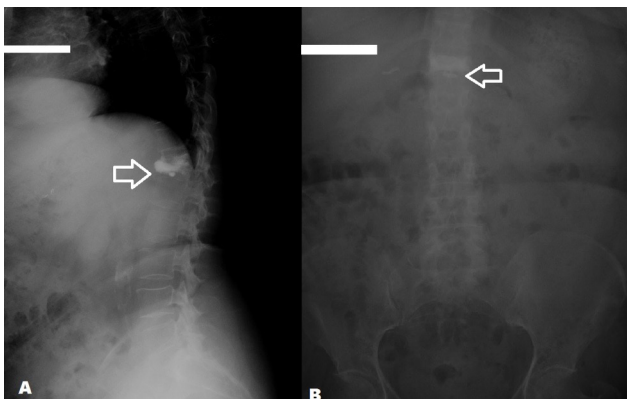
No significant clinical complications or post-procedural clinical sequelae were encountered in both groups.

Comparison of data showed a statistically highly significant difference ( $p: 0.023$ ;  $p < 0.05$ , Continuity Yates correction) of disc cement leakages between patients treated with group HVC and patients in Group LVC (Figure-1).

In group HVC pulmonary embolism ratio was statistically higher than group LVC ( $P: 0.037$ ;  $P < 0.05$ ) (Table-4) (Figure-2).



**Figure-1.** Arrow showing the pulmonary cement embolism in group LVC.



**Figure-2. (A)** Lateral plane x ray showing cement leakage to the disc and anterior wall of the vertebrae. **(B)** Anterior-Posterior x ray arrow showing the cement leakage to the disc.

One elder patient with severe osteoporotic vertebrae body compression fracture (L-1) in group HVC had distal vertebrae fracture (L-2) postoperatively. Also one case of postoperative

adjacent vertebrae fracture was found in group LVC. All new fractures were treated surgically. No statistical difference in new fracture rate was demonstrated between the groups. There was one case with a superficial wound infection that was treated with antibiotics in group LVC.

**Table-4.** Comparison cement leakages and pulmonary embolism between two groups

|                            | GROUP LVC  | GROUP HVC  | p             |
|----------------------------|------------|------------|---------------|
|                            | n (%)      | n (%)      |               |
| <b>Disc cement leakage</b> |            |            |               |
| -                          | 17 (%60,7) | 9 (%28,1)  | <b>0,023*</b> |
| +                          | 11 (%39,3) | 23 (%71,9) |               |
| <b>Pulmonary embolism</b>  |            |            |               |
| -                          | 19 (%67,9) | 12 (%37,5) | <b>0,037*</b> |
| +                          | 9 (%32,1)  | 20 (%62,5) |               |

Continuity (Yates) correction \* $p < 0.05$

## DISCUSSION

Osteoporosis had become a kind of common disease with severe damage to elderly health<sup>(12)</sup>. A female had a risk of osteoporotic fracture at 30 % ~ 40 % worldwide. The rate of osteoporosis was approximately 60 % for the aged over 60 years old, 80 % of who were female.

Traditionally, osteoporosis-related compression fractures of the spine have been treated conservatively, with analgesics and long-term bed rest. However, it is now well accepted that PVP is the treatment of choice for patients with osteoporotic compression fractures. It results in lower morbidity and mortality than open surgery and avoids prolonged immobility. A review of the recent literature on spinal metastases treated with percutaneous transpedicular vertebroplasty revealed that complete or partial pain relief (1–3 days postoperatively) was achieved in 75–89% of patients<sup>(1,10,16-17)</sup>. The results of our study were at least as successful in treating patients with pathological vertebral body collapse using PVP.

PVP was the one of clinical common operation treatment with severe complication of bone cement leakage. Some studies showed that LVC had a higher rate of cement leakage and para-vertebrae leakage than HVC<sup>(4,8)</sup>. LVC was easy to leak and diffuse to vein to induce pulmonary embolism with disadvantage of short solidification time and inconvenient operation. Also in our study we found statistically higher cement leakage rates in LVC.

Three major factors may influence the cement flow into and out of the vertebral body: bone- and fracture-related parameters, injection methods, and properties of cement.



Although fracture morphology is impossible to control and the method of injection has been standardized, the properties of cement may be manipulated to ultimately decrease the rate of leakage of cement. In terms of properties of cement, an increased viscosity leads to a uniformly expanding cloud and a decreased spreading distance ideally, ignoring preformed paths by vessels or structural irregularities, thus reducing the risk of leakage<sup>(4,7,14)</sup>.

In group HVC there was a shorter surgery time using HVC in our study can be attributed to earlier beginning of application of the cement immediately after mixing the components of cement in group HVC, on the other hand surgeon have to wait polymerization of LVC to end to prevent leakage of cement in the surrounding musculature at removal of a needle.

It is unclear whether spatial distribution of the cement influenced by its viscosity affects the outcome of PVP. The results of the present study showed a clinically relevant, significant, immediate, and durable reduction in mean back pain and function, which was comparable between both the groups. Thus there is no direct dependence between the quantity of cement applied and clinical outcome.

In fact our study had limitations. First, it was a retrospective study and the patients were not classified according to the fracture type. Secondly the small size of the study group was a limitation of our study. Also, the research assistants involved in the data collection of this study were not blinded to treatment type and may have introduced bias. Finally, length of follow-up in this study is a limitation.

This study showed that HVC had a lower rate of postoperative cement leakage because HVC was improved on basis of LVC, which could improve the liquid phase in the process of bone cement mixing and decrease the leakage rate and other complication rate to enhance the safety of PVP. A controlled prospective, high-powered, randomized multicenter studies also including the medium viscosity cement need to be designed to determine the differences in patient outcomes and to further elucidate optimal treatment strategies for VCF's.

**Conflicts of interest:** There are no conflicts of interest in connection with this paper, and the material described is not under publication or consideration for publication elsewhere.

**Funding Statement:** There is no financial relationship with this paper.

## REFERENCES

1. Alvarez L, Perez-Higueras A, Quinones D, Calvo E, Rossi RE. Vertebroplasty in the treatment of vertebral tumors: postprocedural outcome and quality of life. *Eur Spine J* 2003; 12: 356–360.

2. Anselmetti GC, Zoarski G, Manca A, Masala S, Eminefendic H, Russo F, Regge D. Percutaneous vertebroplasty and bone cement leakage: Clinical experience with a new high-viscosity bone cement and delivery system for vertebral augmentation in benign and malignant compression fractures. *Cardiovasc Intervent Radiol* 2008; 31: 937–947.
3. Appelman-Dijkstra NM, Papapoulos SE. Novel approaches to the treatment of osteoporosis. *Best Pract Res Clin Endocrinol Metab* 2014; 28: 843–857.
4. Baroud G, Crookshank M, Bohner M. High-viscosity cement significantly enhances uniformity of cement filling in vertebroplasty: an experimental model and study on cement leakage. *Spine* 2006; 31: 2562–2568.
5. Chen C, Bian J, Zhang W. Unilateral versus bilateral vertebroplasty for severe osteoporotic vertebral compression fractures. *J Spinal Disord Tech* 2014, [http:// dx.doi.org /10.1097/ BSD.0000000000000118](http://dx.doi.org/10.1097/BSD.0000000000000118).
6. Evans AJ, Jensen ME, Kip KE, DeNardo AJ, Lawler GJ, Negin GA, Remley KB, Boutin SM, Dunnagan SA. Vertebral compression fractures: Pain reduction and improvement in functional mobility after percutaneous polymethylmethacrylate vertebroplasty retrospective report of 245 cases. *Radiology* 2003; 226: 366–372.
7. Georgy BA. Clinical experience with high-viscosity cements for percutaneous vertebral body augmentation: occurrence, degree, and location of cement leak-age compared with kyphoplasty. *AJNR Am J Neuroradiol* 2010; 31: 504–508.
8. Habib M, Serhan H, Marchek C and Baroud G. Cement leakage and filling pattern study of low viscous vertebroplastic versus high viscous confidence cement. *SASJ* 2010; 4: 26–33.
9. Hernlund E, Svedbom A, Ivergard M, Compston J, Cooper C, Stenmark J, McCloskey EV, Jönsson B, Kanis JA; EU Review Panel of IOF. Osteoporosis in the European Union: medical management, epidemiology and economic burden. A report prepared in collaboration with the International Osteoporosis Foundation (IOF) and the European Federation of Pharmaceutical Industry Associations (EFPIA). *Arch Osteoporos* 2013; 8: 136.
10. Jang JS, Lee SH. Efficacy of percutaneous vertebroplasty combined with radiotherapy in osteolytic metastatic spinal tumors. *J Neurosurg Spine* 2005; 2: 243–248.
11. Klazen CA, Lohle PN, de Vries J, et al. Vertebroplasty versus conservative treatment in acute osteoporotic vertebral compression fractures (Vertos II): An open-label randomised trial. *Lancet* 2010; 376: 1085–1092.
12. Legroux-Gerot I, Lormeau C, Boutry N, Cotten A, Duquesnoy B, Cortet B. Long-term follow-up of vertebral osteoporotic fractures treated by percutaneous vertebroplasty. *Clin Rheumatol* 2004; 23: 310–317.
13. Litwic A, Cooper C, Dennison E. Osteoporosis therapies in 2014. *Panminerva Med* 2014; 56: 273–283.
14. Nieuwenhuijse MJ, Muijs SP, van Erkel AR, Dijkstra SP. A clinical comparative study on low versus medium viscosity polymethylmethacrylate bone cement in percutaneous vertebroplasty: viscosity associated with cement leakage. *Spine* 2010; 35: E1037–1044.

- 
15. Pan J, Yang HL, Meng B. The research progress of bone cement in percutaneous vertebroplasty and percutaneous kyphoplasty. *Chinese J Spine Spinal Cord* 2012; 22: 81-84.
  16. Rand T, Lomoschitz F, Cejna M. Percutaneous radiologically-guided vertebroplasty in the treatment of osteoporotic and tumorous spinal body lesions. *Radiology* 2003; 43: 723-728.
  17. Sun G, Cong Y, Xie Z, et al. Percutaneous vertebroplasty using instruments and drugs made in China for vertebral metastases. *Chin Med J* 2003; 116: 1207-1212.
  18. Suzuki N, Ogikubo O, Hansson T. The course of the acute vertebral body fragility fracture: its effect on pain, disability and quality of life during 12 months. *Eur Spine J* 2008; 17: 1380-1390.
  19. Young C, Munk PL, Heran MK, Lane MD, Le HB, Lee S, Badii M, Clarkson PW, Ouellette HA. Treatment of severe vertebral body compression fractures with percutaneous vertebroplasty. *Skeletal Radiol* 2011; 40: 1531-1536.