

## Proceeding

Supplementary Issue: Spring Conferences of Sports Science. Costa Blanca Sports Science Events, 19-20 June 2020. Alicante, Spain.

# Effectiveness of endoscopic trans-tendineous repair for partial-thickness tears of medius gluteus: A systematic review of literature

ALESSIO D'ADDONA<sup>1</sup> ✉, FEDERICO DELLA ROCCA<sup>2</sup>, DOMENICO CARRELLA<sup>1</sup>, BRUNO CORRADO<sup>1</sup>, FELICE SIRICO<sup>1</sup>, PAOLINO IORIO<sup>1</sup>, GIOVANNI BALATO<sup>1</sup>

<sup>1</sup>Department of Public Health, Section of Orthopaedics and Trauma Surgery, A.O.U. "Federico II", School of Medicine and Surgery, Naples, Italy

<sup>2</sup>U.O.C. Hip Surgery and Prosthetic Surgery, I.R.C.C.S. Humanitas Research Hospital, Rozzano, Italy

### ABSTRACT

Tears of the gluteus medius can result in chronic hip pain over time. Pathological onsets involving the gluteus medius cause pain and weakness of abductor strength. Endoscopic repair is a suitable, effective and safe surgical alternative to traditional open techniques and give satisfactory results over time restoring the footprint of gluteus medius. The purpose of this systematic review is to analyse the effectiveness of endoscopic trans-tendinous technique for partial-thickness tears, analysing the subjective and functional outcome over the time. A search of literature (PubMed, Scopus, WebOfKnowledge) was performed. The PRISMA method was used to screen the articles. A total of 4 articles was screened and included for qualitative analysis. For data extraction patient characteristics, pre-clinical examination, imaging, timing from symptoms to surgery, technique performed, subjective scales, functional outcomes, post-operative clinical assessment were analysed. Subjective scores at mean follow-up of 18 months show a significative improvement in all the scales reported, in relief of pain (VAS score) and in terms of strength of abductor. Trans-tendinous technique represents the gold standard to treat endoscopically these injuries. Furthermore, other studies with larger number of patients and longer follow-up are required to validate the best surgical approach for these injuries. **Keywords:** Endoscopy; Hip; Partial tear; Medius gluteus; Abductor muscle; Lateral hip pain; Trans-tendinous technique.

#### Cite this article as:

D'Addona, A., Della Rocca, F., Carrella, D., Corrado, B., Sirico, F., Iorio, P., & Balato, G. (2020). Effectiveness of endoscopic trans-tendineous repair for partial-thickness tears of medius gluteus: A systematic review of literature. *Journal of Human Sport and Exercise*, 15(3proc), S770-S780. doi:<https://doi.org/10.14198/jhse.2020.15.Proc3.27>



**Corresponding author.** Department of Public Health, Section of Orthopaedics and Trauma Surgery, A.O.U. "Federico II", School of Medicine and Surgery, Via S.Pansini 5, 80131, Naples, Italy. <https://orcid.org/0000-0002-8862-8489>

E-mail: [alessio.daddona@gmail.com](mailto:alessio.daddona@gmail.com)

Supplementary Issue: Spring Conferences of Sports Science. [Costa Blanca Sports Science Events](#), 19-20 June 2020. Alicante, Spain.

JOURNAL OF HUMAN SPORT & EXERCISE ISSN 1988-5202

© Faculty of Education. University of Alicante

doi:10.14198/jhse.2020.15.Proc3.27

## INTRODUCTION

Recently, greater trochanteric pain syndrome have raised as cause of lateral hip pain. In particular, it is more common in females than in men among fifth and sixth decades of life with a ratio of up to 4:1 (Yanke et al., 2013; Alpaugh et al., 2015), with an estimated prevalence of 1.8/1000 (Chandrasekaran et al., 2015; Domb & Carreira, 2013; Thauat et al., 2013). Although trochanteric pain is generally associated to an inflammation of trochanteric bursa, many studies have assessed that the main cause of lateral hip pain is due to gluteus muscles tears, with a prevalence of medius gluteus is comparison with the minimus gluteus (Domb, Botser, & Giordano, 2013; Domb & Carreira, 2013). Gluteus tears are more often characterized by chronic pain onset generated by attritional forces than acute traumatic pain (Chandrasekaran, Gui, et al., 2015; Domb & Carreira, 2013). Generally, patients suffer of pain on weight-bearing and during climbing or descending stairs, limping with a typical Trendelenburg gait (Chandrasekaran et al., 2015; Hartigan et al., 2018; Thauat et al., 2016). Recognize and treat a partial-thickness under surface tears represent a challenge for orthopaedic surgeons because they cannot be visualized directly from the peritrochanteric space (Hartigan et al., 2018). For this purpose, patients history, symptoms and imaging are fundamental. In particular, magnetic resonance imaging (MRI) scan reveals a pattern of tendinosis in chronic onset with partial-thickness tear, or a full-thickness tear with a complete loss of continuity of medius gluteus. However, partial-thickness under surface tears (PUSTA) may be more common than complete ruptures and typically occur at the dual insertion of the anterior and middle muscle fibres of the gluteus medius into the superoposterior and lateral facets of the greater trochanter (Domb et al., 2013), (Yanke et al., 2013). The correct treatment options are still under debate. Generally, for attritional chronic gluteus medius tears, conservative treatment is considered the first line option: physical therapy, functional therapies, peritrochanteric corticosteroids and local anaesthetic injections, and not steroidal anti-inflammatory drugs (NSAIDs) are generally used. Surgical option is recommended for patients who continued to feel pain after more than at least six months of nonoperative management (Chandrasekaran et al., 2015). The goal of surgical approach is to restore the footprint and promote tendon-to-bone healing (Chandrasekaran et al., 2015). Lequesne suggested that surgery is indicated in case of four associated conditions: symptoms duration > 6 months, onset of tendinopathy at MRI scan, positive US-guided local anaesthetic infiltration test, and absence of retraction or fatty degeneration of the gluteus medius (Thauat et al., 2013). For this purpose, traditional open repairs guarantee good results and resolution of symptoms. Given recent advances in hip arthroscopy techniques and the relative instrumentation, over the past decade, surgeons developed to gain access to the peritrochanteric space and address pathology (McCormick et al., 2013). For partial-thickness tears, a transtendinous technique is raised as surgical technique to repair this kind of injury. The technique consists in sparing the intact superficial fibres while enabling debridement of degenerative under surface abductor tissue and adequate exposure for tendon repair.

The aim of this systematic review is to analyse among literature the technique used and the related functional outcomes of endoscopic transtendinous repair of partial-thickness tears of medius gluteus.

## METHODS

The PRISMA (Preferred Reporting Items for Systematic Reviews and Meta-Analyses) guidelines were followed to perform this systematic review (Figure 1).

### **Search strategy**

Four electronic databases (PubMed, Scopus and WebOfScience) were used to search the scientific literature using various combination of the keywords "Endoscopic repair", "gluteus medius", "partial tear",

“transtendineous”, and “Abductor hip tear” for the years 1950-2020. The final search was performed on May 1st, 2020 by two independent investigators. All the resulting titles were organised, screened independently and then matched between the two reviewers. In case of disagreement, a third senior investigator was asked to check and screened the resulting titles.

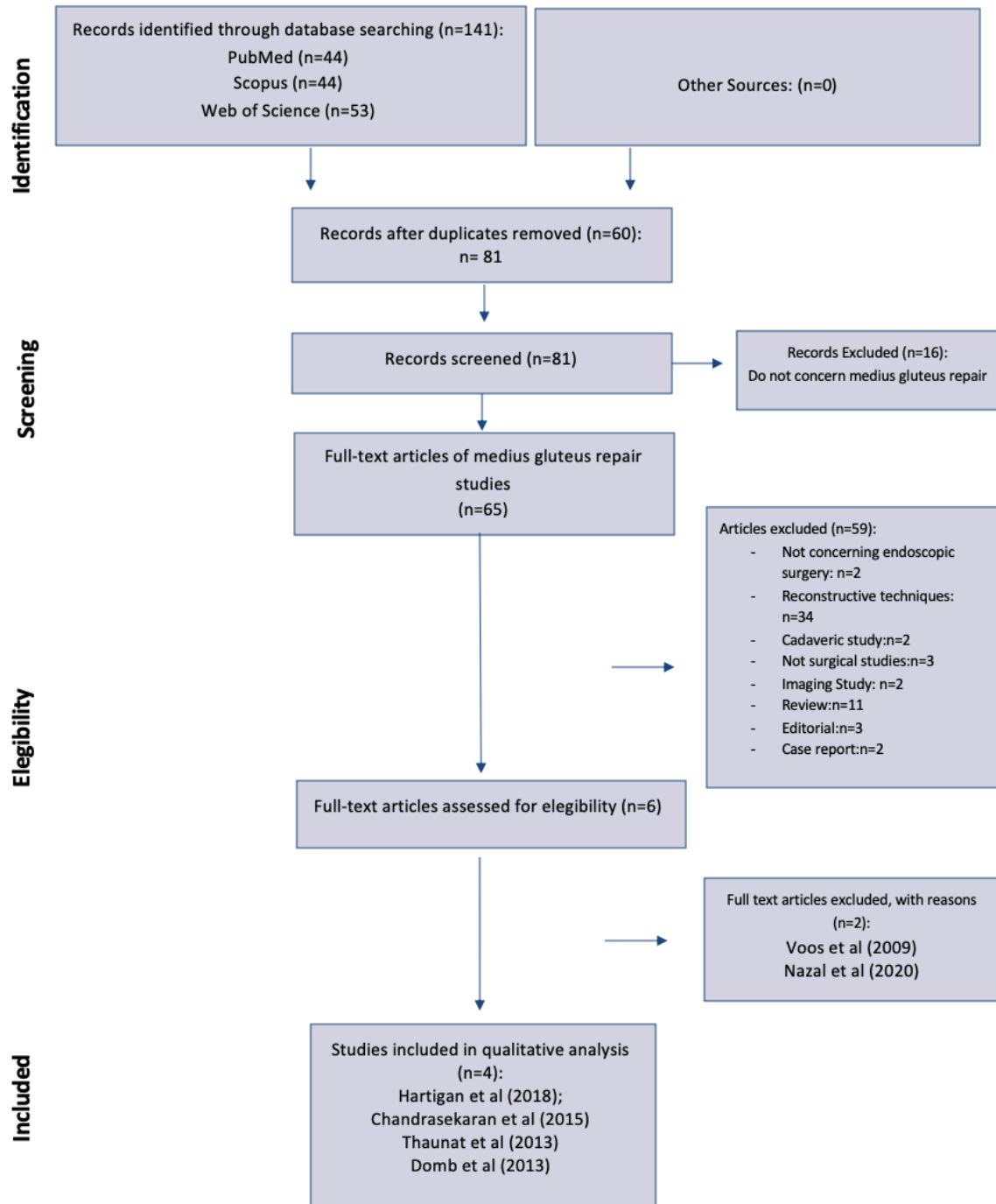


Figure 1. PRISMA flow-chart. Methodology of selection used to screen and include articles for qualitative analysis.

### **Selection criteria**

Only study in the English language and published in peer-reviewed journals were included. Using the Oxford Center of Evidence-Based Medicine guidelines, Level I to IV articles were identified. Studies with patients assessed pre-operative and then endoscopically for gluteus medius partial-thickness tear were included. Furthermore, studies reporting surgical repair of gluteus medius repair outcomes assessed by clinical examination and/or subjective evaluation scales, were included. Reviews, metaanalysis, cadaveric and animal studies, biomechanical studies, case report, commentaries, expert opinions and operative techniques were excluded. We also decided to exclude studies in which no information about the surgical procedure performed, diagnosis, follow-up, endoscopic or surgical assessment of gluteus medius repair, and clinical postoperative outcomes were recorded.

### **Evaluation of the study quality**

The methodological quality and bias of each study were evaluated with the Coleman Methodology Score (CMS), which assesses methodology with 10 criteria, giving a total score between 0 and 100. A score of 100 indicates that the study largely avoids chance, various biases, and confounding factors. The subsections that constitute the CMS are based on the subsections of the Consolidated Standards of Reporting Trials (CONSORT) statement (for randomized controlled trials). Each study was scored by two independent reviewers and matched each other (Table 1). In case of mismatch, a third investigator was asked to perform the CMS assessment independently. Possible disagreements were resolved by discussion.

### **Data extraction**

To avoid any bias of selection, the included articles with all the relative list of references, and the articles excluded from the study were reviewed, assessed, and discussed by all the authors. In case of disagreement among the reviewers regarding the selection of articles based on inclusion and exclusion criteria, the senior investigator made the final decision. The following data were independently extracted by all the investigators: demographics, including mean age, sex; mean follow-up; timing from symptoms to surgery; associated lesion reported; certainty of diagnosis by pre-operative clinical examination and endoscopic confirmation; surgical management and technique performed; clinical outcome measurements by post-operative clinical examination and/or subjective evaluation scales; recurrence of the lateral hip pain and/or pain and/or limping, and intra- and/or post-operative complications

## **RESULTS**

### **Study selection**

A total of 4 articles were included in the qualitative analysis. Figure 1 describes the methodology used for selection and inclusion of articles. The original literature search identified a total of 141 articles comprising of duplicates. No one other articles were identified by other sources. After removal of 60 duplicates, 81 articles were assessed for the eligibility. Fifteen articles were removed because they did not concern medius gluteus repair. Of the remaining 59 full-text articles, 52 articles were removed because do not meet inclusion criteria: eleven articles were excluded because were a review; two articles were excluded because cadaveric studies; two articles were excluded because they were only imaging studies; nine articles were excluded because they were case reports; three were excluded because they were reviews of literature; three article were not surgical studies; two articles were excluded because they were case reports; thirty-six articles were removed from the selection because not concerning endoscopic techniques. A total of 7 articles were therefore assessed. Finally, 4 articles were included for the qualitative analysis: Hartigan et al. (Hartigan et al., 2018), Thaunat et al. (Thaunat et al., 2013), Domb et al. (Domb et al., 2013) and Chandrasekaran et al. (Chandrasekaran et al., 2015). Two articles were excluded with reasons: Voos et al. (Voos et al., 2009) and

Nazal et al. (Nazal et al., 2020), were excluded because, although an endoscopic procedures, they concerns about full-thickness tears.

Table 1. Study characteristics.

Study	Year of publication	Level of evidence	Study design	Mean follow-up (months)	Coleman Methodologic Score (CMS)
Hartigan et al.	2018	IV	Retrospective case series	24	59
Thaunat et al.	2013	IV	Retrospective case series	6	43
Domb et al.	2013	IV	Retrospective case series	25.1	46
Chandrasekaran et al.	2015	IV	Cohort study	27.2	58

### Study characteristics and quality assessment

All the articles included for the qualitative analysis were published in the period 2013 to 2018, and their characteristics are summarized in the Table 1. The articles included are three retrospective case series and one cohort study, and their level of evidence according to the Oxford Center of Evidence-Based Medicine guidelines is IV. The mean follow-up was 18 months, ranging from 6 months (Thaunat et al., 2013) to 36 months (Chandrasekaran et al., 2015). According to the Coleman Methodologic Score (CMS), 2 articles (Domb et al., 2013; Thaunat et al., 2013) were of poor quality (<50), and two (Chandrasekaran et al., 2015; Hartigan et al., 2018) of fair quality (58 and 59). The median CMS was 51.5 (43-59) of a possible 100 total score.

Table 2. (A) Patient characteristics <sup>a</sup> and (B) Surgical indications <sup>a</sup>.

	Hartigan et al.	Thaunat et al.	Domb et al.	Chandrasekaran et al.
<b>A</b>				
N of patients	25	4	6	24
Mean age	53.5	53.5	53.5	53.5
Sex (Male/Female)	1M/24F	1M/24F	1M/24F	1M/24F
<b>B</b>				
Symptoms	Pain, Contraction	Pain, Contraction	Pain, Contraction	Pain, Contraction
Mean timing symptoms to surgery (months)	3	6	26.67	
Pre-operative clinical examination			Objective abductor weakness on manual strength testing. Failure of corticosteroid injections to provide lasting therapeutic benefit	Objective abductor weakness on manual strength testing; Trendelenburg sign
Pre-operative Imaging	MRI, coronal, sagittal, axial images	MRI	MRI	MRI

Note: <sup>a</sup> Blank cell indicate not available.

### Patient characteristics

Patient characteristics and surgery indications are reported in Table 2A-2B. A total of 59 patients with mean age 59.5 (range 38-79) years from the included articles was analysed. The diagnosis and the indications for surgery were based on patient symptoms, pre-operative clinical examination and imaging. In all the articles included, patients experienced symptoms such as pain and tenderness over greater trochanteric. The pre-operative clinical examination was based on the manual strength test to verify abductor weakness for both Domb et al. and Chandrasekaran et al. (Figure 2) that resulted positive in all patients (Chandrasekaran et al., 2015; Domb et al., 2013). Hartigan et al. and Thauinat et al. did not reported the results of any pre-operative clinical examination test (Hartigan et al., 2018; Thauinat et al., 2013). The imaging study to diagnose partial-thickness tears of gluteus medius was always the MRI scan for all included articles. The definitive diagnosis was done by direct endoscopic visualization of gluteus medius tears for all the included articles. The mean timing of symptoms to surgery was different among the included studies and it ranges from the 26.1 months reported in Domb et al. (2013) to 3 months of Hartigan et al. (2018).

### Surgical approach and suturing technique

In Table 3, the surgical technique performed is reported. To confirm the diagnosis and assess the partial-thickness tear of gluteus medius, endoscopic evaluation is fundamental. In all the articles included, direct endoscopic confirmation of partial tear was performed to evaluate the grade of retraction, fatty degeneration in order make the correct diagnosis and to plan the most appropriate treatment. Different endoscopic suturing technique are reported.

Table 3. Surgical characteristics <sup>a</sup>.

	<b>Endoscopic confirmation</b>	<b>Surgical procedure</b>	<b>Suturing technique</b>	<b>Associated lesion</b>
Hartigan et al.	Endoscopic probing and evaluation of retraction	All-inside transtendinous repair	Side-to side repair using two anchors (5.5-mm BioComposite Corkscrew anchors, Arthrex, Naples, FL)	
Thauinat et al.	Endoscopic probing and evaluation of retraction	All-inside transtendinous repair	Side-to-side repair using a resorbable 6.5-mm screwed anchors (Healix BR, Depuy Mitek Inc., Raynham, Massachusetts).	
Domb et al.	Endoscopic probing and evaluation of retraction (grade 2 in 4 patients and grade 3 in 2 patients)	All-inside transtendinous repair	Side-to side repair using two anchors (5.5-mm BioComposite Corkscrew anchors, Arthrex, Naples, FL)	Labral tears, chondral lesion.
Chandrasekaran et al.	Endoscopic probing and evaluation of retraction	All-inside transtendinous repair	Side-to side repair using two anchors (5.5-mm BioComposite Corkscrew anchors, Arthrex, Naples, FL)	

Note: <sup>a</sup> Blank cell indicate not available.

Thaunat et al. (2013) performed a side-to-side repair uses an anchor (U-shaped, with 2 sutures), or two (U-shaped, 4 sutures) in case of incomplete closure. Resorbable 6.5-mm screwed anchors were used (Healix BR, Depuy Mitek Inc., Raynham, Massachusetts). A bird-beak forceps or an automated Expressw suture-passer was used to pass through the greater trochanter (Depuy Mitek Inc., Raynham, Massachusetts) (Thaunat et al., 2013).

Hartigan et al., Chandrasekaran et al. and Domb et al. used the same suturing technique. After performed a longitudinal incision in the tendon in line with its fibres over the middle of the lateral facet, through a transtendinous window, the torn fibres were identified. Then the lateral facet was decorticated with use of a burr to create a bleeding bed of bone for healing. The repair was then performed by using a 5.5-mm BioComposite Corkscrew anchor (Arthrex, Naples, Florida) placed in the lateral facet under fluoroscopy, and two horizontal mattress stitches were passed, with one limb of each suture pulled through the anterior part of the tendon and the other suture limb pulled through the posterior part of the tendon. (Chandrasekaran et al., 2015; Hartigan et al., 2018)

### Outcome analysis

Table 4. Outcome <sup>a</sup>.

	Clinical outcome	Evaluation scales	Complications	Post-operative imaging
Hartigan et al.	Absence of pain; abduction strength test.	Modified Harris hip score (mHHS), the Nonarthritic Hip Score (NAHS), the Hip Outcome Score—Activities of Daily Living Subscale (HOS-ADL), and the Hip Outcome Score—Sport-Specific Subscale (HOS-SSS); VAS score.	None	MRI
Thaunat et al.	Absence of pain.	Mean modified Harris score and NHAS (Non Arthritic Hip Score).	None	MRI
Domb et al.	Abduction strength test; 2/6 persistent peritrochanteric pain.	Modified Harris hip score (mHHS), the Nonarthritic Hip Score (NAHS), the Hip Outcome Score—Activities of Daily Living Subscale (HOS-ADL), and the Hip Outcome Score—Sport-Specific Subscale (HOS-SSS); VAS score.	None	MRI
Chandrasekaran et al.	Absence of pain: abduction strength test.	Modified Harris hip score (mHHS), the Nonarthritic Hip Score (NAHS), the Hip Outcome Score—Activities of Daily Living Subscale (HOS-ADL), and the Hip Outcome. Score—Sport-Specific Subscale (HOS-SSS); VAS score.	None	MRI

Note: <sup>a</sup> Blank cell indicate not available.

Clinical outcome with evaluation subjective scales, peri-operative complications and post-operative imaging studies are reported in Table 4. For all four articles included, the clinical evidence at the final follow-up

demonstrate a complete resolution of pre-operative symptoms (pain and loss of strength of gluteus medius) in the most part of patients.

Hartigan et al. reported a significant improvement in all subjective scales reported (54.9 and 76.2, respectively, for the modified Harris Hip Score (mHHS); 50.2 and 80.6, respectively, for the Hip Outcome Scores-Activity Daily Living Subscale (HOS-ADL); 30.9 and 67.3, respectively, for the Hip Outcome Scores-Sport Specific Subscale (HOS-SSS); and 51.9 and 82.4, respectively, for the Non-Arthritis Hip Score (NAHS). These scores were all deemed significantly improved with  $P < .001$ . A significant improvement in Visual Analogic Score (VAS) was reported. Furthermore, a significant improvement of abductor strength of at least 1 grade in 64% of patients was reported. No complications and no relapse of symptoms was noted (Hartigan et al., 2018).

Chandrasekaran et al. reported a significant improvement of abduction strength, which was measured with manual muscle testing on a scale of 1 (weakest) to 5 (strongest), increased from a mean of 4.2 preoperatively to a mean of 4.5 postoperatively and increased by at least one grade in twenty-six of the thirty-four patients. Furthermore, subjective scales showed a significant improvement from pre-operatively values to post-operatively, except for the HOS-SSS (Chandrasekaran et al., 2015).

Thaunat et al. showed improvement in mean modified Harris score and NAHS (Non-Arthritic Hip Score) respectively from 35.7 (range, 20—54) and 38.3 (21—52) preoperatively to 74 (46—84) and 83 (64—95) at 6 months-follow-up (Thaunat et al., 2013).

Domb et al. reported objective strength improvement from a mean Medical Research Council (MRC) of 4.33 to 4.83 in the partial-thickness group. However, 2 of 6 patients in the partial-thickness group reported persistent peritrochanteric pain. Furthermore the subjective scales reported a significant improvement from pre-operative to post-operative condition with high grade of satisfaction (9.8/10) (Domb et al., 2013).

## DISCUSSION

Both open and endoscopic gluteal repairs have similar patient-reported outcome scores, pain scores, and improvement in abduction strength. Open techniques have a higher reported complication rate (Chandrasekaran et al., 2015). For this reason, in the last decade, endoscopic procedure to treat gluteus medius tears are becoming more popular, and many techniques are been developed. Voos et al. (2009) described a technique to repair gluteus tendon tears that could be seen from the peritrochanteric compartment (Voos et al., 2009). Because tears of gluteus medius and in particular partial-thickness tears are not visible from open and arthroscopic visualization of peritrochanteric space, endoscopic approach to gluteus medius is been developed by Domb et al., by using trans-tendinous repair of partial tears of medius gluteus (Domb, Nasser & Botser, 2010). In this systematic review, the effectiveness and the clinical and functional outcomes of trans-tendinous repair of partial gluteal tears are analysed. For this purpose, four articles, written between 2013 and 2018, have been analysed. A total of 59 patients were counted and underwent surgical endoscopic repair by trans-tendinous technique for partial tears of gluteus medius. Hartigan et al. in their study, counted the highest number of patients treated with trans-tendinous repair (25 patients), that represent the most relevant series in literature for PUSTA (Hartigan et al., 2018). The general rate female/male is 6:1, confirming data reported in literature. The mean age is 59, indicating that partial tears occurs more frequently around the fifth/sixth decade of life, suggesting a progressive chronic onset due to continuous frictioning of gluteal tendon with relative degeneration. On the other hand, full-thickness tears are more often of traumatic nature and they occurs in younger patients (Domb et al., 2013; Domb & Carreira,



2013; McCormick et al., 2013; Voos et al., 2009). Symptoms are not very peculiar of this onset, that it characterised by pain at great trochanter region, tenderness at palpation and weakness with typical Trendelenburg gait (Byrd, 2013; Chandrasekaran et al., 2015; Domb et al., 2013; Domb & Carreira, 2013; Hartigan et al., 2018; Voos et al., 2009). These symptoms are often confused with a bursitis and the correct diagnosis is often missed or delayed. In all the articles analysed, a pre-operative clinical examination is performed, and in particular in Chandrasekaran et al. and Domb et al. studies, an objective muscle strength manual testing was performed. MRI was performed in all the studies to detect gluteus medius tears. For this reason, recognise early and treat as soon as possible these tears is important to restore the footprint of gluteus medius to its insertion, gaining strength to all the abductor muscle complex.

The surgical technique performed by all the authors is an all-inside trans-tendinous technique, first described by Domb et al. in 2010 (Domb et al., 2010).

Hartigan et al, Chandrasekaran and Domb et al. performed the same suturing technique and endoscopic fixation (Chandrasekaran et al., 2015; Domb et al., 2013; Hartigan et al., 2018).

Thaunat et al., although performed a trans-tendinous technique used different suturing technique with different anchors diameters (6.5 instead of 5.5) (Thaunat et al., 2013). All the surgeons preferred to use two anchors.

The mean follow-up among the studies analysed is 18 months. Among the articles included, on 59 patients, only 2 patients (3.3%) reported in Domb et al. study, showed a relapse of symptoms (pain) at great trochanteric region. No one reported intra- or peri-operative complications, indicating that endoscopic repair is safe and effective technique, with lower rate of complications in comparison with open procedure (Chandrasekaran et al., 2015). Subjective scales analysed by the authors (modified Harris hip score, the Nonarthritic Hip Score, the Hip Outcome Score—Activities of Daily Living Subscale, and the Hip Outcome Score—Sport-Specific Subscale) indicate that all the values increased post-operatively in comparison with pre-operative levels. Among all the articles the mean VAS score pre-operatively is 6.9, while post-operatively is 1.8, suggesting an important effect on pain relief. Furthermore, Hartigan et al, Domb et al. and Chandrasekaran et al. reported a significative improvement in abductor strength: in Hartigan et al. study, 7 patients (64%), on a total of 11 with reported weakness of abductor, improved their strength; Chandrasekaran et al. reported an improvement of 0.29 in MRC grade between pre-operatively and post-operatively values, while in Domb et al. in 50% of patients an improvement of at least 1 grade of MRC grading was recorded (Chandrasekaran et al., 2015; Domb et al., 2013; Hartigan et al., 2018). These data suggest that in the largest of patients with a typical Trendelenburg gait for abductor insufficiency, restoring the integrity of footprint is fundamental to give strength and continuity to the gluteus medius, let the patients to return to a normal gait.

### **Limitations**

The limitations of the present systematic review are related to the scanty quality of the studies available in the literature. All the articles included were retrospective case series and one cohort study, with limited number of patients. The level of evidence for all the articles included was low (IV). According to the Coleman Score, the study quality ranges from fair to poor. Furthermore, the absence of randomized controlled study or prospective study represents a limitation for this review.

### **CONCLUSION**

Endoscopic repair of partial-thickness tear of gluteus medius is a safe and effective technique. Trans-tendinous technique represents the gold standard to treat endoscopically these injuries. It is important to

recognize and treat as soon as possible partial tears of gluteus medius in order to avoid excessive weakness of abductor complex and chronic pain to great trochanteric region. The subjective scales and the functional outcome indicate that trans-tendinous endoscopic technique is effective to pain relief and to gain strength to gluteus medius. Further investigations with larger number of patients and randomized controlled trials will be useful to better understand the efficacy of this procedure and to validate it definitively.

## REFERENCES

- Alpaugh K., Chilleli BJ, Xu S. & Martin SD (2015). Outcomes after primary open or endoscopic abductor tendon repair in the hip: A systematic review of the literature. *Arthroscopy*, 31:530-540. <https://doi.org/10.1016/j.arthro.2014.09.001>
- Byrd J. W. T. (2013). Gluteus Medius Repair With Double-Row Fixation. *Arthrosc Techn*, 2(3), e247–e250. <https://doi.org/10.1016/j.eats.2013.02.015>
- Chandrasekaran S., Gu, C., Hutchinson M. R., Lodhia P., Suarez-Ahedo C. & Domb B. G. (2015). Outcomes of Endoscopic Gluteus Medius Repair. *JBone Joint Surg Am.*, 97(16), 1340–1347. <https://doi.org/10.2106/jbjs.n.01229>
- Chandrasekaran S., Lodhia P., Gui C., Vemula S. P., Martin T. J. & Domb B. G. (2015). Outcomes of Open Versus Endoscopic Repair of Abductor Muscle Tears of the Hip: A Systematic Review. *Arthroscopy*, 31(10), 2057-2067.e2. <https://doi.org/10.1016/j.arthro.2015.03.042>
- Domb B. G., Botser I., & Giordano B. D. (2013). Outcomes of endoscopic gluteus medius repair with minimum 2-year follow-up. *Am J Sports Med* 41(5), 988–997. <https://doi.org/10.1177/0363546513481575>
- Domb B. G. & Carreira D. S. (2013). Endoscopic Repair of Full-Thickness Gluteus Medius Tears. *Arthrosc Techn*, 2(2), e77–e81. <https://doi.org/10.1016/j.eats.2012.11.005>
- Domb B. G., Nasser R. M., & Botser I. B. (2010). Partial-thickness tears of the gluteus medius: Rationale and technique for trans-tendinous endoscopic repair. *Arthroscopy*, 26(12), 1697–1705. <https://doi.org/10.1016/j.arthro.2010.06.002>
- Hartigan D. E., Perets I., Ho S. W., Walsh J. P., Yuen L. C., & Domb B. G. (2018). Endoscopic Repair of Partial-Thickness Undersurface Tears of the Abductor Tendon: Clinical Outcomes With Minimum 2-Year Follow-up. *Arthroscopy*, 34(4), 1193–1199. <https://doi.org/10.1016/j.arthro.2017.10.022>
- Mccormick F., Alpaugh K., Nwachukwu B. U., Yanke A. B. & Martin S. D. (2013). Endoscopic repair of full-thickness abductor tendon tears: Surgical technique and outcome at minimum of 1-year follow-up. *Arthroscopy*, 29(12), 1941–1947. <https://doi.org/10.1016/j.arthro.2013.08.024>
- Thaunat M., Chatellard R., Noël E., Sonnery-Cottet B., & Nové-Josserand L. (2013). Endoscopic repair of partial-thickness undersurface tears of the gluteus medius tendon. *Orthop Traumat Surg Res*, 99(7), 853–857. <https://doi.org/10.1016/j.otsr.2013.06.005>
- Thaunat M, Noël E., Nové-Josserand L., Murphy, C. G., Sbiyaa M., & Sonnery-Cottet B. (2016). Endoscopic management of gluteus medius tendon tears. *Sports Med Arthr Rev.*, 24(1), 11–18. <https://doi.org/10.1097/jsa.0000000000000082>
- Voos J. E., Shindle M. K., Pruett A., Asnis P. D., & Kelly B. T. (2009). Endoscopic repair of gluteus medius tendon tears of the hip. *Am J Sports Med.*, 37(4), 743–747. <https://doi.org/10.1177/0363546508328412>
- Yanke A. B., Hart M. A., McCormick F., & Nho S. J. (2013). Endoscopic repair of a gluteus medius tear at the musculotendinous junction. *Arthrosc Techn*, 2(2), e69–e72. <https://doi.org/10.1016/j.eats.2012.11.004>



This work is licensed under a [Attribution-NonCommercial-NoDerivatives 4.0 International](https://creativecommons.org/licenses/by-nc-nd/4.0/) (CC BY-NC-ND 4.0).