



GLOBAL JOURNAL OF MEDICAL RESEARCH: J DENTISTRY & OTOLARYNGOLOGY

Volume 20 Issue 3 Version 1.0 Year 2020

Type: Double Blind Peer Reviewed International Research Journal

Publisher: Global Journals Inc. (USA)

Online ISSN: 2249-4618 & Print ISSN: 0975-5888

Incidence and Outcome of Vocal Cord Polyp: An Endoscopic Experience and Perception

By Delwar AHM, Chowdhury NK, Rahman MS, Khan AM & Hossain ABMT

Abstract- Background: The larynx is an intricate part of the body which has to perform a very composite function like protection, respiration, phonation. To carry out the function, larynx should be adaptable and flexible. Any structural disorder like vocal cord polyp alter these specialized function and squander the laryngeal pacing, and increasing voice discomfort of the patient like hoarseness, dysphonia, and odynophagia day by day. Phonosurgery is the mainstay of treatment.

Methods: It is a cohort retrospective study of 54 cases in the Department of Otolaryngology and Head-Neck Surgery, Comilla Medical College, Bangladesh, from 20 February 2017 to 27 October 2019.

Result: Incidence of vocal cord polyp in laryngeal disorder patient was 6.83%, and the laryngeal operative patient was 28.27%. All patients were treated by micro laryngeal surgery with rigid Hopkin's laryngeal telescope, and setback was 2 (3.70%). Of them, male were 41(75.92%), females were 13(24.08%), below 20 years were 2(3.70%), 20-50years 39(72.23%), and above 50years 13(24.07%), unilateral was 50(92.59%) and 4(7.41%) were bilateral, smoker was 41(75.92%), nonsmoker 13(24.08%), industrial workers were 21(38.89%), professional voice user was 13(24.07%).

Keywords: vocal cord polyp, micro laryngeal surgery (MLS), gastroesophageal reflux disease (GERD), laryngopharyngeal reflux (LPR).

GJMR-J Classification: NLMC Code: WU 610



Strictly as per the compliance and regulations of:



Incidence and Outcome of Vocal Cord Polyp: An Endoscopic Experience and Perception

Delwar AHM ^α, Chowdhury NK ^α, Rahman MS ^ρ, Khan AM ^ω & Hossain ABMT [¥]

Abstract- Background: The larynx is an intricate part of the body which has to perform a very composite function like protection, respiration, phonation. To carry out the function, larynx should be adaptable and flexible. Any structural disorder like vocal cord polyp alter these specialized function and squander the laryngeal pacing, and increasing voice discomfort of the patient like hoarseness, dysphonia, and odynophagia day by day. Phonosurgery is the mainstay of treatment.

Methods: It is a cohort retrospective study of 54 cases in the Department of Otolaryngology and Head-Neck Surgery, Comilla Medical College, Bangladesh, from 20 February 2017 to 27 October 2019.

Result: Incidence of vocal cord polyp in laryngeal disorder patient was 6.83%, and the laryngeal operative patient was 28.27%. All patients were treated by micro laryngeal surgery with rigid Hopkin's laryngeal telescope, and setback was 2 (3.70%). Of them, male were 41(75.92%), females were 13(24.08%), below 20 years were 2(3.70%), 20-50years 39(72.23%) and above 50years 13(24.07%), unilateral was 50(92.59%) and 4(7.41%) were bilateral, smoker was 41(75.92%), nonsmoker 13(24.08%), industrial workers were 21(38.89%), professional voice user was 13(24.07%). The patient's symptoms were divided into three categories rely on an auditory-perceptual evaluation method GRBAS (Grade of hoarseness: Roughness, Breathiness, Asthenia, and Strain) slight degree was 34(62.96%), medium 13(24.08%), and high 7(12.96%). There is another group of people reflux-related disease RSI (Reflux symptom index) was 21(38.89%).

Conclusion: Multidimensional assessment and multi-professional team approach towards the treatment of a patient may fulfill the patient vocal requirement.

Keywords: vocal cord polyp, micro laryngeal surgery (MLS), gastroesophageal reflux disease (GERD), laryngopharyngeal reflux (LPR).

I. INTRODUCTION

For speech, normal structure of the vocal cord is essential that consists of epithelium and lamina propria or vocal ligament in which superficial layer or Reinke's space is most important. It is a potential space containing scanty connective tissue only. Phonation is making sounds that may be expressed by motor activity involves a highly specialized orchestration of laryngeal and respiratory neuromuscular discipline.¹ Periaqueductal grey matter(PAG) in the midbrain is an imperative site for mammalian voice production.² Vocal cord polyp is a nodular lesion which is a benign

enlargement from the free edge of vocal cord which size is greater than three mm.³ Phonotrauma due to vocal cord abuse or misuse, screaming or shouting, irritation due to smoking or industrial fumes, allergy and repeated infection is a significant factor in approbation for it.⁴ Vocal abuse is misapplying of voice that strains or injures the vocal cord that comprises excessive talking, speaking too loudly or at an abnormally high or low pitch.⁵ Acute infective laryngitis and laryngopharyngeal reflux also irritates the vocal cords as a consequence of the production of vocal cord polyp.⁶ Almost all vocal cord polyp patients had a history of cigarette smoking, and also an industrial workers who inhaled fumes everyday causes injury to a vocal cord leading to hyaline degeneration in polyps.⁷ The vocal cord polyp may be hemorrhagic or gelatinous in appearance. The upshot of hemorrhagic polyp is disruption of the vascular basement membrane, capillary proliferation, thrombosis, minute hemorrhage, and fibrin exudation.⁸ The consequence of the formation of gelatinous polyp is unknown.⁹ They strike men more than women, and conventionally the age is between 4 to 6 decade. Vocal cord polyps are benign and most constitutional abnormalities, which are 41% of all benign laryngeal disease.¹⁰ It alters the quality, creating rough voice which has lowered in pitch, cuts out in a speech that they have lost the part of the latitude of voice causes straining to talk.¹¹ However, treatment options of vocal cord polyp both medical and surgical or combined due to multiple etiological factors. Any inflammatory condition and laryngopharyngeal (LPR) or gastroesophageal reflux disease is treated by appropriate and effective drugs.¹² Voice therapy, preventive therapy may make the symptoms comfortable, but the resolution of polyp is scarcely possible.¹³ Different types of technical approaches are available in micro laryngeal surgery. Horace Green described first direct laryngoscopic removal of vocal cord polyp.¹⁴ Oskar Kleinsasser described the adaptation of micro laryngoscopy and endolaryngeal microsurgery for fine manipulation of the vocal cord.¹⁵ Benninger used the CO₂ laser and concluded that with the expert hand, it was excellent for phono surgery.¹⁶ Some Surgeons were using a power instrument microdebrider but, knowledge of the accurate depth of resection should be learned before using it. Some study reports concluded that less post-operative pain in microdebrider surgery and faster return to normal voice.¹⁷

Author α : e-mail: mamun.delwar196@gmail.com

Our aim of the study is to find out the relative incidence, frequency, and presentation of vocal cord polyp and to compare the empirical study of different types of surgical procedures.

II. METHODS AND MATERIALS

It is a cohort retrospective study of 54 patients who were attended in the outdoor with laryngeal disorder especially hoarseness of voice from 02 February 2017 to 10 October 2019 in the Department of Otolaryngology and Head-Neck Surgery, Comilla Medical College Hospital, Bangladesh. Out of three years outpatients, 791 patients were suffering from the laryngeal disorder. We performed the endoscopic assessment of all patients by rigid Hopkin's laryngeal telescope. Before examination, we used the 10-15% lidocaine spray in the oral cavity and oropharynx of the patient to prevent gag reflex, which mostly interfere with the examination and proper view of the larynx. The patient and the attendant, if the patient was the children gave the informed written consent about the examination procedure. Of 791 patients, 54 diagnosed as a vocal cord polyp. During that time, 191 routine laryngeal operative procedures were performed in which vocal cord polyp were 54 and post-operative recurrence was 2. We used GRBAS and RSI scale to determine the grading of severity and reflux-related to vocal cord polyp. The following data collected about the patient: Age, Sex, Personal habit, Occupation, operations, post-operative follow up, and complications. All data calculated by using the statistical software of SAS.

III. RESULTS

The incidence of vocal cord polyp in total laryngeal disorder patients (791) was 6.83%, and total laryngeal surgery (191) was 28.27%. In our hospital set

up we were following rigid laryngoscope set up with rigid Hopkin's laryngeal telescope 0° to perform MLS of vocal cord polyp. Recurrence after operation was 2(3.70%) (Figure-1). We were follow-up the patient 15 days interval for one month and monthly for three months. The recurrent two patients were a smoker. After 15 days of operation, they started smoking again. Junior trainee surgeons performed some operations. So both patient awareness factor and competent surgeon factor were responsible for the recurrence. Amidst 54, male was 41(75.92%) females were 13(24.08%) (Figure-1). Regarding side, unilateral was 50(92.59%) in which left side 29(58%), and right side 21(42%), and bilateral were 04(7.41%) (Figure-1). Age allocated 10-20 years were 2(3.70%), 20-30 years were 12(22.23%), 30-40 years were 14(25.93%), 40-50 years were 13(24.07%) and above 50 years were 13(24.07%) whereas the maximum incidence in between 3rd to 5th decade was 39(72.23%) in which lowest age was 13 and highest one was 89 years whereas mean age was 47.26 years (Figure-2). Personal history revealed smoker was 41(75.92%), non-smoker was 13(24.08%), industrial workers were 21(38.89%), and professional voice user was 13(24.08%) like Hawker, Teacher, leader and the 13 years old boys was a student of Madrasa where he was bound to read Holy Quran with a very robustious voice (Figure-3). The presenting symptoms divided into three categories depending on the auditory-perceptual evaluation method of hoarseness is the GRBAS scale, which gives scores of 0, 1, 2 or 3 for the Grade of hoarseness: Roughness, Breathiness, Asthenia, and Strain, where 00 is normal, 01 is a slight degree, 02 is a medium degree, and 03 is a high degree.^{18,19} In our study, slight degree was 34(62.96%), the medium was 13(24.08%), and the high was 07(12.96%)(Figure-4). RSI scale indicated the GERD or LPR related vocal cord polyp was 21(38.89%)²⁰(Figure-4).

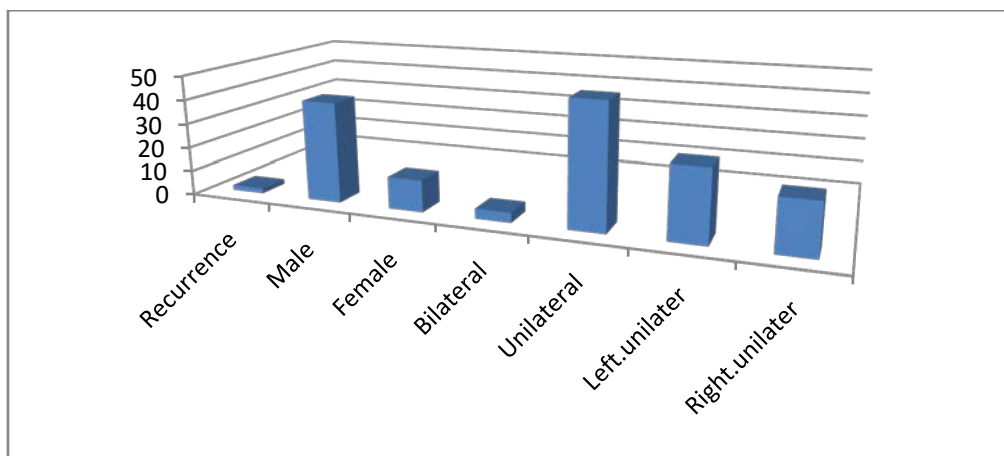


Figure-1: Recurrence after surgery, Gender epidemiology and Side distribution. [n=54; Recurrence-2(3.70%); {Gender epidemiology; Male-41(75.92%); Female-13(24.08%)}; {Side distribution; Bilateral-4(7.41%); Unilateral-50(92.59%); Left-29(58%); Right-21(42%)]

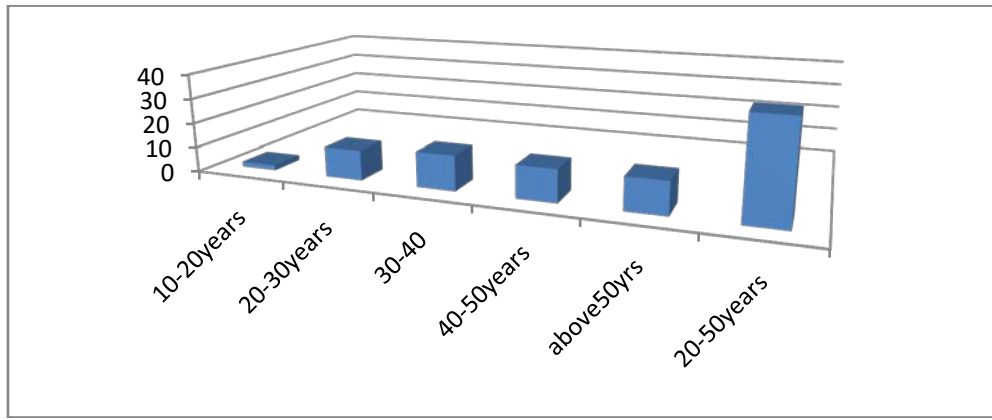


Figure-2: Age Allocation {n-54;10-20yrs-2[3.70%]:20-30yrs-12[22.23%]:30-40yrs-14[25.93%]:40-50yrs-13[24.07%]: Above 50 yrs-13[24.07%]: 20-50 years-39[72.23%]}

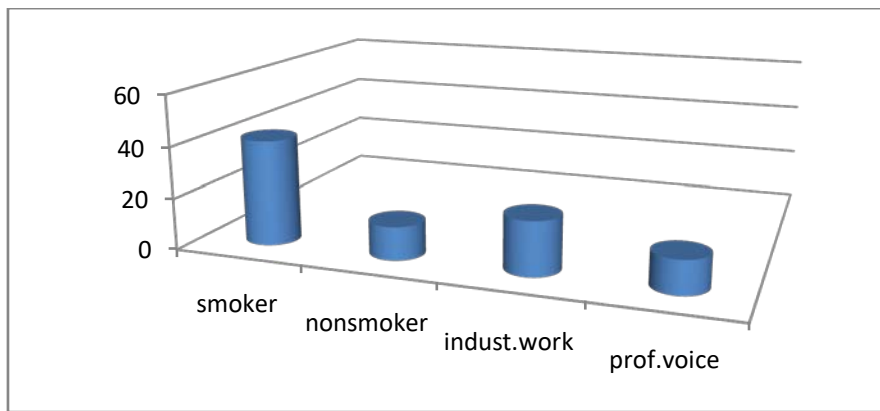


Figure-3: Personal History. [n-54;Smoker-41(75.92):Nonsmoker 13(24.08%):Industrial worker-21(38.89%):Professional voice user-13(28.08%)]

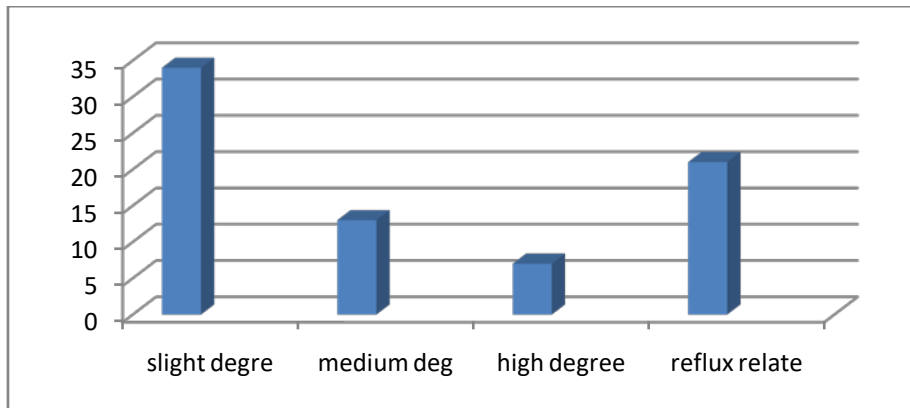


Figure-4: Presenting features: [n-54;Slight degree-34(62.96%):Medium-13(24.08%):High-7(12.96%):Reflux related-21(38.89%)]

IV. DISCUSSION

The incidence of vocal cord polyp in our study was 6.83% and 28.27% in a different study groups. Due to the discrete study group there was a divergent result in which Vasconcelos D. et al. showed incidence in smoker and GERD group was 1.0-1.7%.²¹ Goswami S. et al. series displayed 16.86% vocal cord polyp in total laryngeal disorder patient.²² But Woo et al. series

revealed that vocal cord polyp were the second most prevalent laryngeal lesion.²³ In our endoscopic assessment and evaluation of study, vocal cord polyp was the fourth type of the laryngeal disorder.

In gender epidemiology, male were predominant in our study, supported by a large number of studies.²⁴ But fewer research work arrayed female preponderance may be due to a large number of

women of those countries were working in voice profession.²⁵

About personal habits, 75.92% were smokers that also held up by other studies.²⁶ Every-where in the road, market, public places even in hospitals people smoke without any hesitation.

Regarding age, in our study displayed maximum age incidence was 3rd to 5th decade in which was followed out by the Karagama YG. et al. series where he stood up for 4th to 6th decade.²⁷ Some other studies showed that the maximum age incidence in the 5th decade.²⁸

About laterality, Goswami S. et al. series showed only unilateral polyp; bilateral polyp was absent in their study.²² In our work, it was 7.4% which kept up by Kleinasser O. series that was 5%.¹⁵

In presenting features we followed the auditory-perceptual evaluation method for hoarseness in which the slight degree was 62.96%, the medium degree was 24.08%, and the high degree was 12.96%) near other studies of Hirano M. study and Okano W. et al. series.^{18, 19} Another group of the patient presented with GERD and LPR related symptoms was 38.89% which supported by Mosca F. et al. series used RSI.²⁹

About treatment of vocal cord polyp, some study displayed medical or non-invasive treatment, which included voice rest, menthol steam inhalation, anti-allergic, anti-reflux, and antiulcer drug with speech and language therapy for voice disorders and preventive measure relieved the symptom.³⁰ In our study, we were treated the patient by both surgical and medical modalities. In our surgical set up, we practiced MLS by rigid Hopkin's laryngeal telescope.³¹ Recurrence was 2 cases in our study, which was against Goswami S. et al report, in their series recurrence was 18 in 129.²² After surgical treatment, we advised them verbally and write in discharge paper to avoid vocal misuse, overuse and abuse, and refrain from smoking forever, which was an important factor in relapse.³²

We were follow-up the patient for four months after surgery, fifteen days interval for monthly and monthly for three months. The recurrence cases did not stop their smoking and continued the voice abuse, and these two cases polypectomy did the junior trainee surgeon, which may be the factor of incomplete clearance of the disease. Another 52 cases properly maintained the advice and their voice was fine up to the last follow-up.³³

V. CONCLUSION

Vocal cord polyp is one of the common laryngeal disorders which occur in middle-aged people and intervene with the quality of life. Rapid industrialization without proper management of its fume and uncontrolled smoking is the common cause of vocal cord polyp like developing, and also the

developed countries. Fast and spicy food increases the number of GERD and LPR patient, another factor to raise the vocal cord polyp need multi-professional treatment approach. Prevention and change of personal habit decrease the incidence of vocal cord polyp. Surgery and voice rest are the principal treatment modalities of vocal cord polyp. Surgery aims is to restore normal voice by making the edge of vocal cord smooth and disease-free. Expert surgeons and responsible patients reduce the recurrence rate.

Funding: No funding sources.

Conflict of interest: None declared.

Ethical approval: The study was approved by the Institutional Ethics Committee.

REFERENCES RÉFÉRENCES REFERENCIAS

1. Loucks TM, Poletto CJ, Simonyan K. et al. Human brain activation during phonation and exhalation common volitional control for two upper airway function. *Neuroimage* 2007; 36(1): 131-43
2. Davis PJ, Zhang SP, Winkworth A, Bandler R. Neural control of vocalization, respiratory and emotional influences. *J Voice* 1996; 10 23-38.
3. Wallis L, Jackson-Menaldi C, Holland W, Giraldo A. A vocal fold nodule vs vocal fold polyp: answer from surgical pathologist and voice pathologist point of view. *J Voice* 2004; 18:125-9.
4. Bastan RW, Thomas JP. Do talkativeness and vocal loudness correlate with laryngeal pathology? A study of the vocal overdoer/underdoer continuum. (*ejournals/linkout/10.1055/5-0038-1675391/id/jr0802 um-25*). *J Voice* 2016; 30(05): 557-562.
5. Ciprtani NA, Martin DE, Corey JP. The clinic-pathologic spectrum of benign mass lesion of the vocal fold due to vocal abuse. *Int J. Surg Pathol* 2011; 19(5):583-7.
6. Koufman JA. The Otolaryngologic manifestation of gastroesophageal disease (GERD): a clinical investigation of 225 patient using ambulatory 24 hours pH monitoring and an experimental investigation of the role of acid and pepsin in the development of laryngeal injury. *Laryngoscope* 1991; 101(4p:2suppl53):1-78.
7. Effat KG, Millad M. A comparative histopathological study of vocal fold polyps in smokers versus non-smokers. *J Laryngol Otol* 2015; 129(5):484-8.
8. Bykova VP, Kochesokova EA, Ivanchenko GF, Rotova ID. The morphology of vocal fold polyps and Mucosa in Reinke's edema. *Arkh Patol.* 2015; 77(1):30-7.
9. Martin RH, Defaveril, Domingues MA, de Albuquerque e Silva R. Vocal polyps: Clinical, morphological and immunohistochemical aspects. *J voice* 2011; 25(1): 786-792.
10. Singh M. Bandyopadhyay S. Gupta SC. & Rai A. Benign Laryngeal Lesion-a clinicopathological study

- of eleven years and a case report of pleomorphic lipoma. *Indian Journal of Otolaryngology and Head-Neck Surgery*. 2002; 54(3):242-245.
11. Coltron RH, Woo P, Brewer DW, et al. Stroboscopic signs associated with benign lesion of the vocal folds. *J Voice* 2002; 9:312-25.
 12. Koufman JA. Perspective on laryngopharyngeal reflux: from silence to omnipresence. *Classics in voice and laryngology*. San Diego: Plural Publishing; 2009. P. 179-266.
 13. Jeong WJ, Lee SJ, Lee WY, et al. Conservative management for vocal fold polyps. *JAMA Otolaryngol Head Neck Surg*. 2014; 140(5):448-52.
 14. Green H. *Morbid growth within the larynx*. New York; GP Putnam: 1852.
 15. Kleinsasser, O. Pathogenesis of vocal cord polyps. *Annals of Otolaryngology, Rhinology & Laryngology*. 1982; 91(4):378-381.
 16. Benninger MS. Microdissection or Microspot CO₂ laser for limited vocal fold benign lesions: a prospective randomized trial. *Laryngoscope* 2000; 110:1-17.
 17. Patel RS, Mackenzie K. Powered Laryngeal Shavers and Laryngeal Papillomatosis: a preliminary report. *Clin Otolaryngol* 2000; 25: 358-60.
 18. Hirano M. *Clinical examination of voice*. New York. 1981; Springer-verleg:43-65.
 19. Okano W, Tada Y, Omori K. Laryngeal disorders- This is how I examine vocal cord polyps/nodes(1). *JOHNS*. 2009; 25:535-538.
 20. Betelefsky PC, Postma GN, Koufman JA. Validity and reliability of the reflux symptom index (RSI) *J Voice* 2002;16:274-7.
 21. Vasconcelos D, Gomes A, Araujo C, Vocal fold polyp; Literature review. *Int Arch Otorhinolaryngol* 2019; 23(1): 116-24.
 22. Goswami S, Kesarwaani S, Basumata DK. *Saudi J Med*. 2018; May (Vol-3):196-201.
 23. Woo SH, Kim RB, Choi SH, Lee SW, Won SJ. Prevalence of laryngeal disease in South Korea: data from the Korea National Health and Nutrition Examination Survey from 2004 to 2011. *Yonsei Med J* 2014; 55(02)499-507.
 24. Nagata K, Kurita S, Yasumoto S, Maeda T, Kawasaki H & Hirano M. Vocal fold polyps and nodules. A 10-year review of 1156 patients. *Auris Nasus Larynx*, 1943; 10:S27-S35.
 25. Dursan G, Karatayli-Ozgursoy S, Ozgursoy OB, Tezcaner ZC, Courh I, Kilic MA. Influence of the macroscopic features of vocal fold polyps on the quality of the voice: a retrospective review of 101 cases. *Ear Nose Throat J* 2010; 89(03) E12- E17.
 26. Effat K. G, and Milad M. (2015) A comparative histopathological study of vocal fold polyps in Smokers versus Nonsmokers. *The Journal of Laryngology & Otology*, 129(5); 484-488.
 27. Karagama YG & McGlashan JA. *Scott-Brown's Otorhinolaryngology Head and Neck Surgery*. 8th Edition (2019), Volume-3, Chapter-63, P-950.
 28. Bastian R.W. Keider A. Verdolini-Marston K. Simple vocal tasks for detecting vocal fold swelling. *Journal of voice*. 1990; 4(2):172-1.
 29. Mosca F, Rossillo V, Leone CA. Manifestation of gastro-pharyngo-laryngeal reflux disease. *Acta Otorhinolaryngol Ital*. 2006; 26(5): 247-51.
 30. Klein AM, Lehmann M, Hapner ER, Johns MM.(2009) Spontaneous resolution of hemorrhagic Polyps of the true vocal fold. *Journal of voice*. 23(1), 132-135.
 31. Zeitels SM, Hilman RE, Desloge R, et al. Phonosurgery in singers and performing artists: Treatment outcome, management theories and future directions. *Ann Otol Rhinol Laryngol* 2002; 111:21-40.
 32. Wang CT, Liao LJ, Lai MS, Cheng PW. Comparison of benign lesion regression following vocal fold steroid injection and vocal hygiene education. *The Laryngoscope*. 2014; 124(2):510-515.
 33. Hojslet PE, Moesgaard-Nielsen V, Karlsmose M. Smoking cessation in chronic Reinke's edema. *The Journal of Laryngology & Otology*. 1990; 104(8):626-628.