

CASE REPORT

Anatomical Variations of the Lumbrical Muscles Causing Carpal Tunnel Syndrome

BENNY E, PARMINDER GS, NUR AZUATUL AK, TAN JA, AHMAD
SUPARNO B, JAMARI S, SHALIMAR A

Hand and Microsurgery Unit, Department of Orthopaedics and Traumatology, Faculty of Medicine, Universiti Kebangsaan Malaysia Medical Centre, Jalan Yaacob Latif, Bandar Tun Razak, 56000 Cheras, Kuala Lumpur, Malaysia.

ABSTRAK

Pelbagai jenis variasi anatomi terdapat di sekeliling terowong karpal namun variasi yang menyebabkan sindrom terowong karpal jarang berlaku. Tambahan pula, pembedahan terowong karpal sering dilakukan oleh pakar bedah yang muda yang seringkali tidak sedar akan variasi anatomi menyebabkan pembedahan yang kurang memuaskan. Kami ingin memberi fokus kepada kes otot lumbrikal penyebab sindrom terowong karpal. Seorang lelaki berumur 73 tahun mempunyai simptom kebas dan sakit di kedua-dua belah tangan bersama dengan bengkak di kawasan pergelangan tangan. Pada mulanya hanya tangan kanannya yang kebas, namun setahun kemudian, tangan kirinya pula kebas. Pemeriksaan fizikal semua positif untuk pemeriksaan Durkan, Phalen dan Tinel di terowong karpal. MRI menunjukkan otot-otot yang tidak normal di dalam terowong karpal. Semasa pembedahan terowong karpal, didapati otot lumbrikal mempunyai asal yang agak proksimal di dalam lengan (forearm) dan bukan di dalam tangan seperti kebiasaannya. Juga, di sebelah kiri, ada tumbesaran otot lumbrikal yang lebih besar dari kebiasaan. Kedua faktor ini menyebabkan tiada cukup ruang di dalam terowong karpal. Selepas pembedahan, pesakit sembuh dengan baik tanpa sakit dan kebas yang berkurangan. Variasi anatomi di terowong karpal tidak jarang dan boleh menyebabkan sindrom terowong karpal. Juga, pembedahan terowong karpal tidak boleh diambil senang dan pakar bedah hendaklah mengetahui tentang kemungkinan variasi begini berlaku.

Kata kunci: anatomi, median, lumbrikal, otot, sindrom terowong karpal, tumbesaran, urat saraf variasi

Address for correspondence and reprint requests: Assoc. Prof. Dr. Shalimar Abdullah. Hand and Microsurgery Unit, Department of Orthopaedics and Traumatology, Faculty of Medicine, Universiti Kebangsaan Malaysia Medical Centre, Jalan Yaacob Latif, Bandar Tun Razak, 56000 Cheras, Kuala Lumpur, Malaysia. Tel: +603-9145 6005 Email: kelapa44@yahoo.com

ABSTRACT

Many anatomical variations exist in and around the carpal tunnel. However, symptomatic anomalies causing carpal tunnel syndrome is rare. Additionally, carpal tunnel surgery is considered a simple operation commonly done by junior surgeons who are usually unaware of variations resulting in unfavorable surgical outcomes. We highlight a case of lumbrical muscle variation causing carpal tunnel syndrome. A 73-year-old male presented with numbness and pain of both hands associated with abnormal fullness over both wrists and distal forearms. Initially the right hand was numb and subsequently a year later, the left hand became numb. Physical examination was positive for Durkan, Phalen and Tinel signs at the carpal tunnel. Magnetic Resonance Imaging (MRI) showed abnormal muscle tissues in the carpal tunnel. During the carpal tunnel release and exploratory surgery, we noted an abnormally proximal origin of the lumbrical muscles in the forearm rather than the typical palmar origin. He also had lumbrical muscle hypertrophy in the left side. These two factors resulted in overcrowding within the carpal tunnel. Post-operatively the patient recovered well with pain relief and gradual improvement of his numbness. Variations in the anatomy of the lumbrical muscles is not uncommon and may result in carpal tunnel syndrome. Hence, carpal tunnel release surgeries may not be as straight forward as expected and surgeons should be aware of this possibility.

Keywords: anatomical, carpal tunnel syndrome, hypertrophy, lumbrical, median nerve, muscle, variations

INTRODUCTION

The occurrence of anomalous muscles in the region of the wrist is not uncommon but they are seldom associated with compression neuropathy. Anomalous proximal muscle origins or hypertrophy of the lumbrical muscles may limit space available for the median nerve within the carpal tunnel causing compressive neuropathy (Ragoonwansi et al. 2002).

Aberrant muscles in relation to the carpal tunnel have been previously described, some of which were directly implicated in median nerve compression resulting in carpal tunnel

syndrome (Cartwright et al. 2014). The majority of the muscle aberrations are from the first or second lumbricals, palmaris longus, flexor digitorum superficialis of the index finger and atypically, palmaris profundus muscles (Redondo et al. 2011).

The lumbrical muscles typically originate from the flexor tendons in the palm and insert into the extensor expansions. Variations are not uncommon and the present study depicts a case where the lumbricals originate much more proximally in the forearm. We report a patient with carpal tunnel syndrome (CTS) of both hands

resulting from an abnormal origin of the lumbrical muscles proximal to the carpal tunnel in the forearm arising from both flexor digitorum profundus (FDP) and superficialis (FDS) tendons. Additionally on the left side, there was hypertrophy of the lumbricals to the left ring finger.

CASE REPORT

A 73-year-old retired army veteran presented with numbness, pain, night pain and clumsiness on his right hand for past one year. There was thenar muscle atrophy and numbness over the median nerve area, together with soft tissue fullness proximal to the wrist crease. Numbness was aggravated by active flexion of his fingers. Tinel sign over the carpal tunnel area and Phalen test were positive.

Open carpal tunnel release was performed under general anesthesia in anticipation of exploratory surgery. Intraoperatively, the transverse carpal ligament had no overlying mass or fibrotic thickening. After incising

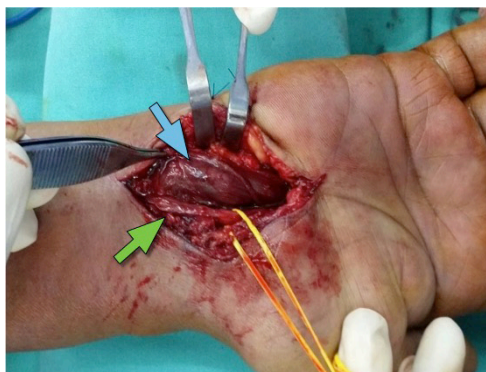

Figure 1: Hypertrophied first lumbrical muscle (blue arrow) and second lumbrical muscle (green arrow) compressing on the median nerve (deep to the lumbrical muscle).

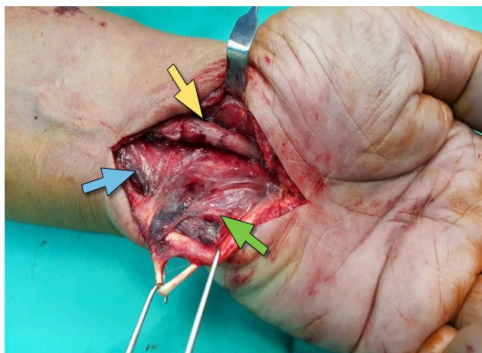


Figure 2: Note the abnormal lumbrical muscles (blue arrow) with abnormal proximal insertion to both the tendons of FDS and FDP (green arrow). The median nerve is marked with a yellow arrow.

the transverse carpal ligament, a hypertrophic muscle was found compressing on the median nerve. A gentle pull of this muscle confirmed its origin from the first and second lumbricals extending into the carpal tunnel attaching to the transverse carpal ligament as well as the FDP. Additionally, the second lumbrical was hypertrophic causing overcrowding in the carpal tunnel (Figure 1). Other structures in the carpal tunnel were normal. This anomalous muscle was later excised to reduce the compression to the median nerve. Symptoms were relieved post-operatively.

One year later, the patient presented with similar complaints and physical findings over his left hand. Magnetic Resonance Imaging (MRI) revealed abnormal muscle tissue within the carpal tunnel. The median nerve was compressed between the transverse carpal ligament and the anomalous muscle. An open carpal tunnel release was performed under general anesthesia. Hypertrophied lumbrical muscles were noted inside the carpal

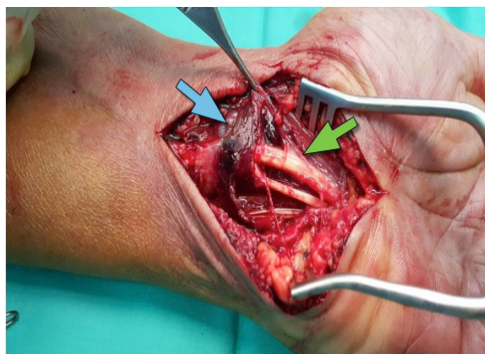


Figure 3: The abnormal lumbrical muscles (blue arrow) are being dissected from the tendons of the FDS and FDP (green arrow).

tunnel overcrowding the carpal tunnel (Figure 2), with an abnormal origin from the tendons of both FDP and FDS of ring finger, proximal to the wrist (Figure 3). No median nerve abnormality was noted. The abnormal lumbrical muscle belly was excised (Figure 3).

Post-operatively the patient was satisfied as his pain was relieved. On follow-up, he underwent physiotherapy and his symptoms of numbness gradually improved.

DISCUSSION

The median nerve course and its surrounding anatomical structures are vital while discussing on median nerve compression. The median nerve arises from the C5-T1 roots and enters the arm lateral to the brachial artery between biceps brachii and brachialis. It then crosses the artery descending medial to it before entering the cubital fossa. Once in the cubital fossa, it is medial to the brachial artery and enters between the two heads of pronator teres, deep to the bicipital aponeurosis but superficial to the brachialis.

Proximal median nerve compression can be due to pronator teres, lacertus fibrosus and tendinous origin of flexor digitorum superficialis. An anomalous third head of biceps brachii has been reported in a cadaveric dissection tightly encasing the median nerve and brachial artery restricting motion of the two structures (Zar Chi et al. 2017).

The median nerve then continues in the forearm passing between the flexor digitorum superficialis and and flexor digitorum profundus muscles before emerging between the flexor digitorum superficialis and flexor carpi radialis muscle just about 5cm proximal to the carpal tunnel. In the carpal tunnel, the median nerve shares an enclosed space with nine other structures namely the four FDS, four FDP and one flexor pollicis longus tendon. Hence, it is commonly compressed resulting in CTS.

There are four groups of median nerve variations i.e. I-the course of the thenar branches, II-accessory branches at the distal carpal tunnel, III-high division of the nerve including bifid median nerve and IV-accessory branches proximal to the carpal tunnel (Lanz 1977). In a bifid median nerve, an accessory muscle or a median artery may run in-between the division. The accessory muscles reported include the first lumbrical, palmaris longus, FDS muscle (Park et al. 2017; Atoni et al. 2017) and palmaris profundus. Presence of these anatomical variations are frequently associated with median nerve compression (Al-Qattan et al. 2009).

Lumbrical muscles are important for finger movements and is part of

the intrinsic muscles of the hand. They are different from other muscles as they connect muscle to muscle forming a connection from the digit flexors to the extensors. Usually, they originate from the FDP tendon, distal to the carpal tunnel, and the muscle belly moves proximally on finger flexion. It is common to encounter variations in lumbrical attachment. Few variations include originating from a metacarpal, from the forearm or from a superficial flexor tendon (instead of FDP). Additionally, the third and fourth lumbricals normally originate from two tendons but may originate from a single tendon (Mehta et al. 1961).

An additional muscle belly for the lumbrical muscle of the left ring finger was seen in our case where the hypertrophic muscle belly compressed the median nerve within the carpal tunnel. CTS can be caused by median nerve compression by anomalous and additional lumbrical muscles (Chaudruc et al. 2000). A similar observation was seen in a study showing a bipennate origin of the first lumbrical, extending from the distal part of forearm with a split insertion (Singh et al. 2001). Several other authors also reported that lumbrical muscle intrusion is a potential cause of CTS (Jabaley 1978; Joshi et al. 2005).

In our case, the lumbrical muscle of the left ring finger had a proximal origin in the carpal tunnel as well as in the forearm. Siegel et al. reported that those patients with idiopathic CTS had lumbrical muscle origins located significantly more proximally in the carpal tunnel. Additionally, the lumbrical muscles were larger and had

more proximal origins in those with jobs requiring repetitive hand motions (Siegel et al. 1995).

Other than the abnormal attachments, those with repetitive hand movements and those with CTS were reported to have significantly larger and hypertrophied lumbricals (Joshi et al. 2005). Shimizu et al. reported a case of CTS caused by a hypertrophied lumbrical muscle with flexor synovitis (Shimizu et al. 2015). Such hypertrophied muscle belly can cause overcrowding of the carpal tunnel as they glide proximally along with the flexor tendon during flexion of the fingers or when making a fist. Some reports suggest that it is not the existence of an anomalous muscle per se producing symptoms but hypertrophy due to manual work (Redondo et al. 2011; Ragoonwansi et al. 2002).

Operative treatment is preferred for CTS associated with lumbrical muscle anomaly rather than conservative management. Carpal tunnel release is usually performed, as well as resection of the abnormal muscle belly. It is preferably done under general anesthesia due to the larger surgical exposure. The prognosis is good after operative treatment once the abnormal muscle is resected as this prevents overcrowding of the carpal tunnel. It is best performed at an early stage before irreversible pathological changes occur on the median nerve.

CONCLUSION

Variations in the anatomy of the lumbrical muscles may produce

CTS. Surgeons performing carpal tunnel surgeries should have a sound knowledge of carpal tunnel anatomy and not consider them as simple straight forward operations.

REFERENCES

- Al-Qattan, M.M., Al-Zahrani, K., Al-Omawi, M. 2009. The bifid median nerve re-visited. *J Hand Surg* **34**: 212-4.
- Atoni, A.D., Oyinbo, C.A. 2017. Anatomic variation of the median nerve associated with an anomalous muscle of the forearm. *Folia Medica* **59**: 106-7.
- Cartwright, M.S., Walker, F.O., Newman, J.C. Arcury, T.A., Mora, D.C., Haiying, C., Quandt, S.A. 2014. Muscle intrusion as a potential cause of carpal tunnel syndrome. *Muscle Nerve* **50**(4): 517-22.
- Chaudruc, J.M., Florenza, F., Riviere, C., Arnaud, J.P. 2000. White finger and hypertrophy of the lumbrical muscles. *Chir Main* **19**(4): 232-4.
- Jabaley, M.E. 1978. Personal observations on the role of the lumbrical muscles in carpal tunnel syndrome. *J Hand Surg Am* **3**(1): 82-4.
- Joshi, S.D., Joshi, S.S., Athavale, S.A. 2005. Lumbrical muscles and carpal tunnel. *J Anat Soc India* **54**(1): 12-5.
- Lanz, U. 1977. Anatomical variations of the median nerve in the carpal tunnel. *J Hand Surg Am* **2**(1): 44-53
- Mehta, H.J., Gardner, W.U. 1961. A study of lumbrical muscles in the human hand. *Am J Anat* **109**: 227-38.
- Park, J.J, Choi, J.G., Son B.C. 2017. Carpal tunnel syndrome caused by bifid median nerve in association with anomalous course of the flexor digitorum superficialis muscle at the wrist. *Nerve* **3**(1): 21-3.
- Ragoonwansi, R., Adeniran, A., Moss, A.L. 2002. Anomalous muscle of the wrist. *Clinical Anat* **15**(5): 363-5.
- Redondo, M.G., Garcia-Guilarte, R.F., de Castro, A.B. 2011. Carpal tunnel syndrome caused by an anomalous muscle belly of the index finger lumbrical. *Eur J Plast Surg* **34**(1): 61-3.
- Shimizu, A., Ikeda, M., Kobayashi, Y., Saito, I., Mochida, J. 2015. Carpal tunnel syndrome with wrist trigger caused by hypertrophied lumbrical and tenosynovitis. *Case Rep Ortho* **2015**: 1-3.
- Siegel, D.B., Kuzma, G., Eakins, D. 1995. Anatomic investigation of the role of the lumbrical muscles in carpal tunnel syndrome. *J Hand Surg Am* **20**(5): 860-3.
- Singh, G., Bay, B.H., Yip, G.W., Tay, S. 2001. Lumbrical muscle with an additional origin in the forearm. *ANZ J Surg* **71**(5): 301-2.
- Zar Chi, T., Ahmad Ruzain, S., Mohammad Johari, I., Syed Baharom, S.A.F. 2017. Anomalous third head of biceps brachii muscle and its variant insertion compresses surrounding neurovascular structure: a rare case Report. *Med Health* **12**(2): 368-74

Received: 20 June 2018

Accepted: 28 Jan 2019