



### ACUTE AND SUBACUTE TOXICITY OF SIDDHA FORMULATION *DHATHU BHUSTI CHOORANAM*

**K. Thangadurai**

Associate Professor, Department of Pothu Maruthuvam, National Institute of Siddha, Tambaram Sanatorium, Chennai.

#### ABSTRACT

*Dhathu busti chooranam* (DBC) is a polyherbal formulation indicated in *Siddha* literature for the treatment of male infertility. The aim of this research was to evaluate the acute and sub-acute oral toxicity of the drug DBC. The acute toxicity test was conducted using albino rats of either sex. Water extract of DBC was administered in a single dose of 2000 mg/kg via oral gavage and the animals were observed for any behavioral changes or mortality. In the sub-acute toxicity study, male albino rats received two doses of DBC (200, 400mg/kg) for 28 days via oral gavage and the rats were observed for toxicity symptoms. Following the 28-day treatment, the rats were sacrificed for hematological, biochemical and histopathology studies. In the acute toxicity study, DBC was found to be non-toxic at a dose of 2000 mg/kg b.w with no signs of mortality. In the sub-acute toxicity study, there was no significant variations in body weight, hematological and biochemical parameters found in the experimental groups at the dose of 200 and 400 mg/kg. The tested dose in experimental rats is significantly higher than the human therapeutic dosage. The acute and subacute toxicity study results show that DBC may be a safe drug without causing any serious side effects.

**KEYWORDS:** *Siddha*, *Dhathu busti chooranam* (DBC), herbal medicine, Toxicity studies.

#### INTRODUCTION

Since ancient days, *Siddha* medicines have been largely used for the treatment of sexual disorders and infertility. The Siddhars, who were the saints of South India, had been enlightened about the nature, its association with human and its contribution to the physiological function of our body. That was why there was no complexity in producing their offspring. Many herbal and herbo mineral formulations that are indicated in *Siddha* texts has the promising effect to increase spermatogenesis, and give potent aphrodisiac action<sup>1,2</sup>. This study evaluates the acute and subacute toxicity of *Dhathu Busti Chooranam* (DBC).

#### MATERIALS AND METHODS

##### Preparation of *Dhathu busti chooranam*<sup>3</sup>

The ingredients are *Nilapanai Kizhangu* (*Curculigo orchoides*), *Boomi Sharkarai Kizhangu* (*Ipomoea mauritiana*), *Poonai Kali* (*Mucuna pruriens*), *Salamisri* (*Orchis latifolia*), *Thaner vitta kizhangu* (*Asparagus racemosus*).

##### Method of Preparation

These above mentioned drugs were taken 120 gms each and dried well. The dried pieces were finely powdered and then sieved by fine cotton cloth.

**Dose** : 2 gms twice a day before food.

**Adjuvant** : Cow's Milk.

**Indications** : Development and maturation of semen, strength and general vitality, impotence and nervine tonic.

##### Toxicity studies

The study was performed at Thanthai Periyar pharmacy College, Sundhar Nagar, Trichy, Tamil Nadu, during the year 2006-2007, after getting approval from Institutional Animal Ethical Committee (IAEC). The principles of laboratory animal care were also followed in

this study LD 50 of *Dhathu Busti Chooranam* was done as per OECD (Organization of economical Co-operation and Development).

##### Acute toxicity study<sup>4,5</sup>

Albino rats of either sex (wt. 150 – 180 g were used for acute toxicity studies) the animals were supplied by the Periyar animal facility centre. They were fed ad libitum with standard feed and had free access to water. They were also maintained under standard conditions of humidity, temperature and 12 hr. light / darkness cycle. The animals were acclimatized for a week before the commencement of the study.

##### Observation

In acute toxicity study, the control and 2000 mg/kg b.wt treated animals were observed for their behavioural signs and mortality for a period of 14 days.

##### Behavioural signs

All the experimental animals were observed for behavioural signs such as Piloerection, lacrimation, salivation, diarrhoea, gait, posture, dyspnoea, lethargy, tremors, convulsions, coma and death.

##### Sub acute toxicity study<sup>4,5</sup>

##### Selection of animals

Adult male albino rats of wistar stain 4-6 weeks, were obtained from Venkateshwara Agencies, Bangalore. The animals were housed in large spacious cages, maintained in controlled environment of temperature, humidity and light/dark cycles. They were fed with standard pelleted diet obtained from Hindustan lever limited, Bangalore and water ad libitum.

Fifteen albino rats weighing 100-250 gms were taken and divided into three groups. Groups I served as control. Group II received drug *Dhathu Boosti Chooranam* -

200 mg/kg per day and group III received drug *Dhathu Boosti Chooranam* - 400 mg/kg per day. This dose was given to animal for 28 days. Blood was drawn from the carotid artery and serum was separated for the different assays of AST, ALT, AKP, ALP, Bilirubin, Protein, Triglycerides, Total cholesterol and HDL. Organs, which were subjected to histopathological studies include kidney and liver. All the animals were sacrificed on the next day and the viscera were separated, grossly inspected and then subjected to histopathological studies.

Estimation of Aspartate Aminotransferase (AST), Alanine Aminotransferase (ALT), Alkaline Phosphatase (ALP), Cholesterol, Urea, Creatinine, Protein, Albumin and Globulin, Bilirubin was performed by using Reitman and Frankel method 1957, Kind & Armstrong method, 1934, ZAK B Method, 1977, DAM Method, Owen, JA, Steward Method, Lowry et al method - 1951, Biuret

method - Wolfson 1948 and Malloy HT and Evelyn method, 1937 respectively.

**Histopathological examination<sup>6</sup>**

The histopathological changes of the organs liver and kidney were observed macro and microscopically. Histological slides of organs were made and observed under the microscope for any changes. The pathological observations of these tissues were performed on gross and microscopic bases. Organs were processed to study histological changes adopting paraffin method.

**RESULTS AND DISCUSSION**

**Acute toxicity study**

The trial drug *Dhathu Busti Chooranam* did not exhibit any significant toxicity. The drug *Dhathu Busti Chooranam* falls under class 4. (LD<sub>50</sub> > 2000 mg/kg). The animals did not show any signs of acute toxicity and behavioural changes.

**Table 1: Acute toxicity study**

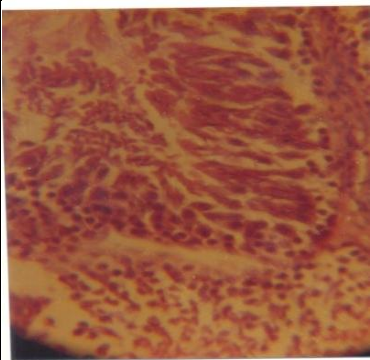
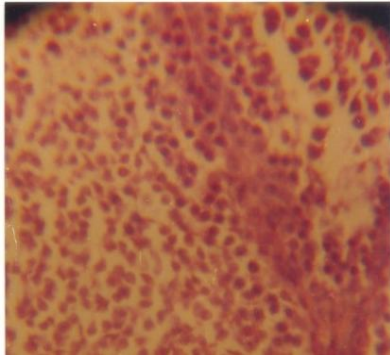
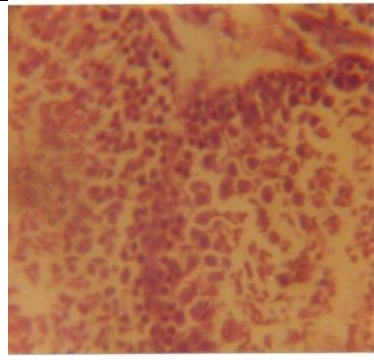
Treatment	Protein mg/dl	Urea mg/dl	TGL mg/dl	HDL mg/dl	LDL mg/dl	VLDL md/dl	Total Cholesterol
Control	1.93 ± 0.09	22.3±1.32	76.39±1.32	24.5±1.32	39.12±4.13	15.22±0.82	78.84 ±6.27
Group-I DBC-200 mg/kg	2.1 ±0.12	22.5 ±1.2	5.12± 3.96	31.3 ±2.1	43.64±0.58	15.86±1.12	90.8±3.80
Group-II DBC-400 mg/kg	2.8±0.08	22.8 ± 1.3	83.74±4.3	33.2 ± 2.9	34.16± 1.9	16.74 ± 1.2	84.1 ±5.13

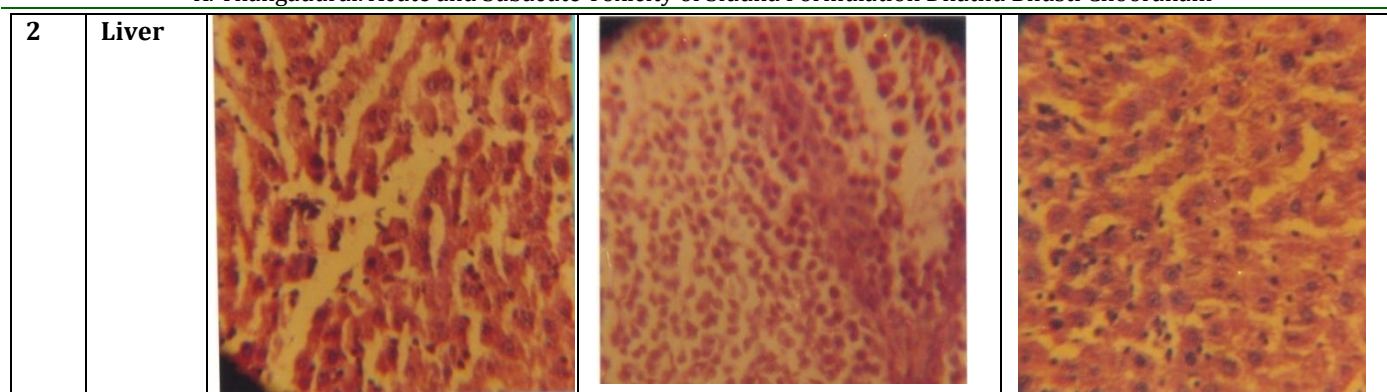
**Table2: Acute toxicity study**

Treatment	AST (U/I)	ALT (I/I)	ALP (U/L)	Bilirubin (mg/100 ml of blood)	
				Direct	Total
Control	37.8 ±1.8	55.88±8.2	17.83±0.81	0.098±0.02	0.153±0.03
Group-I DBC-200 mg/kg	40.2 ±2.2	59.8 ±3.53	21.8±1.8	0.11±0.015	0.23 ±0.22
Group-II DBC-400 mg/kg	43.9±2.1	63.8±3.9	23.6± 1.2	0.17±0.008	0.22±0.01

**Histopathology**

No significant changes in Kidney and liver tissue damages were observed against the control after 30 days treatment of *Dhathu Busti Chooranam* (200 mg/kg) and also at a higher dosage of *Dhathu Busti Chooranam* (400mg/kg). The degree of inflammation and histopathologic damage with reference to hepatocellular architecture, necrosis, inflammation, mononuclear cell infiltration, Kupffer cells presence, arrangement of sinusoids, vacuolization vascular congestion and renal architecture were observed carefully and the results showed normal hepatic and renal architectures with no significant changes(fig.1).

S.No	Section	Control	DBC-200mg	DBC-400mg
1	Kidney			

**Fig-1 Histopathology**

Though Herbal medicines are widely perceived by the public to be natural, safe and free from side effects, the above toxicity study was performed to scientifically claim the safety of the Herbal formulation DBC. The *Dhatu Busti Chooranam* was found to be safe in both the dose levels of 200 & 400 mg/kg as evidenced by the levels of different enzymes after treatment for 30 days. In the DCB treated rats (200 & 400 mg/kg), the levels of AST, ALT, ALP, Protein, Triglycerides, Total Cholesterol, LDL and VLDL were found to be within the normal physiological limits indicating its safety. The hepatic cell architecture and renal architecture doesn't show any severe damage. None of the dose levels showed any form of injury or fatty changes with treatment of *Dhatu Busti Chooranam* at 200 & 400 mg/kg. The renal tissues were absolutely free from any pathological changes due to *Dhatu Busti Chooranam* in chronic treatment.

**CONCLUSION**

Through this acute and sub acute toxicity study, the drug *Dhatu bhusti Chooranam* (DBC) a traditional Siddha herbal formulation was found to be safe on both doses of 200 & 400 mg/kg and the LD<sub>50</sub> was found to be higher than 2000 mg/kg.

**REFERENCES**

1. M.Shanmugavelan, *Noikalukku Siddha Parikaram*. Volume -2, Chennai; Department of Indian medicine and Homeopathy; 1976. p.166.
2. Murugesu Mudaliar KS. Mooligai vaguppu, *Gunapadam Part I*, Chennai; Department of Indian and Homeopathy; 1988. p. 439-706.
3. Thyagarajan.R. Gunapadam thathu seeva vaguppu, *Part II,III*. Chennai; Directorate of Indian Medicine Homeopathy; 2004. p. 687.
4. Ramaswamy et al. Acute toxicity and the 28-days repeated dose study of a Siddha medicine Nuna kadugu in rats, *BMC Complementary and Alternative Medicine*. 2012;12:190.
5. Muralidhara NK, Viswanatha S, Ramesh BS., Acute and subchronic toxic assessment of Debitterized Fenugreek powder in the mouse and rat. *Food and Chemical Toxicology*.1999;37: 831-838.
6. Arsad SS, Esa NM, Hamzah H. Histopathologic Changes in Liver and Kidney Tissues from Male Sprague Dawley Rats Treated with *Rhaphidophora Decursiva* (Roxb.).
7. Schott Extract..J Cytol Histol. 2014; S4: 001.

**Cite this article as:**

K. Thangadurai. Acute and Subacute Toxicity of Siddha Formulation Dhatu Bhusti Chooranam. *International Journal of Ayurveda and Pharma Research*. 2017;5(2):22-24.

**Source of support: Nil, Conflict of interest: None Declared**

**\*Address for correspondence**

**Dr K. Thangadurai**  
Associate professor  
National Institute of Siddha  
Tambaram, Sanatorium,  
Chennai, Pin-600047.  
Mobile: 09841023292  
Email: [drkthangadurai@gmail.com](mailto:drkthangadurai@gmail.com)