



## Research Article

### ROLE OF PROTECTION PROVIDED BY *EMBLICA OFFICINALIS* LINN. AGAINST RADIATION AND LEAD INDUCED HISTOLOGICAL CHANGES IN THE JEJUNUM OF SWISS ALBINO MICE

R.K. Purohit<sup>1\*</sup>, Aruna Chakrawarti<sup>2</sup>, Manisha Agarwal<sup>2</sup>, Ashok Jangir<sup>3</sup>, Purkha Ram<sup>3</sup>, Pyare Lal<sup>3</sup>, Kamal kumar Nayak<sup>3</sup>

\*<sup>1</sup>Professor, <sup>2</sup>Lecturer, <sup>3</sup>Ph.D. scholar, Radiation Biology Laboratory, Department of Zoology, Govt. Dungar College, Bikaner, Rajasthan, India.

#### ABSTRACT

Exposure to ionizing radiation increases the production of the reactive oxygen species (ROS) leading the irradiated cells into a state of oxidative stress. Furthermore, Lead exposure along with ionizing radiation can potentially become toxic to the tissues due to the heightened oxidative stress. In the present study adult male Swiss albino mice were procured and divided into seven groups. Group (II to IV) serving as control, received sub lethal dose (3.0 Gy or 6.0Gy) and /or lead acetate (20ppm) in drinking water *ad libitum*. The experimental groups (V to VII) were given aqueous solution of *Emblica* (1000 mg/ Kg b.wt./ animal/ day) orally seven days prior to radiation and/or lead acetate treatment. Sham- irradiated animals of Group I served as normal. Animals of all the groups were autopsied at each post treatment interval of 1, 2, 4, 7, 14 and 28 days. After the experiments observed number of lesions in the intestinal epithelium from outer coat to inner mucosa. Loosened sub mucosa with hyperaemia and hemorrhage, shortened crypts and a number of apoptotic cells with severe cytoplasmic variations were noted. Villi had a rough surface, wavy epithelium and hydropic degeneration up to day-2 and thereafter, a recovery from intestinal lesions was initiated and noticed till the last autopsy interval. After the combined exposure of gamma radiation and lead acetate, Group IV exhibited same pattern of damage but severe histopathological alteration than individual exposure of radiation or lead acetate indicating "synergistic" effect. Process of recovery started on day-14 after the combined treatment but the process was slow. The Combined treatment showed synergistic effect. In experimental groups less severe radiolesions and an early onset of recovery was observed. Therefore it may be deduced that *Emblica* is a good herbal radioprotector and may be useful for the clinical applications in human beings during radiotherapy.

**KEYWORDS:** *Emblica Officinalis* Linn., Radiation and Lead Induced Histological Changes, Jejunum of Swiss Albino Mice.

#### INTRODUCTION

Radioactive materials that decay spontaneously produce ionizing radiation, which has sufficient energy to strip away electron, from atoms (creating two charged ions) or to break some chemical bonds. Any living tissue in the human body can be damaged by ionizing radiation in a unique manner. The body attempt to repair the damage, but sometimes the damage is of a nature that cannot be repaired or it is too severe or widespread to be repaired. Also mistakes made in the natural repair process can lead to cancerous cells. The exposure of mammals to ionizing radiation such as gamma radiation can cause the development of a complex dose dependant series of potentially fatal physiological and morphological changes. Oxidative stress contributes to normal tissue damage during tumor therapy with radiation [1]. The most common forms of ionizing radiation are alpha and beta particles or gamma and x-rays. In general, the

amount and duration of radiation exposure affects the severity or type of health effect.

Intestine is the most sensitive tissue in the gastrointestinal tract mainly because its cell population in the villi is dynamic and under normal condition it is in a steady state. The cells are produced in the crypts, migrate up in the villi, and are finally sloughed off from the tips off villi, the immature cells and cells in active division are especially sensitive to irradiation. It is their presence is plenty in the intestine, which makes it relatively more radiosensitive. The intestinal epithelium is a cell renewal system, consisting of cells with different sensitivity. Crypts have been reported to be more vulnerable than the vilus epithelium. The extensive cell loss in the intestinal crypts after irradiation is responsible for morphological, biochemical and functional changes[2].

Heavy metals were considered to pose major health problems only to workers involved in mining and processing of ores and in industries using metals.

Lead is a multiple source pollutant, well known for its toxicity, of great risk both for the environment and human health. Toxic effects caused by lead exposure are usually detected in the kidney, nervous, hematopoietic and gastrointestinal systems. Several studies have shown that maternal exposure to lead is highly responsible for miscarriages and birth defects in the fetuses and also has adverse effects on the cognitive development of children [3].

The metallic toxicants and radiations when administered simultaneously may prove the more disastrous to living beings. To understand the effect of lead and radiations, intestine study can provide vulnerable information.

*Emblica* is a natural, efficacious, antioxidant with the richest natural source of vitamin- C. Ayurveda describes it as one of the best herbs for diabetes, bleeding disorders, strength and stamina promoter [4]. Polyphenol compounds that act as antioxidant are found abundantly in plants. They exert profound chemo-radio preventive activities due to their ability to scavenge and reduce the production of free radicals and act as transition metal inhibitors, DNA cleavage protector [5].

The present study was focused on the protection and modulation provided by the *Emblica* against radiation and lead induced changes in jejunum.

The changes were more severe in the combined treatment groups showing synergistic effects. An early and fast recovery was noted in the drug treated groups showing protection provided by *Emblica*.

## MATERIALS AND METHODS

### Procurement of animals and their maintenance

In the present study, adult healthy male Swiss albino mice (6-8 weeks old) were purchased from Lala Lajpat Rai University of Veterinary and Animal Sciences, Hissar (India). The animals were housed in cages under good ventilation and illumination condition. They were fed with standard mice feed and water was given ad libitum. The temperature of the room was maintained between 22-27°C. The Govt. Dungar College, Bikaner is registered under CPSCEA, Chennai (Registration no. 1066/ac/07/CPCSEA) and has its own Institutional Animal Ethics Committee (IAEC). All the experiments conducted in the present investigation were performed strictly under the supervision of IAEC of the college.

**Lead:** Lead salt in the form of Lead acetate was procured from Ranbaxy Laboratories Ltd. Lead acetate was given in the drinking water at the dose of 20 ppm<sup>[6]</sup>.

***Emblica* [EOE]:** Fresh fruits of the *Emblica officinalis* were cleaned, cut into small pieces, air dried, powdered and extracted with double distilled water (DDW) by refluxing for 36 hrs. (12 hrs.x 3). The extract thus obtained was vacuum evaporated so as to make it in powdered form. The extract was redissolved in DDW just before oral administration. An approximate thirty eight per cent yield of the extract is obtained. The EOE was given from seven days prior to Lead acetate treatment or irradiation in all the experimental groups<sup>[7]</sup>.

**Source and procedure of irradiation:** Cobalt-60 gamma radiotherapy source (Theratron) of AECL make, obtained from Canada was used to expose the animals. This facility was provided by the Radiotherapy Department of Prince Bijay Singh Memorial Hospital, Bikaner (Rajasthan). The animals were irradiated at the dose rate of 0.69 Gy/min during first year and 1.22Gy/min during the subsequent year.

**Experimental Design:** In the present study, the animals were grouped as under Group I: (Sham-irradiated animal-normal)

**Group II:** (Lead Acetate treated animals)

**Group III:** (Only irradiated animals)

Sub-group IIIa: 3.0 Gy

Sub-group IIIb: 6.0 Gy

**Group IV:** (Animals treated with radiation and lead acetate)

Sub-group IVa: 3.0 Gy + Lead acetate

Sub-group IVb: 6.0 Gy + Lead acetate

**Group V:** (Animals treated with Lead Acetate and *Emblica*)

**Group VI:** (Animals treated with radiation and *Emblica*)

Sub-group VIa: 3.0 Gy + *Emblica*

Sub-group VIb: 6.0 Gy + *Emblica*

**Group VII:** (Animals treated with radiation, Lead acetate and *Emblica*)

Sub-group VIIa: 3.0Gy + Lead Acetate + *Emblica*

Sub-group VIIb: 6.0Gy + Lead Acetate + *Emblica*

Histological studies, the pieces of intestine were fixed in Bouin's fluid for 24 hours and after routine procedure, 5µ thick sections were cut and stained with Harris haematoxylin and eosin. To count the number of goblet cells, some slides were stained by PAS haematoxylin method. Qualitative and quantitative parameters were taken to assess the changes in crypts and villi.

## RESULTS AND DISCUSSION

Exposure to 6.0 Gy gamma radiations to animals resulted in radiation sickness within 3-5 days

after exposure. The symptom included reduction in the food and water intake, weight loss, diarrhea, ruffling of hairs and irritability [8].

Because of the anatomic location, the small intestine often receives injurious doses of ionizing radiation even though it rarely needs therapeutic radiation itself. It has generally been claimed that intestine constitute the most radio sensitive tissue in the gastrointestinal tract. A number of active chemicals have been found to reduce the intensity of radiation injury when administered before exposure. Environmental toxins are chemicals and other materials created largely from industry and carelessness. While a very large number of environmental toxicants are potentially harmful to health, the most commonly studied ones can be divided into three major categories heavy metals, air pollutants and pesticides. Environmental toxins that are internalized by skin absorption or by inhalation may be secreted into the lumen through the biliary system and lead to toxicity. Toxins suspended in air make their way into the intestinal tract by drainage from the sinuses into the pharynx and oesophagus. Exposure to chemical agents at critical periods of development may cause some permanent change in the histology and physiology of various organ systems in organism [9].

Radio sensitivity of jejunum is due to its very high physiological activity and abundance of immature and actively dividing cells in it [10]. Jejunal epithelium is one of the cell renewal systems. The integrity of cell renewal system depends upon a balanced sequence of proliferation and differentiation that leads ultimately to the production of functional cells. Cell renewal system is readily perturbed by ionizing radiation [11]. There is no doubt that the significant increase in survival in *Emblica* treated mice could be due to the antioxidant property, as evidenced by the restoration of glutathione and LPO levels [12].

## HISTOLOGICAL STUDIES

### QUALITATIVE STUDIES

In the present investigation, important radio lesions seen in non-drug treated groups II, III and IV are looseness of musculature, hydropic degeneration, hyperaemia and hemorrhage in submucosa, pyknotic nuclei, necrotic cells, cytoplasmic degranulation, vacuolation and abnormal mitotic figures in crypts. Karyorrhexis, karyolysis and chromatolysis are also observed in crypt cells at higher dose (6.0 Gy). Shortening and breaking of villi, hydropic degeneration and leucocytic infiltration in lamina propria, cell debris in intestinal lumen are also observed (Figs. 1-4). These changes were qualitatively similar in the entire dose groups but severity increased with dose. These radiation-induced changes in small intestine are in conformation with earlier reports [13]. In the *Emblica* treated groups V, VI and VII the changes were of lesser magnitude and early recovery was also observed.

It was revealed that nuclear changes in the basal cells of crypts of Lieberkuhn of duodenum and jejunum after two hours of exposure were more extensive [14]. The injury in mice exposed to 1000 R total body X- irradiation has also been reported and it was concluded that the intestinal crypt epithelium was quite radiosensitive [15].

The hypersensitivity of intestinal crypts demonstrated in the present investigation is in accordance with the law given earlier [16]. Intestinal crypts have immature and dividing cells and, therefore, this region is most radiosensitive. The necrotic cells in intestinal epithelium 12 hours after irradiation; the villi with ruptured tips and lumen contained exudates from villi, at 24 hours were also noticed. There was marked hydropic degeneration in villi, reduced crypt cell population and necrotic cells in crypts. The radio lesions in the form of disarrangement of cells in the intestinal mucosa and appearance of dead cells at the base of villus folds, hydropic degeneration in lamina propria, muscular coat and sub mucosa appeared oedematous in the small intestine of *Uromastix* have also been reported [17-18].

The decline in the number of crypt cells was due to sharp diminution of mitotic activity in the crypts. After exposure to ionizing radiation, rapidly replicating crypt transit cells either undergo apoptosis or cease replication [19].

Various stages of collapse of villus structure after radiation including the production of conical and rudimentary villi and a flattened mucosa have been reported [20]. The extensive histological changes in the crypts were also noticed by some workers. They reported pyknotic nuclei, necrotic cells, abnormal mitoses, cytoplasmic degranulation, karyorrhexis and distorted arrangement of cells after exposure to 10 Gy of gamma rays. These changes became more pronounced after 15 Gy exposures. They also reported severe injury in villi with extensive cell loss and stunted and ruptured tips. Decrease in the intake of food along with impairment of digestion was also observed [21].

It has also been stated that villus height was found to be reduced from 24 hours and maximum reduction was noted on day-3 after exposure of gamma rays. Loss of epithelial cells from the villi is the basic reason of reduction in height [22].

It has been suggested [23] that gastrointestinal syndrome and lesions in intestinal epithelium depends on the various factors like animal species, quality, dose and dose rate of radiation etc. Radiation induced gastrointestinal toxicity is due in part to the killing of the clonogenic crypt cells and eventual depopulation of villi was also reported [24].

The changes in the number of villus enterocytes, goblet cells, lamina propria cells and mitotic figures have also been observed. It was reported that programmed cell death is the prominent

mechanism in radiation induced cell damage to intestinal mucosa [25-26].

In present investigation, Group II showed various histological changes in the jejunum of Swiss albino mice. These changes are loosened musculature, hydropic degeneration in submucosa and lamina propria, cytoplasmic degranulation and vacuolation, abnormal mitoses, pyknotic nuclei and necrotic cells in crypt, loosened and broken tips of villi, shortened villi and leucocytic infiltration in lamina propria (Fig. 5-8).

After the treatment of another heavy metal (Methyl mercury) also (5.0 mg/kg body weight). A number of lesions in the intestinal epithelium from outer coat to inner mucosa were noted. Loosened submucosa with hyperaemia and hemorrhage, shortened crypts and a number of apoptotic cells with severe cytoplasmic variations were noted. Villi had a rough surface, wavy epithelium and hydropic degeneration up to day-2 and thereafter, a recovery from intestinal lesions was initiated and noticed till the last autopsy interval (Figs. 9-10).

After the combined exposure of gamma radiation and lead acetate, Group IV exhibited same pattern of damage but severe histopathological alteration than individual exposure of radiation or lead acetate indicating "synergistic" effect. Process of recovery started on day-14 after the combined treatment but the process was slow. The present observation finds support from the findings of previous workers who also observed drastic qualitative alterations after the combined treatment of methyl mercuric chloride (MMC) and radiation. The separation of submucosa and muscularis mucosa, thickening in the blood vessels, haemorrhage, shortened crypts and cytoplasmic degranulation with increased apoptotic cells were observed. The villi were also affected to a greater extent in the combined treatment as these had ruptured, stunted and denuded epithelial surface. The maximum severity of cytolesions was observed in MMC+3.60Gy<sup>[27]</sup>.

In the present investigation, *Emblica* treated groups V, VI and VII exhibited less severe radio lesions and early recovery as compared to non-drug treated groups II, III and IV showing protection provided by *Emblica*. This is in concur with earlier studies that reduction in the total cell population of the crypt is due to an early and marked decline in DNA synthesis in the crypt cells, cell death and movement of cells up to villus in the absence of replacement by cellular proliferations [28].

#### Protective mechanism of *Emblica officinalis*

The possible mechanisms of action of *Emblica* may be as under:

(1) Radiation has been shown to induce DNA strand breaks and mutation and induced peroxidative changes to lipid and proteins. *Emblica* extracts has

been shown to have significant antioxidant activity, which reduces the oxidative changes induced by radiation.

- (2) *Emblica* extract was also found to inhibit mutagenesis by direct binding to certain mutagens as well as by inhibiting carcinogen activation.
- (3) It stimulates haemopoiesis thus reducing the myelo suppression induced by radiation.
- (4) Moreover, it produces a protective layer in stomach thus reduces the mucosal damage of gastrointestinal linings during irradiation.
- (5) Presence of a variety of polyphenols are reported in *Emblica*. These polyphenols are excellent scavengers of oxygen radicals produced in the body by radiation, thus affording protection to the body [29].
- (6) The protection afforded by *E. officinalis* may be associated with its antioxidant capacity and through its modulatory effect on hepatic activation and detoxifying enzymes [30].
- (7) Administration of *Emblica* extract increased the GSH levels. *Emblica* showed excellent antioxidant activity in vitro and present study also revealed its antioxidant potential [31].
- (8) It can be hypothesized that antioxidant activity, potent stimulation of haemopoietic system, non toxicity as well as the easy availability of *Emblica* make it as an excellent choice for further development as a natural radioprotector.
- (9) In conclusion owing to the properties the *Emblica* extract known for its functional properties can be further extended to exploit its possible application for various health benefits as nutraceuticals and food ingredient in radiotherapy to protect the normal tissue.

#### CONCLUSION

In previous studies, the miracle *Emblica* extract was found quietly healing radiation wounds in jejunum effectively as antioxidant because it is rich vitamin C and glutathione peroxidase, it scavenges free radicals. *Emblica* have clinically proved medicinal properties, which enhanced the activity of various antioxidant enzymes and GST as well as glutathione system. The data clearly indicates that the extract significantly reduced the bio effects of radiation, *Emblica* may be useful in reducing the side effects produced during therapeutic radiation.

#### REFERENCES

1. Singariya, S., Songara, V., Agarwal, M., Chakrawarti, A. and Purohit, R.K., Radioprotective potential of *Aloe vera* against radiation and cadmium mediated alterations in differential leucocyte counts in Swiss albino mice. Int. J. Adv. Res., 3 (7): 1293-1593 (2015).

2. Pyarelal, Role of protection provided by *Emblica officinalis* Linn. against radiation and lead induced changes in the jejunum of Swiss albino mice. A Ph.D. thesis submitted to M.G.S.University, Bikaner (2015).
3. Songara, V., Singariya, S., Agarwal, M., Chakrawarti, A. and Purohit, R.K., Effect of gamma radiation and lead on total erythrocyte count and hemoglobin of mice and its modification by *Emblica officinalis* Linn., *WJPR*, 4(8):2104-2118, (2015).
4. Kumar, A., Singh, A. and Singh, B., Assessment of therapeutic potential of *Phyllanthus emblica* (Amla): A natural Godsend., *Int. J. Cell Sci. Biotech.*, 3: 4-14(2014).
5. Bhati, S.L., Ranga, D., Meena, D.C., Agarwal, M., Chakrawarti, A. and Purohit, R.K., Ameliorative effect of *Emblica officinalis* in radiation and cadmium induced alteration in mice liver. *WJPR*, 3(10):846-863 (2014).
6. Agarwal, M., Songara, V., Singariya, S., Purohit, R.K., and Chakrawarti, A., Protective role of *Emblica officinalis* Linn. against radiation and lead induced haematological changes in swiss albino mice. *IJCPR*, 5 (4):77-82 (2013).
7. Bhati, S.L., Agarwarl, M. Chakrawarti, A. and Purohit, R.K., Modulation of radiation and cadmium induced changes in the hepatic nucleic acid content of mice by *Emblica officinalis* (Amla). *Int.J. Sci. Eng.Res.*, 6(7), 1475-1484 (2015).
8. Jagetia, G.S., Jagetia, G.S. and Baliga, M.S., The effect of seasonal variation on the antineoplastic activity of *Alstonia scholaris* R. Br. In *Hela Cells.*, *J Ethanopharmacol*, 96: 37-42 (2005).
9. Sharma, R. and Mogra, S., Effects of gestational exposure to lead acetate on implantation and neonatal mice. *J. of Cell and Mol. Biol.*, 11 (1 & 2): 47-58 (2013).
10. Bloom, W, *Histopathology of irradiation from external and internal sources.* National Nuclear Energy Series, Div. IV, Vol. 221, McGraw Hill Book Co., N.Y. (1948).
11. Patts, H.M. and Quastler, H. (1963): Radiation effect on cell renewal and related systems. *Physiol. Rev.*, 43: 357 (1963).
12. Chakrawarti, A., Purohit, R.K., Agarwal, M., Joshi, P., Basu, A, Bhartiya, K.M. and Bhardwaj, A., Modulation of radiation and cadmium induced biochemical changes in mouse kidney by *Emblica officinalis* Linn. *Iran. J. Radiat. Res.*8(1): 3-10 (2010).
13. Bisht, K.S., Prabhu, S., Umadevi, P. Modification of radiation induced damage in mouse intestine by WR- 2721. *Indian J Exp Biol*, 38: 669-674 (2000).
14. Warren, S. L. and Whipple, G. H., Roentgeno therapy in man in the light of experiments showing sensitivity of intestinal epithelium. *J. Am. Med. Assoc.*, 81: 1673 (1923).
15. Barrow, J. and Tullis, J. L., Sequence of cellular response to injury in mice exposed to 1000 r total body X-radiation. *A. M. A. Arch. Pathol.*, 53: 391 (1952).
16. Bergonie, J. and Tribondeau, L. Interpretation de quelques resultates de la radiotherapie at essai de fixation d'ume technique retionelle. *Compt.Rene.Acad.Sci. Paris*, 143: 983 (1906).
17. Umadevi, P., Saini, M. R., Verma, A. and Saharan, B. R., Radio-protective effect of 2-MPG on the small intestine of Swiss albino mice. *Ind. J. Exptl. Biol.*, 16: 86 (1978).
18. Gupta, M.L. and Umadevi, P., The effect of gamma irradiation on the small intestine of *Uromastix*. *Proc. Natl. Academy of sciences, India. Golden Jubilee session, Allahabad* (1980).
19. Vidrich, A., Buzan J.M., Barnes, S., Reuter, B., Skaar, K., Iio, C., Caminelli, F., Pizarro, T. and Chon, S.M., Altered epithelial cell lineage allocation and global expansion of the crypt epithelial stem cell population are associated with ileitis in SAMP1 YitFc mice. *American J Pathol*, 166: 1055- 1067 (2005).
20. Carr, K. E. Hamlet, Nias, A. H. and Watt, C., Damage to the surface of the small intestinal villus: an objective scale of assessment of the effects of single and fractionated radiation doses. *Brit. J. Radiol.*, 56: 467 (1983).
21. Veena, K. and Umadevi, P., Modification of radio-response of sub-lethally irradiated mouse jejunum by misonidazole. *Acta Oncol.*, 31: 585 (1992).
22. Gehlot, P. and Goyal, P.K., Evaluation of radioprotective efficacy of *Aloe vera* leaf extract in mouse intestinal mucosa after low level exposure to gamma radiation. *J Enviorn & Sociobiol*, 3: 93-100 (2006).
23. Osborne, J. W., Early and late radiation effects (external irradiation) on the gut. In "Radiation and Gut" (Eds.) C.S. Potten and J.H.Hendy Manchester, U.K. pp 145 (1995).
24. Khan, W. B., Shui, C., Ning, S. and Knox, S. J., Enhancement of murine intestinal stem cell survival after irradiation by keratinocyte growth factor. *Radiat. Res.*, 148: 248 (1997).
25. Brennan, P. C., Carr, K. E., Seed, T. and McCullough, J. S., Acute and protracted radiation effects on small intestinal morphological parameters. *Int. J. Radiat. Biol.*, 73: 691 (1998).
26. Mylonas, P. G., Matsouka, P. T., Papandoniou, E. V., Vagianos, C., Kalfarentzos, F. and Alexandrides, T. K., Growth hormone and insulin-like growth factor I protect intestinal cells from radiation induced apoptosis. *Mol. Cell Endocrinol.*, 160: 115 (2000).
27. Saxena, A., Entero-hepatic response against the combined effect of mercury and radiation in mice and its modification by Liv.52. Ph.D. Thesis, University of Rajasthan, Jaipur (1997).
28. Gehlot, P. and Goyal, P.K., Rectification of radiation-induced damage in swiss albino mice by *aloe vera*

- leaf extracts (AVE). Iran. J. Radiat. Res., 5 (2): 71-78 (2007).
29. Zhang, Y., Abe, T., Uang, C. and Kouno, I., Phyllanemblinins A-F, New ellagitannins from Phyllanthus emblica. J.Nat. Prod. 64: 1527-153 (2001).
30. Banu, S.M., Selvendiran, K., Singh, J.P. and Sakthisekaran, D., Protective effect of Emblica officinalis ethanolic extract against 7, 12 dimethylbenz (a) anthracene (DMBA) induced genotoxicity in Swiss albino mice, Hum Exp Toxicol., Vol 23, pp 527-31(2004).
31. Jeena, K.J. and Kuttan, R., Antioxidant activity of Emblica officinalis. J.Clin. Biochem, Nutri, 19: 63-70 (1995).

**Cite this article as:**

R.K. Purohit, Aruna Chakrawarti, Manisha Agarwal, Ashok Jangir, Purkha Ram, Pyare Lal, Kamal kumar Nayak. Role of Protection Provided by Emblica Officinalis Linn. Against Radiation and Lead Induced Histological Changes in the Jejunum of Swiss Albino Mice. International Journal of Ayurveda and Pharma Research. 2015;3(11):1-7.

**Source of support: Nil, Conflict of interest: None Declared**

**\*Address for correspondence**

**Dr. R.K. Purohit**

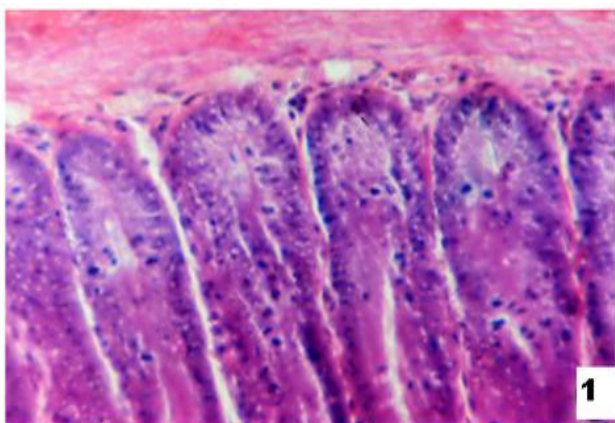
Professor, Radiation Biology Laboratory, Department of Zoology, Govt. Dungar College, Bikaner, Rajasthan, India.

Email:

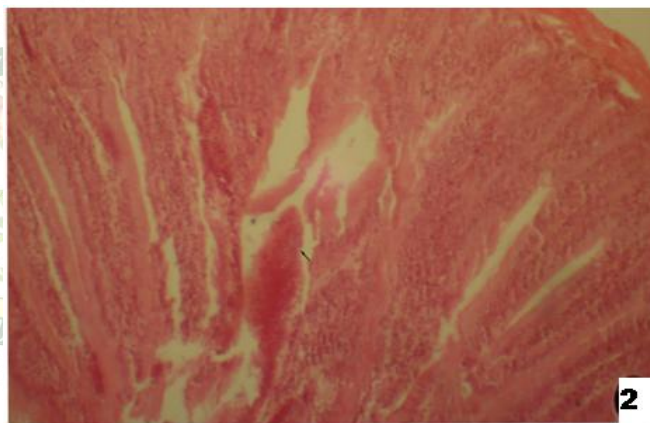
[dr\\_rajendra\\_purohit@yahoo.co.in](mailto:dr_rajendra_purohit@yahoo.co.in)

Mobile: 09413939790

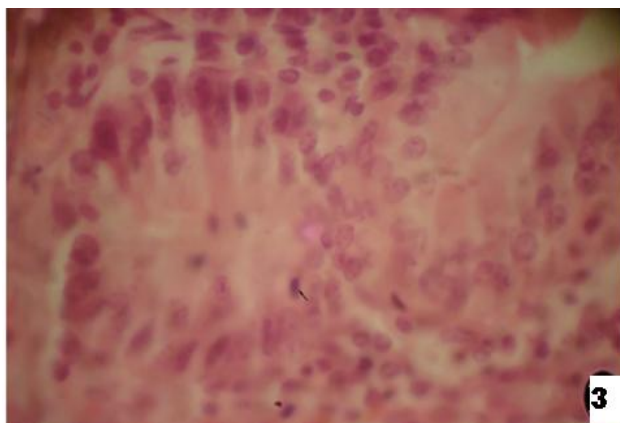
**Study Photographs**



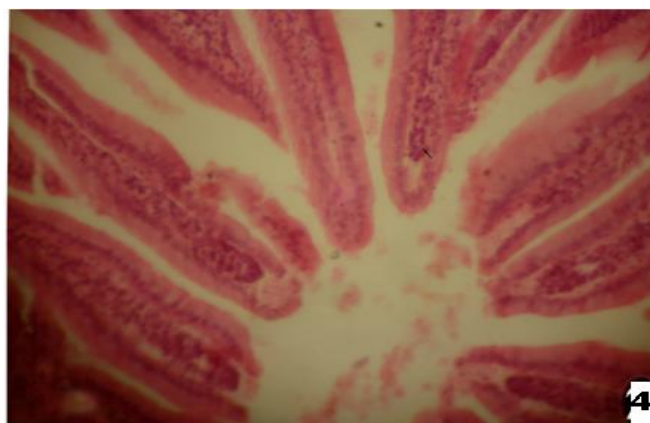
**Figure 1: Sham-irradiated group showing normal structure**



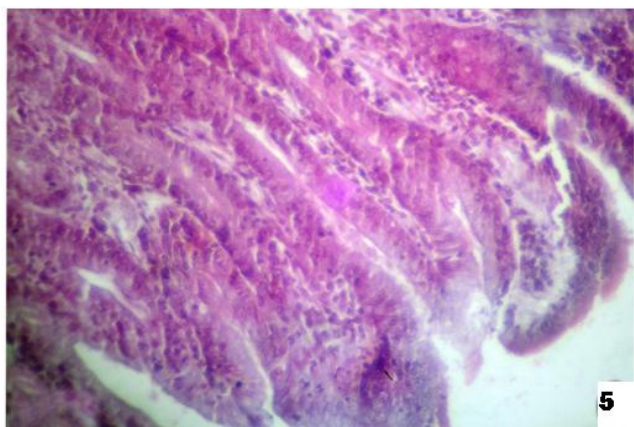
**Figure 2: After 14-days of gamma rays exposure showing better organized crypts cells with mitotic figures and necrotic cells**



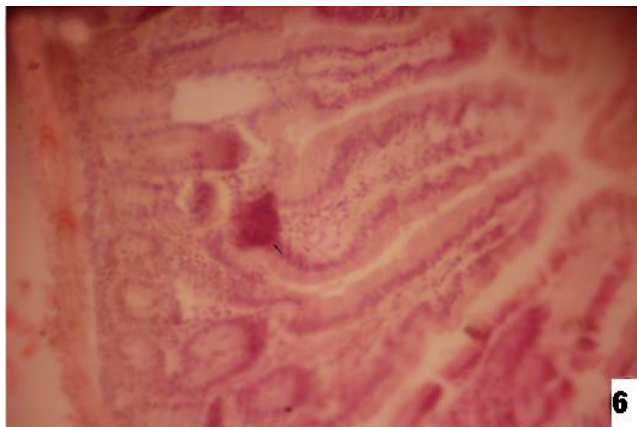
**Figure 3: After 1-days of gamma ray exposure (6.0 Gy) showing abnormal mitoses, cytoplasmic degranulation and vacuolation.**



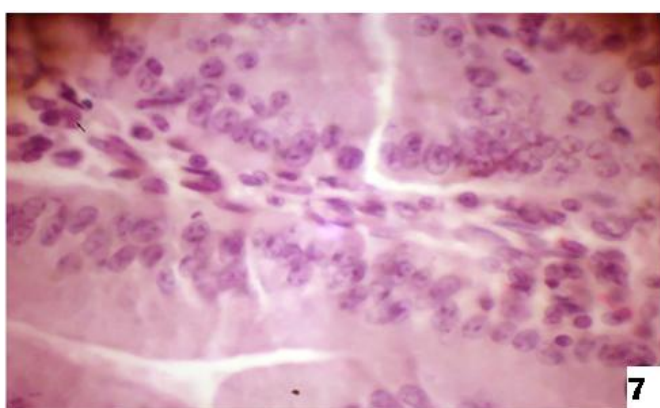
**Figure 4: After 4-days (6.0Gy+lead acetate) showing increased number of pycnotic nuclei and disarrangement of cells. Broken villi tips are also visible**



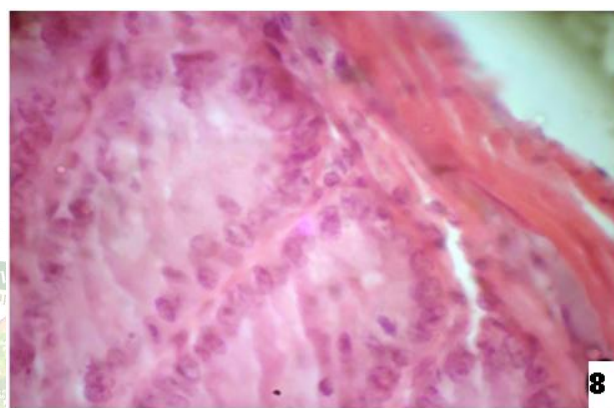
**Figure 5:** After 14-days of gamma rays exposure showing better organized crypts cells with mitotic figures and necrotic cells



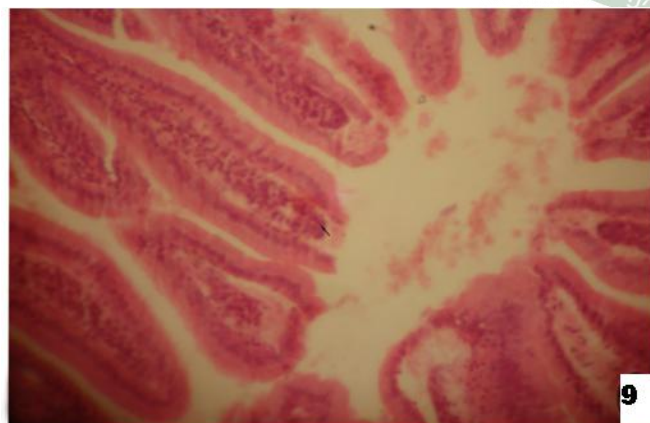
**Figure 6:** After 2-days (3.0 Gy + *Emblica*) depicting disarrangement of cells. Cytoplasmic degranulation and vacuolation are also seen



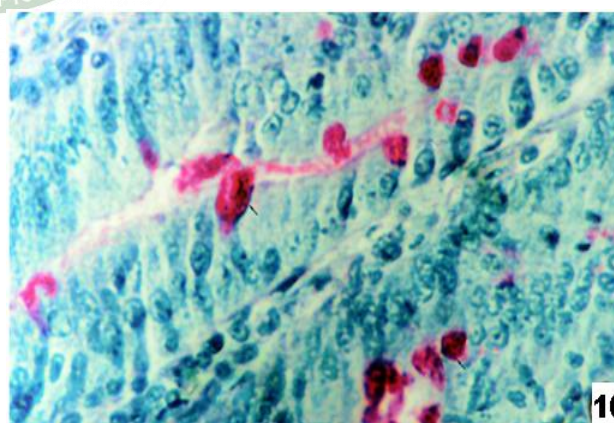
**Figure 7:** After 28-days (3.0 Gy+ *Emblica*) illustrating progressive recovery. Mild cytoplasmic degranulation and increased no. of mitotic figures.



**Figure 8:** After 2-days (6.0 Gy+ *Emblica*) showing loosened submucosa and hydropic degeneration in sub mucosa



**Figure 9:** After 4-days (6.0 Gy + Lead acetate + *Emblica*) showing displaying cellular necrosis and pycnotic nuclei. Broken villi tips are also seen



**Figure 10:** After 7 days (6.0 Gy) showing displaying decreased number of goblet cells in both crypts and villi