



Unprotected autogenous bone block grafts in the anterior maxilla: resorption rates and clinical outcomes

Nezaštićeni koštani autotransplantati u prednjem segmentu gornje vilice: stepen resorpcije i klinički rezultati

Ivan Kosanić*, Miroslav Andrić*, Božidar Brković*, Vladimir Koković†, Milan Jurišić*

*Clinic of Oral Surgery, Faculty of Dental Medicine, University of Belgrade, Belgrade, Serbia; †Ras Al Khaimah College of Dental Sciences, Ras Al Khaimah, United Arab Emirates

Abstract

Background/Aim. The use of autogenous bone grafts for augmentation of the resorbed alveolar ridge is still considered the gold standard in implant dentistry. The aim of this study was to analyze the resorption rate of autogenous bone block grafts from the retromolar region placed in the frontal segment of the upper jaw unprotected by barrier membranes, to assess the stability of implants placed into the grafted bone, as well as to monitor its changes during the healing period. **Methods.** The study included 18 patients with a total of 20 grafted sites. The residual alveolar ridge was measured before and after the augmentation and prior to implant placement. All implants were restored with provisional crowns within 48 hours after the placement. Implant stability was assessed using resonance frequency analysis. **Results.** The average period from ridge augmentation to reentry was 5.4 months (range 4–6 months). At reentry the healed alveolar ridge had a mean width of 6.1 ± 1.27 mm. The mean calculated width gain was 3.04 ± 1.22 mm. The overall surface resorption of block grafts was 0.68 ± 0.69 mm (18.85%). At the time of implant placement the mean value of implant stability quotient (ISQ) was 71.25 ± 5.77 . The lowest ISQ values were noted after three weeks of healing, followed by a gradual increase until week 12. After 12 weeks implants showed significantly higher ISQ values compared to primary stability ($p < 0.05$ Wilcoxon signed ranks test). During the 3-years follow-up period no cases of implant loss were recorded. **Conclusion.** Despite a significant resorption of bone grafts, it was possible to place implants in all the cases and to use the immediate loading protocol without affecting implant survival rate.

Key words:

maxilla; alveolar ridge augmentation; transplantation, autologous; dental implants; bone resorption; treatment outcome.

Apstrakt

Uvod/cilj. Primena autogenih koštanih graftova (implantata) za uvećavanje smanjenog (resorbovanog) alveolarnog grebena još uvek se smatra zlatnim standardom u implantologiji. Cilj ove studije bio je analiza stepena resorpcije autogenih koštanih blok transplantata nezaštićenih barijernim mebranama, uzetih iz retromolarnog predela mandibule i postavljenih u frontalni segment gornje vilice, procena stabilnosti implantata ugrađenih u povećanu regiju, kao i praćenje promene implantne stabilnosti tokom perioda oseointegracije. **Metode.** U studiju je bilo uključeno 18 pacijenata sa ukupno 20 autotransplantata. Širina rezidualnog alveolarnog grebena merena je pre i posle postavljanja transplantata, kao i neposredno pre ugradnje implantata. Svi implantati su opterećeni privremenim nadoknadama 48 sati nakon ugradnje. Stabilnost implantata procenjena je primenom analize rezonantne frekvencije. **Rezultati.** Srednje vreme između uvećavanja grebena i ugradnje implantata iznosilo je 5,4 (4–6) meseci. Pre ugradnje implantata srednja vrednost širine grebena iznosila je $6,1 \pm 1,27$ mm, a povećanja širine grebena u odnosu na vrednosti pre uvećanja $3,04 \pm 1,22$ mm. Površinska resorpcija grafta iznosila je 18,85% ($0,68 \pm 0,69$ mm). Srednja vrednost koeficijenta implantne stabilnosti (ISQ) u momentu ugradnje iznosila je $71,25 \pm 5,77$. Najniže vrednosti ISQ zabeležene su u trećoj nedelji nakon ugradnje, što je bilo praćeno postepenim porastom do dvanaeste nedelje zarastanja. Nakon dvanaest nedelja vrednosti ISQ bile su statistički značajno više od vrednosti u momentu ugradnje ($p < 0,05$ Wilcoxon test). Tokom trogodišnjeg perioda praćenja nije bilo izgubljenih implantata. **Zaključak.** Bez obzira na značajan stepen resorpcije autotransplantata, kod svih pacijenata bilo je moguće ugraditi implantate u uvećani greben, kao i primeniti protokol ranog opterećenja bez uticaja na stepen preživljavanja implantata.

Ključne reči:

maksila; alveolni greben, podizanje; transplantacija, autologna; stomatološki implantati; kost, resorpcija; lečenje, ishod.

Introduction

Quantity and quality of available bone for dental implants placement significantly affect final results of implant surgery. Besides other variables, long-term maintenance of esthetic results is largely dependent on thickness of labial cortex covering the implant¹. Therefore, sufficient bone volume is among the most important factors when it comes to implant surgery in the anterior maxilla.

The use of autogenous bone grafts for augmentation of the resorbed alveolar ridge is still considered the gold standard in implant dentistry². Although usage of autogenous bone block grafts from the retromolar region proved to be safe and effective procedure³⁻⁵, there are still some issues which should be considered when planning this kind of surgery. Horizontal ridge augmentation with autogenous block grafts and a bioinert expanded polytetrafluoroethylene (ePTFE) membrane is well documented, with good clinical results⁶. The lack of this procedure is a certain risk of wound dehiscence, membrane exposure and subsequent site infection⁷. Usage of collagen membranes reduces risk of dehiscence but it seems that their barrier function is limited to a few weeks⁸. On the other hand, it has been demonstrated that mandibular bone grafts can be used for ridge augmentation without barrier membrane⁹. Still, such approach might be related to increased resorption of the graft, affecting the final result of grafting procedure^{10,11}.

At last, this kind of surgery should enhance not only dimensions of residual alveolar ridge, but also should improve bone quality at the site of future implant placement. This is particularly important in the frontal segment of the upper jaw, where increased bone density and implant stability should allow for immediate loading of the implants, providing patients with esthetically acceptable restoration in a shortened period of time.

Therefore, the aim of this study was to analyze clinical outcomes of autogenous bone block grafts from the retromolar region placed in the frontal segment of the upper jaw, to assess resorption rates of grafts unprotected by barrier membranes at the time of implant placement, as well as to assess the stability of implants placed into the grafted bone and to monitor its changes during the healing period of implants restored according to immediate loading protocol, as well as to report survival rate of these implants.

Methods

The study sample included 18 patients. The patients were fully informed about the surgical procedures and treatment alternatives. The protocol of the study was approved by the institutional Ethics Committee.

Inclusion criteria comprised the American Society of Anesthesiology (ASA) physical status classification system I and II patients, aged 20 or more, missing one or more teeth in the frontal segment of the upper jaw. In all the cases the available width of the residual ridge was insufficient for placement of standard diameter implants without significant augmentation at the implant site. The minimum time allowed between tooth extraction and augmentation procedure was

six weeks. When due to severe infection or trauma postextraction defects presented with less than three walls, grafts were placed before complete bone healing (less than four months post extraction).

Upon standard flap reflection, the width of alveolar ridge was measured with a caliper prior and after the augmentation in two levels, at 5 mm and 10 mm from cemento-enamel junction (CEJ) of the neighboring teeth. Special ablative bur, 5 mm in diameter, was used to remove cortex at the recipient site and prepare bony bed for the future bone graft.

All grafts were harvested from the retromolar area. The osteotomy was performed with a trephine bur with 5 mm inner diameter, in a straight surgical handpiece, under copious saline irrigation. The trephine bur was graduated and preparation was performed to the depth of 10 mm. Using a thin surgical chisel and a hammer, the block graft was mobilized and prepared for the augmentation procedure. After harvesting procedure, the bone block was slightly adapted to the recipient site and secured by osteosynthesis screws of 10 mm in length in order to obtain bicortical fixation. The augmented alveolar ridge was measured again with caliper at the same reference points as before the graft placement. Voids around the block graft were filled with anorganic bovine bone matrix (ABBM) particles. A periosteal-releasing incision was made and primary closure was obtained without any tension in the grafted area.

After 6 months the grafted sites were re-exposed and second surgery was performed. New measurements of ridge width were made on the grafted site, using the same caliper and reference points as during the augmentation procedure. Osteosynthesis screws were removed and the Brånemark System[®] Mk III implants (10 mm length, 4.0 mm diameter) were placed in an optimal position, following instructions from the manufacturer.

The primary stability of implants placed in the grafted area was measured by resonance frequency analysis (RFA). Measurements were repeated during the healing period at the postoperative weeks 3, 6, 8 and 12. The measuring devices (Smartpeg[™]) were attached to the implant and measurements were performed according to the manufacturer's instructions, with the probe aiming from the buccal direction. The probe was held at the distance of 2–3 mm until the instrument displayed the implant stability quotient (ISQ) value. Two ISQ values were recorded and used as a mean value for statistical analysis.

After implant placement temporary crowns were made from composite material and fixed within 48 hours after the weeks after implants installation.

Descriptive statistics was used to report the mean values and standard deviations of the reported parameters. Student's *t*-test and Wilcoxon signed ranks test were used to analyze the differences in graft resorption rates and ISQ values. *P* values of < 0.05 were considered to be statistically significant. Calculations were performed using SPSS 10.0 statistical software.

Results

In 18 of the patients (11 males, 7 females; mean age 29 years; range 19–47 years), a total of 20 alveolar sites were

augmented (Table 1). No major intraoperative and postoperative complications were noted.

The widths of the residual alveolar ridge before and after the augmentation and also at the time of implant placement are shown in Table 2. Prior to augmentation, the mean width of 3.06 mm was insufficient to allow optimal placement of 4.0 mm diameter implants. It is interesting that the mean thickness of the graft was less than 4 mm, although a trephine bur of 5 mm diameter was used for graft harvesting, indicating that some of bony tissue was lost during graft mobilization and adaptation to the recipient site (Table 2).

The average period from ridge augmentation to reentry was 5.4 months (4–6 months). At reentry the healed alveolar ridge had the mean width of more than 6 mm, which was sufficient for implant placement. The mean calculated width gain was approximately 3 mm. The overall surface resorption of block grafts was 18.85% on 5 mm and 20.04% on 10 mm from CEJ. There was no statistically significant difference between graft resorption in these two reference points ($p > 0.05$; t -test) (Table 2).

Out of 20 implants 19 had primary stability higher than 60 ISQ (Figure 1). At the time of implant placement the

Table 1

Augmentation sites and demographic data					
No	Age	Gender	Time of tooth loss (months ago)	Reason of tooth loss	Recipient site
1	25	M	1.5	Trauma	21
2	25	M	3	Trauma	21
3	38	F	84	Trauma	21
4	23	F	42	Trauma	11
5	24	M	4	Trauma	11
6	24	F	84	Trauma	21
7	24	M	6	Trauma	11
8	22	M	36	Trauma	11
9	22	M	36	Trauma	12
10	29	F	180	Infection	12
11	25	F	8	Trauma	11
12	25	M	120	Trauma	22
13	24	M	120	Trauma	21
14	30	M	1	Trauma	22
15	49	F	3	Trauma	21
16	34	M	18	Trauma	21
17	39	M	36	Trauma	22
18	35	M	18	Infection	22
19	35	M	19	Infection	23
20	34	F	1.5	Infection	21

M – male; F – female.

Table 2

Measurements of residual ridge width							
Width		Pre-augmentation	Post-augmentation	Thickness of graft	Re-entry width	Graft gain	Amount of surface resorption
5 mm from CEJ (mean ± SD)	Mean	3.06 ± 1.55	6.78 ± 1.26	3.72 ± 0.86	6.10 ± 1.27	3.04 ± 1.22	0.68 ± 0.69
	Minimum	1.8	4.5	2	4.3	0.7	0
	Maximum	4.8	9.2	5.3	9	5	2.5
10 mm from CEJ (mean ± SD)	Mean	5.84 ± 1.69	9.47 ± 1.79	3.63 ± 1.17	8.74 ± 1.59	2.90 ± 1.11	0.73 ± 0.75
	Minimum	3.7	6	0.5	6	0.5	0
	Maximum	10.2	12.5	5.3	12	5.3	2.8

CEJ – cemento enamel junction; SD – standard deviation.

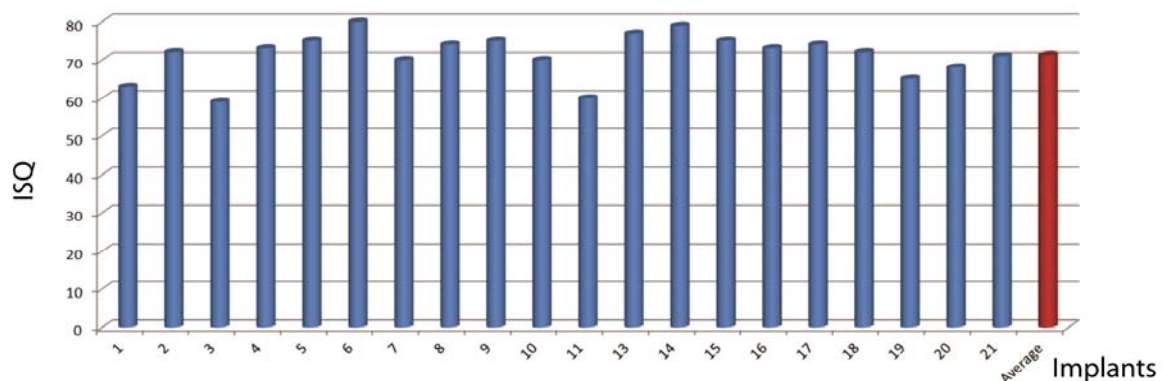


Fig. 1 – Primary implant stability quotient (ISQ) of 20 implants.

mean value of implant stability was 71.25 ± 5.77 ISQ. During the healing period, slight decrease of the mean implant stability was noted after three weeks of healing, just to be followed by another rise of ISQ values till the end of the observation period (Figure 2). There were no significant differences between the implants stability measured at the weeks 3, 6 and 8 and the primary implants stability ($p > 0.05$) but the difference between the implants stability at twelve weeks after the surgery and the primary stability was significant ($p < 0.05$ Wilcoxon signed ranks test).

During the 3-year follow-up period no cases of implant loss were recorded, constituting survival rate of 100%.

As an alternative to ePTFE membranes, it was demonstrated that resorbable collagen membranes also exert protective effect and reduce amount of graft resorption. Von Arx and Buser¹³ demonstrated grafts resorption rate of 7.2% using collagen membrane and ABBM particles. However, besides the protective effect of collagen membranes it was shown that ABBM materials *per se* are able to reduce graft resorption. In the study from Maiorana et al.¹⁴ the resorption of bone block grafts of only 9.3% for the sites treated with ABBM particles was found, whereas the sites without coverage demonstrated the resorption rate of 18.3%. Such effect might be attributed to the fact that these bone substitutes demonstrate slow and minimal resorption^{15,16}.

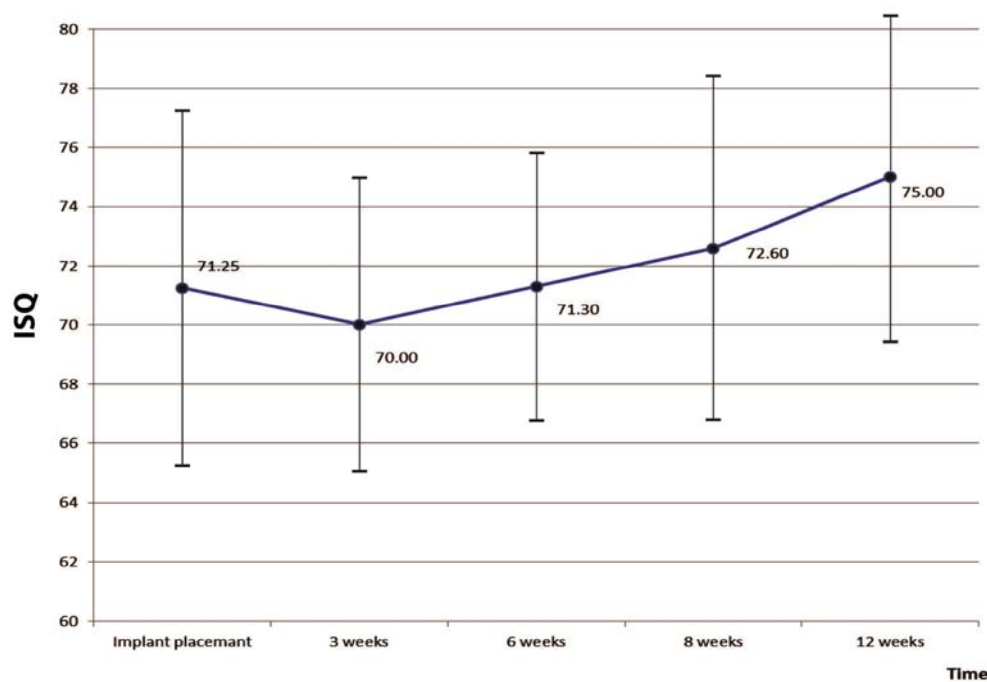


Fig. 2 – Changes of the implant stability quotient (ISQ) (mean ISQ values and standard deviations) during the healing period.

Discussion

Several techniques have been proposed for augmentation of the residual alveolar ridge, including bone blocks harvested from the mandible and positioned at the time of implant placement¹², but also bone grafts from intra-oral or extra-oral donor sites transplanted several months before the implantation⁷.

However, the principal issue when discussing bone block grafts is amount of surface resorption, as this phenomenon might significantly affect final result of grafting procedure. Graft resorption is largely dependent on the usage of barrier membranes. In the study from Antoun et al.¹¹ grafted sites covered by non-resorbable ePTFE membrane showed the mean surface resorption of 0.3 mm (resorption rate of 7.5%) compared to the control group sites without membrane, with the mean resorption of 2.3 mm (resorption rate of 45%)¹⁰.

Still, in several studies it was shown that autogenous bone blocks might be used for ridge augmentation without coverage by membranes and/or particulated grafting materials. Using autogenous bone grafts from chin and mandibular ramus, Cordaro et al.⁹ reported 20% of graft resorption on maxillary sites. In a similar protocol, the resorption of 13.1% was reported for ramus block grafts used for augmentation of future implant sites in the upper jaw¹⁷. In our study the mean surface resorption of grafts from the retromolar region was 19.45%, which was similar to the results of Proussaefs et al.¹⁸, who reported 17% of graft resorption using mandibular ramus block grafts, and particles of Bio-Oss at a periphery. In contrast to studies in which ABBM particles were used to protect graft surface, in our study this material was used only to fill the gaps around block graft and recipient bone, but it seems that such procedure does not affect the amount of graft resorption. Still, it has to be noted that the apparently signifi-

cant resorption of almost 20% of graft width actually represents the loss of only 0.7 mm in the horizontal dimensions of future implant site. From that point of view, it seems that for a significant number of cases this degree of graft resorption might be clinically acceptable.

It is of interest that monitoring of RFA results during the healing period showed similar pattern of ISQ changes as reported in previous studies. Although not statistically significant, it was evident that ISQ values decreased during the first three weeks of healing. Such a decrease, already well recognized in the literature¹⁹⁻²², reflects initial phases of bone remodeling around newly placed implants and, from our results, it seems that such a process is similar both in grafted and native bone. Also, it was shown that initial fall of implant stability is followed by gradual increase of ISQ values, which were significantly higher after 12 weeks of healing.

Finally, it is of importance that initial implant stability was sufficiently high to allow immediate loading of implants placed into the grafted anterior maxilla. Such possibility is particularly important in this part of the jaws, as it provides esthetically acceptable restorations to be made in a shortened period of time. In the present study, the mean ISQ values of primary stability (71.25) were high enough to justify the immediate loading protocol²³. Even more, although two implants demonstrated slightly lower values of the primary stability (58 and 59 ISQ) these implants were subjected to immediate loading without affecting their survival. Such a result is in agreement with studies indicating that the primary stability of ISQ *per se* has low predictive value regarding future osseointegration of implants²⁴.

High ISQ values in this study might be partially explained by changes in bone density following the grafting procedure. It was demonstrated that block grafts from mandibular ramus show high degrees of mineralization (68.7%) and that such a high percentage of mineral content is largely preserved during the healing period²⁵. Hence, it seems reasonable to believe that grafting of the anterior maxilla by autogenous block grafts from the retromolar area improves bone density of future implant sites.

Furthermore, although there was a slight decrease in ISQ values over the first three weeks of healing, the stability of implants was still high enough not to affect the process of osseointegration, which is demonstrated by the fact that no implants were lost during the follow-up period. Several studies reported 100% survival rate of immediately loaded single implants in anterior maxilla²⁶⁻³⁰. The results of our study indicate that the same high survival rates might be obtained in both grafted and native sites. From this study it seems that bone augmentation of the anterior maxilla using bone blocks from the mandibular ramus is a safe and predictable procedure, with low complications rates. Although resorption of grafts unprotected by barrier membranes might be substantial, the amount of residual graft was large enough to allow optimal implant placement in most of the cases.

Conclusion

Considering the results of this study, it seems that the stability of implants placed into the grafted bone is high enough to allow the immediate loading protocol to be used, not affecting the survival rate of implants during the 3-year follow-up period.

Acknowledgments

This study was supported by grant No. 175021 from the Ministry of Education, Science and Technological Development of the Republic of Serbia.

Conflicts of interest

The authors deny any conflicts of interest regarding this study. A set of special ablative and trephine burs for graft harvesting was produced by Hager & Meisinger, GbmH, Germany. RFA measurements were performed using the Osstell mentor™ (Integration Diagnostics AB, Göteborg, Sweden). All devices and instruments were obtained under commercial conditions.

R E F E R E N C E S

1. Grunder U, Gracis S, Capelli M. Influence of the 3-D bone-to-implant relationship on esthetics. *Int J Periodontics Restorative Dent* 2005; 25(2): 113-9.
2. Nkenke E, Radespiel-Tröger M, Wilfang J, Schultze-Mosgau S, Winkler G, Neukam FW. Morbidity of harvesting of retromolar bone grafts: A prospective study. *Clin Oral Impl Res* 2002; 13(5): 514-21.
3. von Arx T, Hardt N, Wallkamm B. The TIME technique: A new method for localized alveolar ridge augmentation prior to placement of dental implants. *Int J Oral Maxillofac Implants* 1996; 11(3): 387-94.
4. Misch CM. Comparison of intraoral donor sites for onlay grafting prior to implant placement. *Int J Oral Maxillofac Implants* 1997; 12(6): 767-76.
5. Pikos MA. Alveolar ridge augmentation with ramus buccal shelf autografts and impacted third molar removal. *Dent Implantol Update* 1999; 10(4): 27-31.
6. Buser D, Dula K, Hirt HP, Schenk RK. Lateral ridge augmentation using autografts and barrier membranes: a clinical study with 40 partially edentulous patients. *J Oral Maxillofac Surg* 1996; 54(4): 420-32.
7. Chiapasco M, Abati S, Romeo E, Vogel G. Clinical outcome of autogenous bone blocks or guided regeneration with e-PTFE membranes for reconstruction of narrow edentulous ridges. *Clin Oral Impl Res* 1999; 10(4): 278-88.
8. Owens KW, Yukna RA. Collagen membrane resorption in dogs: a comparative study. *Implant Dent* 2001; 10(1): 49-58.
9. Cordaro L, Amadè DS, Cordaro M. Clinical results of alveolar ridge augmentation with mandibular block bone grafts in partially edentulous patients prior to implant placement. *Clin Oral Impl Res* 2002; 13(1): 103-11.
10. ten Bruggenkate CM, Kraaijenhagen HA, van der Kwast WA, Krekelier G, Oosterbeek HS. Autogenous maxillary bone grafts in conjunction with placement of I.T.I. endosseous implants. A

- preliminary report. *Int J Oral Maxillofac Surg* 1992; 21(2): 81–4.
11. *Anton H, Sibon JM, Martinez H, Missika P.* A prospective randomized study comparing two techniques of bone augmentation: onlay graft alone or associated with a membrane. *Clin Oral Impl Res* 2001; 12(6): 632–9.
 12. *Jensen J, Sindet-Pedersen S.* Autogenous mandibular bone grafts and osseointegrated implants for reconstruction of the severely atrophied maxilla: a preliminary report. *J Oral Maxillofac Surg* 1991; 49(12): 1277–87.
 13. *von Arx T, Buser D.* Horizontal ridge augmentation using autogenous block grafts and the guided bone regeneration technique with collagen membranes: A clinical study with 42 patients. *Clin Oral Implants Res* 2006; 17(4): 359–66.
 14. *Maiorana C, Beretta M, Salina S, Santoro F.* Reduction of autogenous bone graft resorption by means of Bio-Oss coverage: A prospective study. *Int J Periodontics Restorative Dent* 2005; 25(1): 19–25.
 15. *Araújo MG, Sonohara M, Hayacibara R, Cardaropoli G, Lindhe J.* Lateral ridge augmentation by the use of grafts comprised of autologous bone or a biomaterial. An experiment in the dog. *J Clin Periodontol* 2002; 29(12): 1122–31.
 16. *von Arx T, Cochran DL, Schenk RK, Buser D.* Evaluation of a prototype trilayer membrane (PTLM) for lateral ridge augmentation: an experimental study in the canine mandible. *Int J Oral Maxillofac Surg* 2002; 31(2): 190–9.
 17. *Acocella A, Bertolai R, Colafranceschi M, Sacco R.* Clinical, histological and histomorphometric evaluation of the healing of mandibular ramus bone block grafts for alveolar ridge augmentation before implant placement. *J Craniomaxillofac Surg* 2010; 38(3): 222–30.
 18. *Prousaefs P, Lozada J, Kleinman A, Rohrer MD.* The use of ramus autogenous block grafts for vertical alveolar ridge augmentation and implant placement: A pilot study. *Int J Oral Maxillofac Implants* 2002; 17(2): 238–48.
 19. *Bischof M, Nedir R, Szemekler-Moncler S, Bernard JP, Samson J.* Implant stability measurement of delayed and immediately loaded implants during healing. *Clin Oral Impl Res* 2004; 15(5): 529–39.
 20. *Han J, Lulic M, Lang NP.* Factors influencing resonance frequency analysis assessed by Osstell™mentor during implant tissue integration: II. Implant surface modifications and implant diameter. *Clin Oral Impl Res* 2010; 21(6): 605–11.
 21. *Sim CC, Lang NP.* Factors influencing resonance frequency analysis assessed by Osstell™mentor during implant tissue integration: I. Instrument positioning, bone structure, implant length. *Clin Oral Impl Res* 2010; 21(6): 598–604.
 22. *Zembić A, Glauser R, Khrasat A, Hämmerle CH.* Immediate vs. early loading of dental implants: 3-year results of a randomized controlled clinical trial. *Clin Oral Impl Res* 2010; 21(5): 481–9.
 23. *Sennerby L, Meredith N.* Analisi della frequenza di risonanza (RFA). Conoscenze attuali e implicazioni cliniche. In: *Chiapasco M, Gatti C*, editors. *Osteointegrazione e carico immediato. Fondamenti biologici e applicazioni cliniche.* Milano, Italia: Masson; 2001. p. 19–31.
 24. *Krafft T, Graef F, Karl M.* Osstell resonance frequency measurement values as a prognostic factor in implant dentistry. *J Oral Implantol* 2015; 41(4): e133–7.
 25. *Thorwarth M, Srour S, Felszeghy E, Kessler P, Schultze-Mosgau S, Schlegel KA.* Stability of autogenous bone grafts after sinus lift procedures: a comparative study between anterior and posterior aspects of the iliac crest and an intraoral donor site. *Oral Surg Oral Med Oral Pathol Oral Radiol Endod* 2005; 100(3): 278–84.
 26. *Hui E, Chow J, Li D, Liu J, Wat P, Law H.* Immediate provisional for single-tooth implant replacement with Brånemark system: preliminary report. *Clin Implant Dent Relat Res* 2001; 3(2): 79–86.
 27. *Andersen E, Haanaes HR, Knutsen BM.* Immediate loading of single-tooth ITI implants in the anterior maxilla: a prospective 5-year pilot study. *Clin Oral Implants Res* 2002; 13(3): 281–7.
 28. *Kan JY, Rungcharusaeng K, Lozada J.* Immediate placement and provisionalization of maxillary anterior single implants: 1-Year prospective study. *Int J Oral Maxillofacial Implants* 2003; 18(1): 31–9.
 29. *Prousaefs P, Lozada J.* Immediate loading of hydroxyapatite-coated implants in the maxillary premolar area: three-year results of a pilot study. *J Prosthet Dent* 2004; 91(3): 228–33.
 30. *Glauser R, Rühstaller P, Windisch S, Zembić A, Lundgren A, Gottlow J*, et al. Immediate occlusal loading of Brånemark System Ti-Unite implants placed predominantly in soft bone: 4-year results of a prospective clinical study. *Clin Implant Dent Relat Res* 2005; 7(1): 52–9.

Received on April 29, 2015.

Revised on July 20, 2015.

Accepted on December 01, 2015.

Online First July, 2016.