



## Apical root-end filling with tricalcium silicate-based cement in a patient with diabetes mellitus: A case report

Punjenje kanala korena cementom na bazi trikalcijum-silikata kod bolesnika sa dijabetesom melitusom

Vladimir Biočanin\*, Marija Milić†, Milan Vučetić‡, Miljana Bačević‡, Dina Vasović†, Milka Živadinović†, Dejan Četković‡, Dejan Čalasan†, Božidar Brković†

\*Department of Dentistry, Faculty of Pharmacy and Health, University of Travnik, Travnik, Bosnia and Herzegovina, and Private Practice, Belgrade, Serbia; †Clinic of Oral Surgery, ‡Anatomy Institute, Faculty of Dental Medicine, University of Belgrade, Belgrade, Serbia

### Abstract

**Introduction.** The material used for root-end filling has to be biocompatible with adjacent periapical tissue and to stimulate its regenerative processes. Tricalcium silicate cement (TSC), as a new dental material, shows good sealing properties with dentin, high compression strengths and better marginal adaptation than commonly used root-end filling materials. Although optimal postoperative healing of periapical tissues is mainly influenced by characteristics of end-root material used, it could sometimes be affected by the influence of systemic diseases, such as diabetes mellitus (DM). **Case report.** We presented apical healing of the upper central incisor, retrofilled with TSC, in a diabetic patient (type 2 DM) with peripheral neuropathy. Standard root-end resection of upper central incisor was accompanied by retropreparation using ultrasonic retrotips to the depth of 3 mm and retrofilling with TSC. Postoperatively, the surgical wound healed uneventfully. However, the patient reported undefined dull pain in the operated area that could possibly be attributed to undiagnosed intraoral diabetic peripheral neuropathy, what was evaluated clinically. **Conclusion.** Although TSC presents a suitable material for apical root-end filling in the treatment of chronic periradicular lesions a possible presence of systemic diseases, like type 2 DM, has to be considered in the treatment outcome estimation.

### Key words:

periapical diseases; oral surgical procedures; dental cements; silicates; diabetes mellitus, type 2; comorbidity; diabetic neuropathies.

### Apstrakt

**Uvod.** Materijal koji se koristi za retrogradnu opturaciju kanala korena trebalo bi da bude biokompatibilan sa okolnim periapikalnim tkivom i da stimuliše procese njegove regeneracije. Trikalcijum silikatni cement (TSC), kao novi dentalni materijal, pokazuje dobro zaptivanje, visoku kompresivnu snagu i bolju ivičnu adaptaciju u odnosu na standardno korišćene materijale za retroopturaciju. Iako postoperativno zarastanje periapikalnog tkiva najviše zavisi od karakteristika materijala za retroopturaciju, ponekad na uspeh zarastanja može uticati i prisustvo neke sistemske bolesti kao što je dijabetes melitus (DM). **Prikaz bolesnika.** Prikazali smo apikalno zarastanje u predelu gornjeg centralnog sekutića, nakon retroopturacije sa TSC, kod bolesnika sa DM tipa 2 i prisutnom perifernom neuropatijom. Standardna resekcija korena gornjeg centralnog sekutića bila je urađena retropreparacijom ultrazvučnim nastavcima do dubine od 3 mm i retrogradnom opturacijom sa TSC. Zarastanje postoperativne regije bilo je u fiziološkim granicama. Bolesnik se, međutim, žalio na nedefinisani, tup bol u predelu operisane regije koji je verovatno bio povezan sa nedijagnostikovanom intraoralnom dijabetičnom perifernom neuropatijom, što je potvrđeno kliničkim nalazom. **Zaključak.** Iako TSC predstavlja pogodan materijal za retrogradnu opturaciju kanala korena zuba u lečenju hroničnih periradikalarnih lezija, u proceni ishoda lečenja treba imati u vidu i moguće prisustvo perifernih manifestacija sistemskih bolesti kao što je DM tipa 2.

### Ključne reči:

periapeksne bolesti; hirurgija, oralna, procedure; zub, cement; silikati; dijabetes melitus, insulin-nezavisni; komorbiditet; dijabetesne neuropatije.

## Introduction

The primary goal of periradicular surgery is to seal the apex of the root canal hermetically, preventing the passage of microorganisms or their products into adjacent periapical tissues. Traditionally, root-end filling is obtained by amalgam or different types of cement<sup>1</sup>. However, modern apical surgery is still seeking for the material with superb long-time mechanical properties and excellent apical obturation together with biostimulation of regenerative processes of apical tissues<sup>2</sup>. Beside the mentioned properties of the material used, it has to be biocompatible to the neighbouring periapical tissues<sup>3</sup>. On the other hand, there are still some possible complications of periradicular surgery related to disadvantages of materials used for root-end filling<sup>4,1</sup>.

Tricalcium silicate cement (TSC), as a new dental material, shows mechanical and safety profile which could improve the quality of apical obturation<sup>5,6</sup>. It was also shown that TSC possesses good sealing properties with dentin and high compression strengths<sup>7,6</sup>. TSC provides better marginal adaptation than commonly used root-end filling materials<sup>8</sup>.

Although optimal postoperative healing of periapical tissues is mainly influenced by the characteristics of root-end material used, it could sometimes be affected by the peripheral appearance of systemic diseases<sup>4</sup>. Diabetes mellitus (DM) results in delayed wound healing and associated complications in dental treatments<sup>9,10</sup>. It was already shown that DM decreased osteoblasts function in the rat model<sup>11</sup>. In addition, microvascular changes found in DM may decrease the reparatory processes of soft and hard tissue and, gradually, could lead to postoperative complications, such as diabetic neuropathy<sup>12-15</sup>.

The aim of this report was to present apical healing of the upper central incisor, retrofilled with TSC, in a diabetic patient with possible peripheral neuropathy, as a complication associated with type 2 DM.

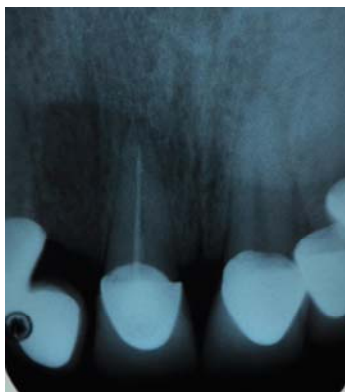## Case report

A 53-year-old man, suffering from type 2 DM, with peripheral neuropathy and cardiovascular complications (ASA

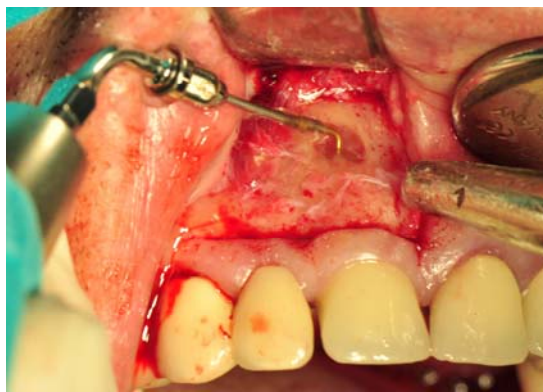
III), was referred by his general dental practitioner to the Clinic of Oral Surgery, Faculty of Dental Medicine, University of Belgrade, for root apical surgery of the right central incisor. Clinical examination showed the presence of a fistula in the region of the root apex of the tooth. There were no signs and symptoms of acute dental infection, although the patient indicated unpleasant discomfort and unmarked chronic pain of the alveolar ridge on the right side. In addition, retroalveolar radiogram was done and short canal filling with well demarcated slight periapical radiolucency were seen around the root apex of tooth (Figure 1). It was decided to perform root-end surgery, implying resection of the root-end and retrofilling with tricalcium silicate cement (TSC) (Biodentine<sup>®</sup>, Septodont, Saint des Fausses, France) under high magnifying glass.

Standard root resection included sectioning the root-end with fissure bar for approximately 2 mm; retro-preparation was done using ultrasonic retro-tips, to the depth of 3 mm (Figure 2). TSC was placed in the 3 mm deep retrograde cavity of the root-end (Figure 3). After the setting time was finished, the wound was debrided and closed primarily.

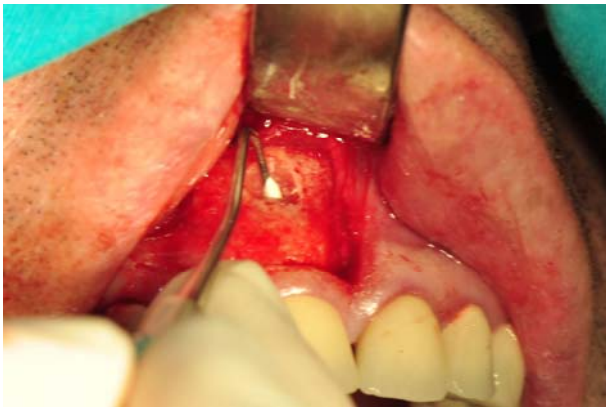
One month after the operation, the patient complained to constant, undefined, dull pain and discomfort in the operated region, which lasted for the next 3 months. Clinical examination and control retroalveolar radiogram did not show any signs of pathological lesion (Figure 4). There was no fistula in the region of oral mucosa or attached gingiva. Also, there were no periodontal pockets around the tooth 11. Regarding that, it was necessary to distinguish the possible presence of vertical root fracture, which usually cannot be diagnosed radiographically. For that reason the re-entry was done. When a full-thickness trapezoid mucoperiosteal flap was elevated, almost complete bone healing in the operated area was present (Figure 5). There were no signs of vertical root fracture. At the end, the operated area was copiously irrigated with saline and interrupted sutures were placed. Follow-up was done 3 and 6 months and 2 years after re-entry and there were no changes both clinically and radiographically. During these observation periods the mentioned disturbances at the operated region were recorded occasionally, with different intensity and usually lasted for several weeks.



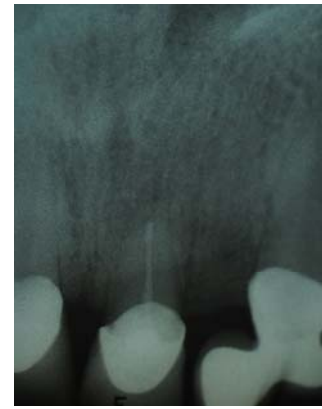
**Fig. 1 – Incorrect root canal 11 filling and slight apical radiolucency.**



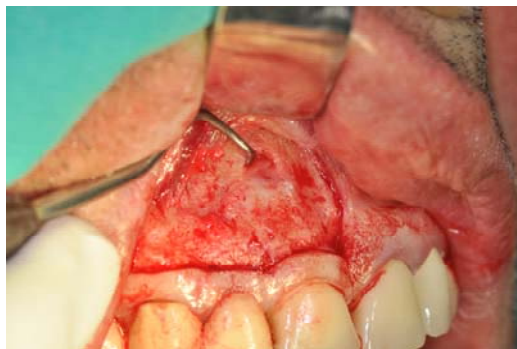**Fig. 2 – Retro-preparation with ultrasonic retrotip.**



**Fig. 3 – Root end filling with tricalcium silicate cement (TSC).**



**Fig. 4 – Control retroalveolar radiogram 3 months after the surgery.**



**Fig. 5 – Complete bone healing after re-entry.**

## Discussion

Different materials have been used for filling root-ends. *In vitro* and *in vivo* studies have shown that mineral trioxide aggregate (MTA), as a gold standard, has considerable sealing ability and better marginal adaptation to dentin<sup>16–18</sup>, compared to amalgam, super-EBA (ethoxy-benzoic acid) and IRM (intermediate restorative material) cement<sup>19</sup>. However, many drawbacks of MTA, such as difficulties with handling, long setting time and high cost, restricts its use as a root-end filling material. In addition, it was found that in higher concentrations, MTA was toxic to cementoblasts<sup>20</sup>.

Tricalcium silicate-based cement – Biodentine<sup>®</sup>, was introduced as a bioactive material, with the idea of overcoming disadvantages of MTA. Its bioactivity was shown on pulp cells by stimulation biomineralisation<sup>21</sup>. Likewise, new calcium silicate-based cement induced odontoblast stimulation and the production of tertiary dentin in the rat pulp injury model<sup>22</sup>. Applied directly onto human pulp, TSC induced stimulation, biomineralization and odontoblast differentiation<sup>23,21</sup>. It was also shown that TSC induced osteoblast differentiation in mesenchymal stem cells<sup>24</sup>. When used as root-end filling material, TSC showed the least microleakage compared to other cements<sup>25</sup>. TSC-based cement produced more prominent  $\text{Ca}^{2+}$  and  $\text{Si}^{2+}$  uptake into the root canal dentine than MTA when used as a root canal obturation material in bovine incisors<sup>2</sup>. Butt et al.<sup>26</sup> suggested that Biodentine possesses better sealing ability, higher compressive strength and better handling consistency than MTA. The most recent

study of Bhavana et al.<sup>27</sup> revealed that TSC had higher antibacterial and antifungal activity than MTA.

Having in mind all the mentioned advantages and direct biological effect of TSC on bone healing, it was expected to have a successful surgical result after being used for retrofilling in the presented patient, showing clinical and radiographic evidence of complete healing. However, the patient reported undefined dull pain in the operated area a month after surgery, which lasted for next 3 months. Pain in the operated area could possibly be attributed to undiagnosed intraoral diabetic peripheral neuropathy, concerning the fact that the patient suffered from type 2 DM for more than 10 years. It was also documented that signs of intraoral peripheral neuropathy, such as the loss of intraoral sensation, hyperesthesia, dysesthesia and temporomandibular dysfunction could be related with clinically evident peripheral diabetic neuropathy<sup>28</sup>. The possible detrimental influence of diabetic neuropathy in progression of chronic orofacial pain could be also corroborated with unpleasant burning mouth syndrome and nonspecific soreness that affect intraoral structures<sup>29</sup>. Furthermore, it was proposed that prolonged effect of local anaesthetic solution could provoke pain in the operating area. Namely, it was already shown that the incidence of diabetic neuropathy increased after spinal and neuraxial block anesthesia<sup>30,31</sup>. Dull pain that the patient described could possibly be explained by microangiopathy of peripheral dental nerves associated with DM and adjunct prolong ischemic effect of vasoconstrictors from local anaesthetic that was administered in the close proximity to peripheral nerves. Atypical facial pain

(AFP) could be considered in differential diagnosis, having in mind its chronic character. Idiopathic or AFP could be described as deep or superficial, poorly localised, and sometimes bilateral pain, predominantly in middle-aged and older women<sup>32,33</sup>. On the other hand, dull character of pain localised only in the operated area, could possibly be attributed to peripheral diabetic neuropathy, distinguishing it clinically from AFP.

### Conclusion

Tricalcium silicate cement presents a suitable material for apical root-end filling with good mechanical and biological

properties. However, there are still little data concerning long-term results of using TSC as a root-end filling material in clinical trials, especially in the risk group of patients such as patients with diabetes mellitus, with changed peripheral healing capacity. Further long-term clinical studies are needed to precisely determine clinical and biological behaviour of TSC as a root-end filling material and to confirm the direct evidence of regeneration of periapical tissues in humans.

### Acknowledgements

This study was supported by the Grant No 175021 from the Ministry of Science of Republic of Serbia.

### R E F E R E N C E S

1. *Chong BS, Pitt FT.* Root-end filling materials: rationale and tissue response. *Endodontic Topics* 2005; 11(1): 114–30.
2. *Han L, Okiji T.* Uptake of calcium and silicon released from calcium silicate-based endodontic materials into root canal dentine. *Int Endod J* 2011; 44(12): 1081–7.
3. *Wälivaara D, Abrahamsson P, Isaksson S, Salata LA, Senneryby L, Dahlén C.* Periapical tissue response after use of intermediate restorative material, gutta-percha, reinforced zinc oxide cement, and mineral trioxide aggregate as retrograde root-end filling materials: A histologic study in dogs. *J Oral Maxillofac Surg* 2012; 70(9): 2041–7.
4. *Lima SM, Grisi DC, Kogawa EM, Franco OL, Peixoto VC, Gonçalves-Junior JF,* et al. Diabetes mellitus and inflammatory pulp and periapical disease: A review. *Int Endod J* 2013; 46(8): 700–9.
5. *Koubi G, Colon P, Franquin J, Hartman A, Richard G, Faure MO,* et al. Clinical evaluation of the performance and safety of a new dentine substitute, Bio dentine, in the restoration of posterior teeth-prospective study. *Clin Oral Invest* 2013; 17:243–249.
6. *Grech L, Mallia B, Camilleri J.* Characterization of set Intermediate Restorative Material, Biodentine, Bioaggregate and a prototype calcium silicate cement for use as root-end filling materials. *Int Endod J* 2013; 46(7): 632–41.
7. *Atmeh AR, Chong EZ, Richard G, Festy F, Watson TF.* Dentin-cement interfacial interaction: Calcium silicates and polyalkenoates. *J Dent Res* 2012; 91(5): 454–9.
8. *Ravichandra PV, Vemisetty H, Deepthi K, Reddy JS, Ramkiran D, Krishna JN,* et al. Comparative evaluation of marginal adaptation of Biodentine(TM) and other commonly used root end filling materials: An invitro study. *J Clin Diagn Res* 2014; 8(3): 243–5.
9. *Chaudhary SB, Liporace FA, Gandbi A, Donley BG, Pinuz MS, Lin SS.* Complications of ankle fracture in patients with diabetes. *J Am Academy Orthop Surg* 2008; 16(3): 159–70.
10. *Kotsonilis S, Karoussis IK, Fourmousis I.* A comprehensive and critical review of dental implant placement in diabetic animals and patients. *Clin Oral Implants Res* 2006; 17(5): 587–99.
11. *Verhaeghe J, Herck E, Visser WJ, Suiker AM, Thomasset M, Einhorn TA,* et al. Bone and mineral metabolism in BB rats with long-term diabetes: Decreased bone turnover and osteoporosis. *Diabetes* 1990; 39(4): 477–82.
12. *Devlin H, Garland H, Sloan P.* Healing of tooth extraction sockets in experimental diabetes mellitus. *Journal of oral and maxillofacial surgery* 1996; 54(9): 1087–91.
13. *Tooke JE.* Microvascular function in human diabetes: A physiological perspective. *Diabetes* 1995; 44(7): 721–6.
14. *Malik RA, Veves A, Masson EA, Sharma AK, Ab-See AK, Schady W,* et al. Endoneurial capillary abnormalities in mild human diabetic neuropathy. *J Neurol Neurosurg Psychiatr* 1992; 55(7): 55–61.
15. *Lin JH, Duffy JL, Roginsky MS.* Microcirculation in diabetes mellitus: A study of gingival biopsies. *Hum Pathol* 1975; 6(1): 77–96.
16. *Torabinejad M, Chivian N.* Clinical applications of mineral trioxide aggregate. *J Endod* 1999; 25(3): 197–205.
17. *Torabinejad M, Rastegar AF, Kettering JD, Pitt FT.* Bacterial leakage of mineral trioxide aggregate as a root-end filling material. *J Endod* 1995; 21(3): 109–12.
18. *Torabinejad M, Watson TF, Pitt FT.* Sealing ability of a mineral trioxide aggregate when used as a root end filling material. *J Endod* 1993; 19(12): 591–5.
19. *Torabinejad M, Smith PW, Kettering JD, Pitt FT.* Comparative investigation of marginal adaptation of mineral trioxide aggregate and other commonly used root-end filling materials. *J Endod* 1995; 21(6): 295–9.
20. *Hakki SS, Bozkurt BS, Hakki EE, Belli S.* Effects of mineral trioxide aggregate on cell survival, gene expression associated with mineralized tissues, and biomineralization of cementoblasts. *J Endod* 2009; 35(4): 513–9.
21. *Zanini M, Sautier JM, Berdal A, Simon S.* Biodentine induces immortalized murine pulp cell differentiation into odontoblast-like cells and stimulates biomineralization. *J Endod* 2012; 38(9): 1220–6.
22. *Tran XV, Gorin C, Willig C, Baroukh B, Pellat B, Decup F,* et al. Effect of a calcium-silicate-based restorative cement on pulp repair. *J Dent Res* 2012; 91(12): 1166–71.
23. *Laurent P, Camps J, About I.* Biodentine(TM) induces TGF-β1 release from human pulp cells and early dental pulp mineralization. *Int Endod J* 2012; 45(5): 439–48.
24. *Lee B, Lee K, Koh J, Min K, Chang H, Hwang I,* et al. Effects of 3 endodontic bioactive cements on osteogenic differentiation in mesenchymal stem cells. *J Endod* 2014; 40(8): 1217–22.
25. *Pavar AM, Kokate SR, Shah RA.* Management of a large periapical lesion using Biodentine(TM) as retrograde restoration with eighteen months evident follow up. *J Conserv Dent* 2013; 16(6): 573–5.
26. *Butt N, Talwar S, Chaudhry S, Naval RR, Yadav S, Bali A.* Comparison of physical and mechanical properties of mineral trioxide aggregate and Biodentine. *Indian J Dent Res* 2014; 25(6): 692–7.
27. *Bhavana V, Chaitanya KP, Gandhi P, Patil J, Dola B, Reddy RB.* Evaluation of antibacterial and antifungal activity of new calcium-based cement (Biodentine) compared to MTA and glass ionomer cement. *J Conserv Dent* 2015; 18(1): 44–6.

28. *Collin HL, Niskanen L, Uusitupa M, Toyry J, Collin P, Koivisto AM*, et al. Oral symptoms and signs in elderly patients with type 2 diabetes mellitus. *Oral Surg Oral Med Oral Pathol Oral Radiol Endod* 2000; 90(3): 299–305.
29. *Moore PA, Guggenheimer J, Orchard T*. Burning mouth syndrome and peripheral neuropathy in patients with type 1 diabetes mellitus. *J Diabetes Complicat* 2007; 21(6): 397–402.
30. *Brull R, McCartney CJ, Chan VW, Liguori GA, Hargett MJ, Xu D*, et al. Disclosure of risks associated with regional anesthesia: A survey of academic regional anesthesiologists. *Reg Anesth Pain Med* 2007; 32(1): 7–11.
31. *Hebl JR, Kopp SL, Schroeder DR, Horlocker TT*. Neurologic complications after neuraxial anesthesia or analgesia in patients with preexisting peripheral sensorimotor neuropathy or diabetic polyneuropathy. *Anesth Analg* 2006; 103(5): 1294–9.
32. *Pfaffenrath V, Rath M, Pöhlmann W, Keeser W*. Atypical facial pain: application of the IHS criteria in a clinical sample. *Cephalalgia* 1993; 13(Suppl 12): 84–8.
33. *Zebenholzer K, Wöber C, Vögl M, Wessely P, Wöber-Bingöl C*. Facial pain and the second edition of the International Classification of Headache Disorders. *Headache* 2006; 46(2): 259–63.

Received on June 6, 2015.

Accepted on July 2, 2015.

Online First May 2016.