

# The Influence of Liners on the Pulp Inflammation

Lado Davidović<sup>1</sup>, Mirjana Ćuk<sup>2</sup>, Marija Živković Sandić<sup>3</sup>, Djurica Grga<sup>4</sup>, Slavoljub Živković<sup>4</sup>

<sup>1</sup>University of East Sarajevo, School of Medicine Foča, Department of Restorative Dentistry and Endodontics, Foča, Bosnia and Herzegovina;

<sup>2</sup>University of East Sarajevo, School of Medicine Foča, Department of Pathology, Foča, Bosnia and Herzegovina;

<sup>3</sup>University of Belgrade, Faculty of Dental Medicine, Department of Orthodontics, Belgrade, Serbia;

<sup>4</sup>University of Belgrade, Faculty of Dental Medicine, Department of Restorative Dentistry and Endodontics, Belgrade, Serbia

## SUMMARY

**Introduction** The study included application of liners and dental composites in to cavities of six experimental animals – rabbits (*Oryctolagus cuniculus*).

**Objective** The aim of the study was to investigate rabbit dental pulp response to different liners.

**Methods** Cavity preparation for class V were made on the maxillary central incisors and one lower incisor, while the second lower incisor served as a control tooth. These teeth were restored with the use of one of the following liners – Calciol LC, ANA Liner and Fuji II LC Improved, and Ceram-X mono dental composite. After an observation period of five days animals were sacrificed and prepared for histological analysis. The existence and degree of the pulp inflammation was determined by using a light microscope.

**Results** Results showed that the used liners do not cause distortion of the structure and continuity of the odontoblastic layer. Inflammation was not registered in the control group, while in each group of tested materials one tooth with mild signs of hyperemia was registered. Results showed that all three tested liners demonstrated favorable effects on the pulp of the tooth and did not lead to inflammatory reactions.

**Conclusion** Histological analysis of the dental pulp of experimental animals suggests that the liners used in this study do not compromise the integrity of the odontoblastic layer, if it is applied over a thin layer of dentin. In each group of tested materials one tooth with mild signs of hyperemia and vasodilation was registered.

**Keywords:** liners; pulp; teeth; rabbit

## INTRODUCTION

In the last few decades restorative dentistry has undergone a revolution in materials, restorative techniques and procedures. Composite materials represent a significant step forward in dentistry, primarily because of its aesthetic qualities, acceptable physical and chemical properties and biological quality. Regardless of these characteristics, composite resin is a potential risk to the biological integrity of the pulp [1]. These risks may be due to the toxic properties or some of the material characteristics that cause microleakage and bacterial penetration through microcracks to the pulp [2]. Individual components of the composite resin can cause toxic effects on the pulp [1, 3, 4]. The lack of exact adhesive bond between composite fillings and dental structures is considered to be the main cause of microcracks and penetration of microorganisms, their toxins and oral fluids to the pulp. Despite the development of restorative dentistry, the bond between materials and hard tooth tissues is still not adequate and often leads to marginal discoloration, microleakage, secondary caries and postoperative sensitivity (PS). PS is a complication of the restorative procedure and is characterized by the appearance of a brief, sharp pain that occurs as a result of mechanical, thermal and osmotic stimuli, after restorative treat-

ment. Hypersensitivity usually lasts a few days or weeks, after which it may spontaneously cease. PS is a complication which dentists and patients have been facing for the last few decades [5, 6]. Although these negative effects, to some extent, can be influenced by the design of cavity preparation (size and shape of the cavity), proper application (layered technique) and the choice of materials, in the case of deep caries (*caries profunda*) additional protection of the pulp is needed in most cases [7]. This protection is achieved with application of different liners, whose main role is to protect pulp-dentine complex from harmful material properties that arise from the materials for permanent closure of the cavity and/or microorganisms and oral fluids, which can penetrate through microcracks into the oral cavity. It is believed that liners reduce postoperative sensitivity and provide a better bonding with the dental tissues due to low viscosity, adaptability and adhesiveness. Moreover, liners are mostly dimensionally stable, compatible, and some may act protective and stimulate dentinogenesis. There are a number of different dental products on the market today that are used as liners. However, in professional circles there is still no consensus on what kind of liners are most effective and which ones can provide optimum protection in a particular clinical situation [8].

## Correspondence to:

Lado DAVIDOVIĆ  
Department of Restorative  
Dentistry and Endodontic  
School of Medicine Foča  
University of East Sarajevo  
Studentska bb, 73300 Foča  
Bosnia and Herzegovina  
[ladohak@yahoo.com](mailto:ladohak@yahoo.com)

## OBJECTIVE

The aim of this study was to evaluate the effect of liners based on GIC, compomer and calcium hydroxide, as well as the occurrence and degree of inflammation of the pulp after their application in cavities of experimental animals (rabbits).

## METHODS

### Experimental animals

The research was conducted at the Department of Pathology, School of Medicine Foca, University of East Sarajevo. The study included application of liners and dental composites in the cavities of experimental animals – rabbits (*Oryctolagus cuniculus*). Six animals of the same age and about the same bodyweight ( $\approx 2,500$  g) were included in the experiment. The experiment was carried out in compliance with the principles of good laboratory practice (86/609/EEC), which include the basic principles of asepsis and antisepsis, and in compliance with international standards (International Organization for Standardization, 1997) for working with experimental animals.

### Materials

Materials tested in this study were different types of liners that are indicated for use in deeper cavities in setting posterior composite restorations: Calcimol LC (VOCO, Germany), ANA Liner (Nordiska Dental, Sweden) and Fuji II LC Improved (GC, Japan). After the application of liners, all teeth were restored with Ceram-X Mono composite material (DENTSPLY, USA).

### Experimental protocol

The animals received intramuscular injection of 35 mg/kg of ketamine with constant monitoring of respiration and muscle tone. Cavity preparations for class V were made on the maxillary central incisors and one lower incisor, while the second lower incisor teeth served as a control. Dental handpieces were used for cavity preparation, diamond and carbide burs and dental glasses with magnification 2.5 $\times$ . Material was applied using the following protocol:

- Protocol A – Calcimol LC was used: liner is applied in a thin layer on the surface of dried dentin and polym-

erized for 40 seconds; adhesive procedures included the etching by 37% phosphoric acid, rinsing, slightly drying and use of Prime & Bond adhesive [9], polymerization;

- Protocol B – ANA Liner was used: adhesive procedure identical to protocol A; setting liner in the layer and polymerization for 40 seconds;
- Protocol C – Fuji II LC Improved was used: conditioning of the cavity with cavity conditioner for 10 seconds with the aim of removing the smear layer and activity modulation of Ca<sup>++</sup> ions; rinsing and drying; setting material and polymerization for 40 seconds;
- Five days after the restorative procedure, all animals were euthanized using intramuscular ketamine (50 mg/kg), application of muscle relaxant pancuronium-bromide (Pavulon, 2 mg) and intracardiac application 7.4% KCl (250 mg) to cause cardiac arrest in diastole.

### Histological procedure

Parts of the upper and lower jaws, containing the tested teeth, periodontium and surrounding alveolar bone, were excised and placed in 10% formalin solution for 48 hours and then decalcified in a mild acid (5% solution of formic acid) for 14 days. After that, the samples were held in water and dehydrated with graded ethanol. Then the samples were immersed in xylene and paraffin. The tissue was cut into 4-micrometer thick sections, stained with hematoxylin and eosin and submitted to histological analysis. Assessment of intensity of inflammation was performed under the light microscope at magnification of 200 $\times$  and 400 $\times$  by a trained observer. We analyzed the structure and continuity of the odontoblastic layer, and the signs of the pulp inflammation. The odontoblastic layer is described as intact/notintact, while the condition of the pulp tissue is categorized into four categories [10]: no inflammation, hyperemia-vasodilation, mild inflammation and intense inflammation.

## RESULTS

After the experimental period of five days, histological analysis showed that after their application in cavities tested liners provide good protection of pulp-dentine complex and do not lead to inflammatory reactions in the pulp tissue (Table 1). Histological analysis showed that the application of the liners does not cause any distortion of continuity and structure of the odontoblastic layer, and

**Table 1.** The histological analysis of inflammation of the pulp after the application of liners

Protocol	Odontoblasts		Pulp tissue			
	Intact	Not intact	No inflammation	Hyperemia, vasodilatation	Mild inflammation	Intense inflammation
Control group	6	-	6	-	-	-
Calcimol LC	6	-	5	1	-	-
ANA Liner	6	-	5	1	-	-
Fuji II LC Imp	6	-	5	1	-	-

also does not cause inflammatory reactions in the pulp after restorative procedures. Inflammatory reaction of the pulp was not found in the control group (Figure 1).

During experimental period of 5 days in group where Calcimol LC was used as liner, there was no inflammatory reaction in five teeth (Figure 2), while hyperemia and vasodilation were noticed in just one case (Figure 3).

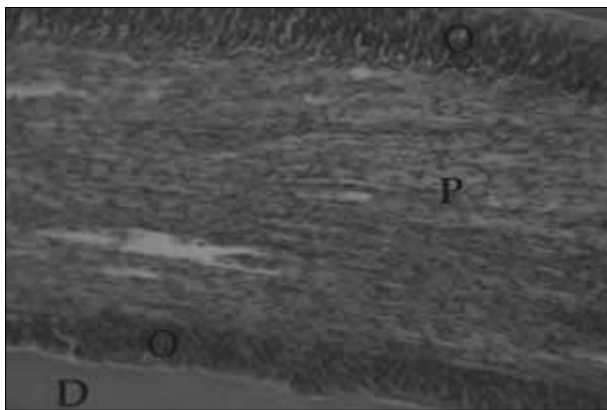
In the experimental group where ANA Liner was used, hyperemia was noticed in just one case (Figure 4), whereas pulp of other teeth was without inflammation (Figure 5). In the experimental group where Fuji II LC was used as liner, pulp inflammation was also registered in just one case (Figure 6), while the pulp of other teeth in this group was not inflamed (Figure 7).

There was no statistically significant difference between the tested materials.

## DISCUSSION

Experimental research was carried out with rabbits. The choice of this experimental model was influenced by a review of literature dealing with this issue [11, 12, 13]. A large number of researchers point out the advantages of rodents, primarily rabbits, in studies of this type [14-17].

These animals meet international standards for dental research, and they are suitable for the experiments because of the fact that they are docile, nonaggressive, easily available and very cost-effective compared to larger animals. Rabbits have a short life cycle and fast metabolism and belong to the category of small animals; for that reason a special permission for the implementation of the research is not required. Their position in the phylogenetic development of the species makes them suitable for inference to what can be expected in humans [16]. The main disadvantage of this choice is that the experimental animals have very small teeth with open apex and incisors that grow constantly [13]. In this study, these deficiencies did not constitute a problem because the main goal of was to investigate the short-term response to pulp irritation. All the animals before and during the experiment were exposed to identical conditions. While selecting anesthetic agents and protocols for euthanasia of animals we used the standards for this type of research [10, 11, 13]. All phases of the study were performed in accordance with the rules and regulations for the keeping of experimental animals. This study investigated the effect of commonly used materials used for the protection of pulp-dentine complex in case of *caries profunda*. Calcimol LC is predominantly composed of a mixture of monomers, while the highest percentage is




**Figure 1.** Histological image of the pulp (control group) without inflammatory reaction (HE, magnification 400x)

D – dentin; O – odontoblasts; P – pulp tissue




**Figure 3.** Histological image of the pulp with signs of hyperemia and vasodilation (Calcimol LC group), (HE, magnification 200x)

D – dentin; O – odontoblasts; P – pulp tissue




**Figure 2.** Histological image of the pulp without inflammatory reaction (Calcimol LC group), (HE, magnification 200x)

D – dentin; O – odontoblasts; P – pulp tissue



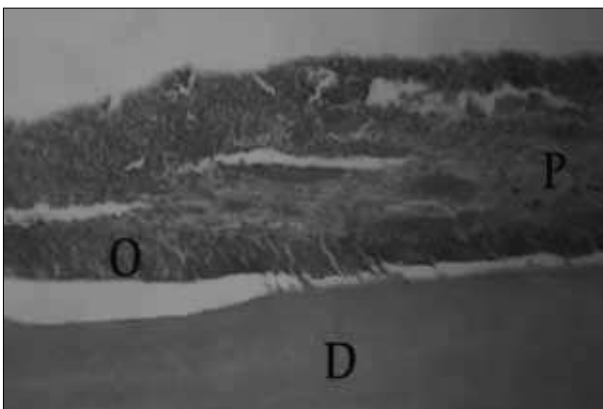
**Figure 4.** Histological image of the pulp with signs of hyperemia and vasodilation (ANA Liner group), (HE, magnification 200x)

D – dentin; O – odontoblasts; P – pulp tissue



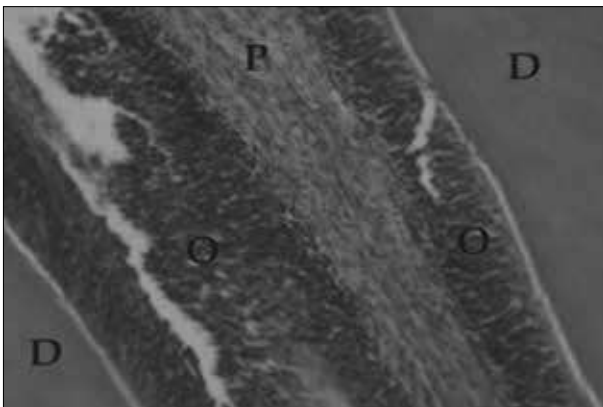
**Figure 5.** Histological image of the pulp without inflammatory reaction (ANA Liner group), (HE, magnification 200×)

D – dentin; O – odontoblasts; P – pulp tissue



**Figure 6.** Histological image of the pulp with signs of hyperemia and vasodilation (Fuji II LC group), (HE, magnification 200×)

D – dentin; O – odontoblasts; P – pulp tissue



**Figure 7.** Histological image of the pulp without inflammatory reaction (Fuji II LC group), (HE, magnification 400×)

D – dentin; O – odontoblasts; P – pulp tissue

UDMA (25–50%). A large part of the material is monomer, and to a lesser extent, butylhydroxytoluene (BHT) and dimethylaminoethylmethacrylate (DMAEMA). Calcium hydroxide makes 2.5–5% of the material. UDMA and TEGDMA are integral parts of the organic components of dental composite materials, and with BisGMA are most responsible for the polymerization shrinkage of composites. ANA Liner is polyacid modified composite resin, compomer. Mechanical properties of compomer are superior

to GIC (and its mechanical properties are not as good as those of composites) while inferior in terms of the GIC fluoride release, biocompatibility and the possibility of adhesion to hard dental tissue [18, 19, 20]. ANA Liner consists of monomers identical to those of the composite (BisGMA 8% and TEGDMA 6%). This system is filled with inert inorganic filler, such as quartz or a silicate glass, while the particles are silanized. Reactive particles of glass which release fluoride are an integral part of the ionomer, in much smaller quantities. Fuji II LC Improved is modified glass-ionomer cement, which means it has good adhesion and chemical bonding with the enamel and dentin substance [1]. This is considerably different compared to the other two liners used in this study, because the Calcimol LC and ANA Liner are characterized with solely micromechanical bond to tooth structure. GIC consists of powder and liquid, where the powder is fluoroaluminosilicate glass, which presents a base component of the material. Liquid component is polyacrylic acid. To solve the problem of sensitivity to water imbalance, the composition of Fuji II LC includes a certain amount of HEMA (less than 5%). Few *in vivo* studies have observed unbiological risks in the use of materials based on the resin, so the information on the effects of these resins is mainly based on *in vitro* studies [21]. UDMA and TEGDMA change mitochondrial activity of fibroblasts and can induce formation of inflammatory reactions in direct contact with fibroblasts [22]. Detrimental effect of monomers on inflammatory cells, which are common in the pulp tissue, was detected by other authors [23, 24]. Fuji II LC Improved, like all GIC, is considered an extremely biocompatible material. This can be explained by the fact that the polyacrylic acid, which makes up the most of liquid component, is a tenuous acid. Polymer chains are long, interconnected and intertwined, with very high molecular weight, which prevents them from migrating through the tubules and prevent harmful effects on the pulp. Nicholson pointed out the problem of GIC that is caused by light-curable component of these materials, and that they can not be held to the same extent as conventional biocompatible cements [25]. Cytotoxicity of HEMA has been documented in numerous studies [26, 27, 28]. They have proven that HEMA is released from all kinds of ionomer. However, the amounts of HEMA, which is an integral part of the ionomer, are much smaller than the amount that can be found within the compomer and dentin adhesives. Extensive researches on the reaction of the pulp to GIC, performed in the last few years, have confirmed the hypothesis that GIC is a biocompatible material [29]. This study includes experiment performed *in vivo* in experimental animals and humans. Some authors compare these results with the results of application of calcium hydroxide cement. The results of this research are consistent with findings of other authors who investigated the biocompatibility of liners [29, 30]. Number of teeth with hyperemia (one tooth in each group) does not indicate a direct link between the application of liners and the development of hyperemia. A possible reason for the occurrence of hyperemia is restorative procedure or cavity preparation itself.

## CONCLUSION

Histological analyses of the dental pulp of experimental animals suggest that the liners used in this study do not

compromise the integrity of the odontoblastic layer, if it is applied over a thin layer of dentin. In each group of tested materials one tooth with mild signs of hyperemia and vasodilation is registered.

## REFERENCES

- Mount GJ, Hume WR. Preservation and Restoration of Tooth Structure. London, Philadelphia: Mosby International Ltd; 1998.
- Mjör IA. Biologija pulpe i dentina u restaurativnoj stomatologiji. Beograd: Data Status; 2008.
- Nakamura M, Inoue T, Shimono M. Immunohistochemical study of the dental pulp applied with 4-META/MMA-TBB adhesive resin after pulpotomy. *J Biomed Mater Res.* 2000; 51:241-8.
- Polydorou O, König A, Hellwig E, Kümmerer K. Long-term release of monomers from modern dental-composite materials. *Eur J Oral Sci.* 2009; 117:68-75.
- Manchorova-Veleva NA. Postoperative tooth sensitivity in type I and II composite obturations (questionnaire survey, computer, biomechanical and clinical studies). *Folia Medica.* 2009; 52:1.
- Perdigao J, Geraldeli S, Hodges JS. Total-etch versus self-etch adhesive: effect on postoperative sensitivity. *J Am Dent Assoc.* 2003; 134:1621-9.
- Manojlović D, Županjac S, Živković S. Mogućnost prevencije postoperativne osetljivosti u zuba restaurisanih kompozitnim ispunima. *Stomatološki glasnik Srbije.* 2007; 54:81-4.
- Weiner R. Liners and bases in general dentistry. *Aust Dent J.* 2011; 56(Suppl 1):11-22.
- Prime&Bond NT. Instructions for use – Material safety data sheets – Science information. Available from: <https://www.dentsply.co.uk/Products/Restorative/Bonds/PrimeBond-NT.aspx>.
- Eversole LR, Rizoiu I, Kimmel AI. Pulpal response to cavity preparation by an erbium, chromium:YSGG laser-powered hydrokinetic system. *J Am Dent Assoc.* 1997; 128(8):1099-106.
- Bourne D. Medetomidine – Ketamine Anaesthesia in Rabbits (Disease Investigation & Management – Treatment and Care). Available from: [http://wildpro.twycrosszoo.org/S/00Man/VeterinaryTechniques/Indiv\\_TechniquesRabbit/MedetomidineKetamineRabbit.htm](http://wildpro.twycrosszoo.org/S/00Man/VeterinaryTechniques/Indiv_TechniquesRabbit/MedetomidineKetamineRabbit.htm).
- Meredith A. Rabbit dentistry. *EJCAP.* 2007; 17(1):55-62; Available from: [http://www.medirabbit.com/EN/Dental\\_diseases/Differential/Rabbit\\_dentistry.pdf](http://www.medirabbit.com/EN/Dental_diseases/Differential/Rabbit_dentistry.pdf).
- Redrobe S. Rabbit and rodent dentistry. Available from: <http://www.redrobe.com/sharon/rabbitdentistry.html>.
- Ahmad I. Protocols for Predictable Aesthetic Dental Restorations. Oxford, UK: Wiley-Blackwell Publishing Ltd; 2006.
- Anusavice K. Phillip's Science of Dental Materials. 11th ed. Philadelphia: WB Saunders; 2003.
- Craig RG, Powers JM. Restorative Dental Materials. 11th ed. St. Louis, London: Mosby Inc; 2002.
- Verstraete FJM, Osofsky A. Dentistry in pet rabbits. *Comp Cont Educ Pract Vet.* 2005; 27:671-84.
- Craig RG. Restorative Dental Materials. 10th ed. St. Louis: Mosby Inc; 2002.
- Jerolimov V. et al. Osnove stomatoloških materijala. Zagreb: Stomatološki fakultet Sveučilišta u Zagrebu; 2005.
- McCabe JF, Walls AWG. Applied Dental Materials. 9th ed. Oxford, UK: Blackwell Publishing Ltd; 2008.
- Bouillaguet S. Biological risks of resin-based materials to the dentin-pulp complex. *Crit Rev Oral Biol Med.* 2004; 15(1):47-60.
- Ratanasathien S, Wataha JC, Hanks CT, Dennison JB. Cytotoxic interactive effects of dentin bonding components on mouse fibroblasts. *J Dent Res.* 1995; 74:1602-6.
- Rakich DR, Wataha JC, Lefebvre CA, Weller RN. Effect of dentin bonding agents on the secretion of inflammatory mediators from macrophages. *J Endod.* 1999; 25:114-7.
- Noda M, Wataha JC, Lockwood PE, Volkmann KR, Kaga M, Sano H. Sublethal, 2-week exposures of dental material components alter TNF-alpha secretion of THP-1 monocytes. *Dent Mater.* 2003; 19:101-5.
- Nicholson JW, Czarnecka B. The biocompatibility of resin-modified glass-ionomer cements for dentistry. *Dent Mater.* 2008; 24(12):1702-8.
- Hamid A, Sutton W, Hume WR. Variation in phosphoric acid concentration and treatment time and HEMA diffusion through dentin. *Am J Dent.* 1996; 9:211-4.
- Hamid A, Okamoto A, Iwaku M, Hume WR. Component release from light-activated glass ionomer and compomer cements. *J Oral Rehabil.* 1998; 25(2):94-9.
- Kawai K, Takaoka T. Fluoride, hydrogen ion and HEMA release from light-cured GIC restoratives. *Am J Dent.* 2002; 15(3):149-52.
- Murray PE, Hafez AA, Smith AJ, Cox CF. Bacterial microleakage and pulp inflammation associated with various restorative materials. *Dent Mater.* 2002; 18(6):470-8.
- Sideridou ID, Achilias DS. Elution study of unreacted Bis-GMA, TEGDMA, UDMA, and Bis-EMA from light-cured dental resins and resin composites using HPLC. *J Biomed Mater Res B Appl Biomater.* 2005; 74(1):617-26.

## Утицај лајнера на запаљење зубне пулпе

Ладо Давидовић<sup>1</sup>, Мирјана Ђук<sup>2</sup>, Марија Живковић Сандић<sup>3</sup>, Ђурица Грга<sup>4</sup>, Славољуб Живковић<sup>4</sup>

<sup>1</sup>Универзитет у Источном Сарајеву, Медицински факултет Фоча, Катедра за болести зуба, Фоча, Босна и Херцеговина;

<sup>2</sup>Универзитет у Источном Сарајеву, Медицински факултет Фоча, Катедра за патологију, Фоча, Босна и Херцеговина;

<sup>3</sup>Универзитет у Београду, Стоматолошки факултет, Катедра за ортодонцију, Београд, Србија;

<sup>4</sup>Универзитет у Београду, Стоматолошки факултет, Катедра за болести зуба, Београд, Србија

### КРАТАК САДРЖАЈ

**Увод** Испитивање је обухватило примену лајнера и композитног материјала у кавитете интактних зуба шест експерименталних животиња – кунића.

**Циљ рада** Циљ истраживања је био да се провери утицај различитих лајнера на настанак и степен запаљења пулпе након примене у кавитете зуба кунића.

**Методе рада** Код сваке животиње су урађене препарације V класе на два горња централна секутића и на једном доњем секутићу, док је други доњи секутић служио као контролни зуб. У препарисане кавитете су апликовани материјали који су индиковани за примену код дубоких кавитета непосредно пре постављања композитних рестаурација на зубима: *Calcimol LC*, *ANA Liner* и *Fuji II LC improved*. Сви кавитети су рестаурисани композитним материјалом *Ceram X-mono*. После опсервационог периода од пет дана животиње су жртвоване и припремљене за хистопатолошку анализу.

**Резултати** Светлосном микроскопијом анализирани су постојање и степен запаљења у зубној пулпи. Резултати су показали да коришћени лајнери не нарушавају структуру и континуитет одонтбластног слоја. На зубима контролне групе није уочено запаљење, док је код тестираних материјала у свакој групи забележен један зуб са благим знацима хиперемije. Добијени резултати су показали да су сва три испитана лајнера повољно утицала на пулпу зуба и након апликације нису довели до запаљењских реакција у пулпи.

**Закључак** Хистолошка анализа зубне пулпе експерименталних животиња је показала да лајнери коришћени у овом истраживању не нарушавају интегритет одонтбласта експерименталних животиња уколико се наносе преко танког слоја дентина. Утврђено је само постојање благе хиперемije и вазодилатације у по једном узорку пулпе зуба заштићених тестираним лајнерима.

**Кључне речи:** лајнери; пулпа; зуби; зечеви

Примљен • Received: 23/06/2014

Прихваћен • Accepted: 18/09/2014