

UDC: 616.314.1-002:577.112

DOI: 10.2298/SGS1401007P

The Concentration of Tumor Necrosis Factor Alpha in Periapical Lesions

Jelena Popović¹, Tatjana Cvetković², Tanja Džopalić³, Aleksandar Mitić¹, Marija Nikolić¹, Radomir Barac¹, Slavoljub Živković⁴

¹Department for Restorative Dentistry and Endodontics, Department of Dentistry, Faculty of Medicine, University of Niš, Niš, Serbia;

²Institute of Biochemistry, Faculty of Medicine, University of Niš, Niš, Serbia;

³Institute of Immunology, Faculty of Medicine, University of Niš, Niš, Serbia;

⁴Department of Restorative Odontology and Endodontics, School of Dental Medicine, University of Belgrade, Belgrade, Serbia

SUMMARY

Introduction The balance between proinflammatory and anti-inflammatory cytokines plays an important role in the pathogenesis of chronic periapical lesions. The aim of this study was to determine the concentration of TNF- α in tissue homogenates of periapical lesions and analyze its levels in relation to the symptomatology and the size of lesions.

Materials and Methods 93 samples of chronic periapical lesions were obtained after extraction of teeth. Samples were classified according to the clinical presentation as symptomatic and asymptomatic, and according to the size as large and small. The concentration of TNF- α was analyzed using ELISA.

Results The results showed increased production of TNF- α in symptomatic lesions compared to asymptomatic. Higher concentration of TNF- α was demonstrated in large lesions compared to small. Large symptomatic lesions showed greater concentration of TNF- α compared to small symptomatic lesions, while bigger asymptomatic lesions demonstrated higher amount of the cytokines compared to small asymptomatic lesions.

Conclusion Higher concentration of TNF- α in large symptomatic lesions indicates that TNF- α is an important factor responsible for the progression of lesions.

Keywords: periapical lesions; cytokines; TNF- α ; symptomatic; asymptomatic

INTRODUCTION

Periapical lesions represent inflammatory and immune diseases affecting periapical tissue and surrounding bone. These periapical processes are primarily caused by bacterial infection of the root canal. Their existence, progression to chronic lesions and destruction of bony structures are the result of host defense inability to eliminate infection [1, 2].

Cytokine network plays an important role in specific and non-specific immune responses. A number of studies have investigated cytokine production in periapical lesions at the level of gene expression, in tissue homogenate or cell cultures and have found that in some cases the balance between pro-inflammatory and immunoregulatory cytokines is disrupted [3, 4].

Tumor necrosis factor α (TNF- α) plays an important role in the initiation and coordination of cellular events in the response of immune system to infection. It is a soluble mediator released by immune cells in the process of inflammation. It is produced mainly by macrophages, as well as lymphoid cells, mastocysts, endothelial cells, myocytes, adipocytes, fibroblasts and neural tissue. Large amounts of TNF- α are released under the influ-

ence of lipopolysaccharide and other bacterial products and interleukin-1 (IL-1) [5, 6]. TNF is the only molecule, beside IL-1 that can activate osteoclasts. It induces calcium release from bone *in vitro* and may play a role in various stages of inflammatory diseases including bone resorption. The presence of TNF- α has been shown in human periapical lesions and exudates from root canals with apical periodontitis [6, 7, 8].

The aim of this study was to determine the concentration of TNF- α in the tissue homogenates of periapical lesions and analyze its levels in relation to the symptomatology and the size of lesions.

MATERIAL AND METHODS

The study involved 93 patients from the Dental Clinic, Faculty of Medicine, Nis, who had diagnosed chronic periapical lesions using clinical and radiographic methods. Periapical lesions were collected from teeth that were determined as non treatable and extracted. Other inclusion criteria were healthy patients not suffering from acute or chronic diseases that could lead to immunodeficiency,

Table 1. Periapical lesions according to symptomatology and size
Tabela 1. Podela ispitivanih lezija u grupe prema simptomatologiji i veličini

Lesions Lezije		Size Veličina		Total Ukupno
		Large Velike	Small Male	
Symptomatology Simptomatologija	Symptomatic Simptomatske	23	23	46
	Asymptomatic Asimptomatske	23	24	47
Total Ukupno		46	47	93

who were not taking antibiotics and anti-inflammatory medications previous two months. Only teeth with periapical lesions which did not show moderate or severe form of marginal periodontitis were included in the study.

According to subjective symptoms lesions were divided into two groups- symptomatic and asymptomatic. Clinically symptomatic lesions were characterized by swelling, pain, discomfort when chewing or sensitivity to percussion and palpation whereas asymptomatic lesions showed no symptoms. The size of periapical lesions was measured in millimeters using a ruler and divided into two groups: small (≤ 5 mm) and large (≥ 6 mm) (Table 1). Since periapical lesions contain granulomatous inflammatory tissue that replaces normal bone there was no equivalent tissue that could be used as negative control.

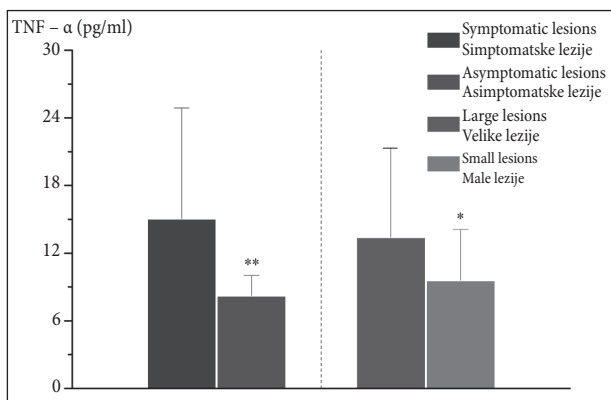
Before administering local anesthetics, teeth, gingiva and mucosa around the tooth were cleaned using 0.12% chlorhexidine and a patient rinsed mouth with 0.12% chlorhexidine for 30 seconds. Samples of periapical lesions removed from the root apex were collected immediately after the extraction using sterile scalpel, then washed in sterile saline, dried using sterile cotton, placed in a sterile plastic Eppendorf tubes and frozen at -70°C . Using teflon crusher in an iced phosphate buffer at pH 7.4 samples were homogenized with volume adapted to weight of the tissue obtaining the final concentration of 10%. Larger debris was sedimented by centrifugation at 1400 rpm for 1 minute at -40°C . The supernatant was frozen at -70°C until further analysis was performed.

The concentration of TNF- α was measured using ELISA test (R&D Systems Inc. Minneapolis, USA) according to the manufacturer's instructions. The sensitivity of ELISA test for TNF- α was from 0.5 to 5.5 pg/ml and the concentration of cytokines was analyzed in relation to the size and symptomatology of periapical lesions.

Statistical analysis was performed using the Mann-Whitney Rank Sum test using software Sigmatat and Origin. The results were expressed as mean \pm standard deviation. $P < 0.05$ was considered as statistically significant.

RESULTS

TNF- α was present in all analysed periapical lesions in significant concentrations. Graph 1 shows the concentrations of TNF- α in all samples, and the average values were analyzed with respect to the size and symptomatology. In the group of symptomatic lesions the average concentra-

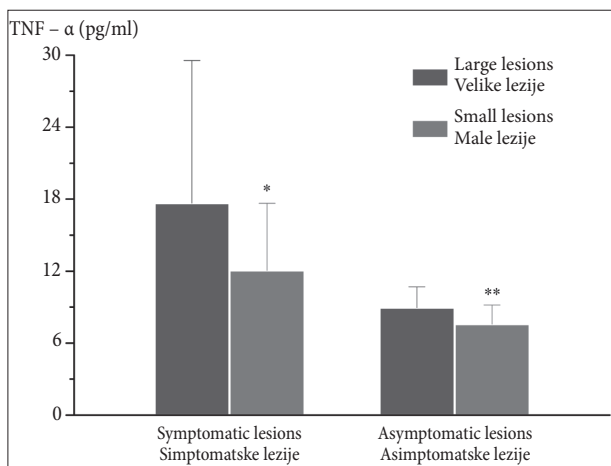


Graph 1. TNF- α concentration in tissue homogenates of periapical lesions in relation to symptomatology and size

Grafikon 1. Koncentracija TNF- α u homogenatu tkiva periapikalnih lezija u odnosu na njihovu simptomatologiju i veličinu

* $p < 0.01$ vs. large lesions; ** $p < 0.001$ vs. symptomatic lesions

* $p < 0.01$ u odnosu na velike lezije; ** $p < 0.001$ u odnosu na simptomatske lezije



Graph 2. TNF- α concentration of symptomatic and asymptomatic periapical lesions

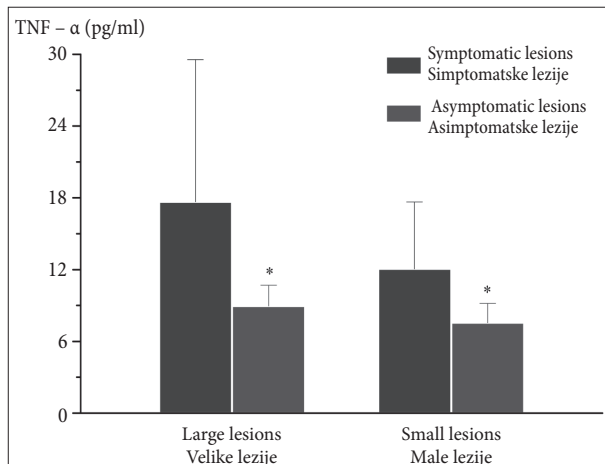
Grafikon 2. Koncentracija TNF- α u okviru grupa simptomatskih i asimptomatskih lezija

* $p < 0.05$ vs. large lesions; ** $p < 0.01$ vs. large lesions

* $p < 0.05$ u odnosu na velike lezije; ** $p < 0.01$ u odnosu na velike lezije

tion was 15.08 pg/ml while in the group of asymptomatic lesions the average value was 8.24 pg/ml. There was a statistically significant difference in the concentration of TNF- α between symptomatic and asymptomatic lesions ($p < 0.001$). In the group of large lesions the average TNF- α concentration was 13.24 pg/ml whereas in the group of small lesions the average value was 9.61 pg/ml. There was a statistically significant difference between TNF- α concentrations in large and small lesions ($p < 0.01$).

Graph 2 shows the mean values of TNF- α within the groups of symptomatic and asymptomatic lesions. In the group of symptomatic lesions, the average concentration of TNF- α was analyzed in large and small lesions. The average concentration of TNF- α in symptomatic large lesions was 17.67 pg/ml, while in small symptomatic lesions it was 12.07 pg/ml. The analysis of the average values showed significantly higher concentrations of TNF- α in symptomatic large lesions ($p < 0.05$). Also, in the group of asymptomatic lesions there was statistically significant



Graph 3. TNF- α concentration of large and small periapical lesions
Grafikon 3. Koncentracija TNF- α u okviru grupa velikih i malih lezija

* $p < 0.001$ vs. symptomatic lesions

* $p < 0.001$ u odnosu na simptomatske lezije

difference in the concentrations of TNF- α in relation to the size of lesions. The average concentration of TNF- α in asymptomatic large lesions was 8.96 pg/ml, while it was 7.58 pg/ml in asymptomatic small lesions ($p < 0.01$).

Graph 3 shows the concentration of TNF- α within the groups of large and small lesions where statistical significance was analyzed in relation to the symptomatology. The analysis showed statistically significant difference in the concentration of TNF- α in large symptomatic lesions (17.67 pg/ml) compared to large asymptomatic lesions (8.96 pg/ml) ($p < 0.001$). Statistically significant difference was noticed in small lesions where the concentration of TNF- α in small symptomatic lesions was 12.07 pg/ml, while it was 7.58 pg/ml in small asymptomatic lesions ($p < 0.001$).

DISCUSSION

Host response to antigen stimulation in chronic inflammatory processes is mainly controlled by the balance between proinflammatory and anti-inflammatory cytokines. While proinflammatory cytokines, such as IL-1, IL-6, TNF- α , TNF- β , chemokines and Th1 cytokines promote inflammation in the periapical tissue and activate osteoclastic bone resorption [1, 2], the role of anti-inflammatory cytokines is important for the suppression of inflammatory processes and beginning of healing process [3, 9, 10]. This specific role of cytokines was studied in the research of Gazivoda et al. [4] which showed that inflammatory cells from periapical lesions produced significant levels of pro-inflammatory (IL-1 β , IL-6, IL-8 and TNF- α) and immunoregulatory (IL-10 and TGF- β) cytokines *in vitro*. The authors investigated whether the production of cytokines was associated with clinical symptoms and the composition of infiltrating cells. In accordance with previous results [10,11] they found that symptomatic lesions contained higher portion of neutrophils. The recruitment of granulocytes in these lesions was probably caused by re-infection of the root canal space and further reactivation of chronic periapical process [1, 2]. Granulocytes present together with activated and infiltrating macro-

phages produce a number of soluble mediators, including proinflammatory cytokines [12].

IL-1, predominantly produced by mononuclear phagocytes, polymorphonuclear leukocytes and connective tissue cells in periapical lesions, has been considered as primary stimulator of periapical bone destruction [9, 13, 14, 15]. Production of IL-1 in periapical lesions is regulated by cytokines originating from Th1 cells, such as interferon gamma (IFN- γ). IFN- γ as a potent activator of macrophages, stimulates the expression of IL-1 and TNF- α by these cells. TNF- α induces the production of IL-1 whereas IL-1 alone stimulates its own synthesis by positive feedback mechanism [2].

The current study analyzed the concentration of proinflammatory cytokine TNF- α in the tissue homogenates of chronic periapical lesions in relation to the symptoms and the size of the lesions. Results demonstrated that the level of TNF- α was significantly higher in symptomatic lesions compared to asymptomatic and in large lesions compared to small. Therefore, TNF- α can be considered responsible for mediation of development and progression of periapical lesions. The research of Gazivoda et al. [4] showed no significant difference in the level of TNF- α between symptomatic and asymptomatic lesions. According to their study, increased secretion of TNF- α in large lesions may be associated with a different composition of infiltrating cells. Danin et al. [3] suggested that activated macrophages may be the main source of TNF- α . In contrast, Ma et al. [16] reported decreased numbers of macrophages in large lesions. The reason for this finding is not clear, however, the study of Artese et al. [7] showed that although 41% of mononuclear cells in periapical lesions are macrophages, only 2-3% of them produced IL-1 β and TNF- α . Danin et al. [3] found significant levels of TNF- α in only two patients with periapical lesions out of 25 while Safavi and Rossomando [6] and Pezelj-Ribarić et al. [17] found TNF- α in all samples of periapical exudates. Brekalo-Pršo et al. in their study [5] demonstrated high concentrations of TNF- α in all symptomatic and asymptomatic lesions. Slightly higher concentration of TNF- α was observed in symptomatic lesions but the difference was not statistically significant. Such differences may occur due to the different state of activating macrophages depending on the clinical case but also as a result of different origin of produced cytokines due to various experimental approaches (tissue extracts or culture supernatants of inflammatory cells).

CONCLUSION

Symptomatic lesions showed increased production of TNF- α compared to asymptomatic. Higher concentration of TNF- α was demonstrated in large lesions compared to small. Large symptomatic lesions showed greater concentration of TNF- α than small symptomatic lesions and large asymptomatic lesions showed higher concentration of cytokines compared to asymptomatic small lesions. Based on these results it can be concluded that TNF- α is an important factor responsible for the progression of periapical lesions.

REFERENCES

1. Márton IJ, Kiss C. Protective and destructive immune reactions in apical periodontitis. *Oral Microbiol Immunol.* 2000; 15:139-50.
2. Nair PNR. Pathogenesis of apical periodontitis and the causes of endodontic failures. *Crit Rev Oral Biol Med.* 2004; 15:348-81.
3. Danin J, Linder LE, Lundqvist G, Andersson L. Tumor necrosis factor-alpha and transforming growth factor-beta₁ in chronic periapical lesions. *Oral Surg Oral Med Oral Pathol Oral Radiol Endod.* 2000; 90:514-7.
4. Gazivoda D, Dzopalic T, Bozic B, Tatomirovic Z, Brkic Z, Colic M. Production of proinflammatory and immunoregulatory cytokines by inflammatory cells from periapical lesions in culture. *J Oral Pathol Med.* 2009; 38:605-11.
5. Brekalo Pršo I, Kocjan W, Šimić H, Brumini G, Pezelj-Ribarić S, Borčić J, et al. Tumor necrosis factor-alpha and interleukin 6 in human periapical lesions. *Mediators Inflamm.* 2007; 2007:38210.
6. Safavi KE, Rossomando EF. Tumor necrosis factor identified in periapical tissue exudates of teeth with apical periodontitis. *J Endod.* 1991; 17:12-4.
7. Artese L, Piattelli A, Quaranta M, Colasante A, Musani P. Immunoreactivity for interleukin 1 β and tumor necrosis factor- α and ultrastructural features of monocytes/macrophages in periapical granulomas. *J Endod.* 1991; 17:483-7.
8. Ataoglu T, Üngör M, Serpek B, Haliloglu S, Ataoglu H, Ari H. Interleukin-1 β and tumor necrosis factor- α levels in periapical exudates. *Int Endod J.* 2002; 35:181-5.
9. Kawashima N, Stashenko P. Expression of bone-resorpting and regulatory cytokines in murine periapical inflammation. *Arch Oral Biol.* 1999; 44:55-66.
10. Čolić M, Gazivoda D, Vučičević D, Vasilijić S, Rudolf R, Lukić A. Proinflammatory and immunoregulatory mechanisms in periapical lesions. *Mol Immunol.* 2009; 47:101-13.
11. Čolić M, Vasilijić S, Gazivoda D, Vučević D, Marjanović M, Lukić A. Interleukin-17 plays a role in exacerbation of inflammation within chronic periapical lesions. *Eur J Oral Sci.* 2007; 115:315-20.
12. Dinarello C. Proinflammatory cytokines. *Chest.* 2000; 118:503-8.
13. Wang CY, Stashenko P. The role of interleukin-1 α in the pathogenesis of periapical bone destruction in a rat model system. *J Oral Microbiol.* 1993; 8:50-6.
14. Tani-Ishii N, Wang CY, Stashenko P. Immunolocalization of bone-resorptive cytokines in rat pulp and periapical lesions following surgical pulp exposure. *J Oral Microbiol Immunol.* 1995; 10:213-9.
15. Wang CY, Tani-Ishii N, Stashenko P. Bone-resorptive cytokine gene expression in periapical lesions in the rat. *Oral Microbiol Immunol.* 1997; 12:65-71.
16. Ma J, Chen T, Mandelin J, Ceponis A, Miller NE, Hukkanen M, et al. Regulation of macrophage activation. *Cell Mol Life Sci.* 2003; 60:2334-46.
17. Pezelj-Ribarić S, Magašić K, Prpić J, Miletić I, Karlović Z. Tumor necrosis factor-alpha in periapical tissue exudates of teeth with apical periodontitis. *Mediators Inflamm.* 2007; 2007:69416.

Received: 01/11/2013 • Accepted: 10/01/2014

Ispitivanje koncentracije faktora nekroze tumora alfa u tkivnim homogenatima periapeksnih lezija

Jelena Popović¹, Tatjana Cvetković², Tanja Džopalić³, Aleksandar Mitić¹, Marija Nikolić¹, Radomir Barac¹, Slavoljub Živković⁴

¹Odeljenje za bolesti zuba i endodonciju, Klinika za stomatologiju, Medicinski fakultet, Univerzitet u Nišu, Niš, Srbija;

²Institut za biohemiju, Medicinski fakultet, Univerzitet u Nišu, Niš, Srbija;

³Institut za imunologiju, Medicinski fakultet, Univerzitet u Nišu, Niš, Srbija;

⁴Klinika za bolesti zuba, Stomatološki fakultet, Univerzitet u Beogradu, Beograd, Srbija

KRATAK SADRŽAJ

Uvod Balans između proinflamatornih i antiinflamatornih citokina igra važnu ulogu u patogenezi hroničnih periapeksnih lezija. Cilj ove studije je bio da se odredi koncentracija faktora nekroze tumora alfa (TNF- α) u homogenatima tkiva periapeksnih lezija i rezultati analiziraju u pogledu simptomatologije tih lezija kod pacijenata, odnosno veličine lezije.

Materijal i metode rada Ispitana su 93 uzorka hroničnih periapeksnih lezija dobijenih nakon ekstrakcije zuba. Uzorci lezija su, prema simptomatologiji pacijenata, podeljeni na simptomatske i asimptomatske, a prema veličini na velike i male. Koncentracija TNF- α u uzorku ispitivana je pomoću testa ELISA.

Rezultati Kod klinički simptomatskih lezija uočeno je povećano stvaranje TNF- α u odnosu na asimptomatske. Veća koncentracija TNF- α je dokazana i u velikim lezijama u odnosu na male. Velike simptomatske lezije su pokazale veću koncentraciju TNF- α u odnosu na male simptomatske lezije, dok su velike asimptomatske lezije imale veću količinu ovog citokina u odnosu na male asimptomatske lezije.

Zaključak Veća koncentracija TNF- α u velikim i u lezijama s pojačanim kliničkim simptomima pokazuje da je TNF- α važan faktor odgovoran za napredovanje lezije.

Ključne reči: periapeksne lezije; citokini; TNF- α ; simptomatska; asimptomatska

UVOD

Periapeksne lezije su inflamatorno-imunska oboljenja koja zahvataju periapeksna tkiva i okolnu kost. Ovakvi periradiksni procesi su primarno izazvani bakterijskom infekcijom iz kanala korena. Njihovo održavanje, razvoj u hronične lezije i destrukcija koštanih struktura posledica su nemogućnosti mehanizama odbrane domaćina da suzbiju infekciju [1, 2].

Mreža citokina igra značajnu ulogu u specifičnim i nespecifičnim imunskim odgovorima. Mnoge studije su proučavale proizvodnju citokina u periapeksnim lezijama na nivou genske ekspresije, tkivnih homogenata ili u ćelijskim kulturama, te ustanovile da je u određenim uslovima balans između proinflamatornih i imunoregulatornih citokina poremećen [3, 4].

Faktor nekroze tumora alfa (TNF- α) igra važnu ulogu u inicijaciji i koordinaciji ćelijskih događaja i odgovoru imunskog sistema na infekciju. On je solubilni medijator kojeg oslobađaju imunokompetentne ćelije u procesu zapaljenja. Proizvode ga uglavnom makrofagi, ali i limfoidne ćelije, mastociti, endotelne ćelije, miociti, adipociti, fibroblasti i nervno tkivo. Velike količine TNF- α se oslobađaju pod uticajem lipopolisaharida i drugih bakterijskih proizvoda i interleukina 1 (IL-1) [5, 6]. TNF- α je, pored IL-1, jedini molekul koji ima funkciju osteoklastne aktivacije. On indukuje oslobađanje kalcijuma iz kosti *in vitro* i može igrati značajnu ulogu u različitim stadijumima inflamatornih oboljenja, uključujući koštanu resorpciju. Prisustvo TNF- α je dokazano u humanim apeksnim parodontalnim lezijama i eksudatima iz kanala korena zuba s apeksnim parodontitima [6, 7, 8].

Cilj ove studije je bio da se odredi koncentracija TNF- α u homogenatima tkiva periapeksnih lezija i rezultati analiziraju u odnosu na simptomatologiju tih lezija kod pacijenata, odnosno veličinu lezije.

MATERIJAL I METODE RADA

U istraživanje su uključena 93 pacijenta Klinike za stomatologiju Medicinskog fakulteta Univerziteta u Nišu kod kojih je kliničkim i radiografskim metodama postavljena dijagnoza hronične periapeksne lezije. Periapeksne lezije su uzimane sa korenova zuba koji su zbog nemogućnosti lečenja indikovani za ekstrakciju. Pored periapeksne lezije, uslov za uključivanje pacijenata u studiju bio je da ne boluju od akutnih ili hroničnih oboljenja koja dovode do stanja imunodeficijencije i da u prethodna dva meseca nisu uzimali antibiotsku i antiinflamatornu terapiju. U istraživanje su uključivane periapeksne lezije onih zuba koji nisu pokazivali umeren ili težak oblik marginalnog parodontitisa.

Ispitivane lezije su podeljene u dve grupe prema subjektivnim simptomima pacijenata: simptomatske i asimptomatske lezije. Klinički su se simptomatske lezije odlikovale otokom, bolom, nelagodnošću pri žvakanju ili osetljivošću na perkusiju i palpaciju, dok asimptomatske lezije nisu pokazivale znake ili simptome u vreme studije. Periapeksne lezije su merene milimetarskim lenjirom i u odnosu na veličinu svrstane u dve grupe: male (≤ 5 mm) i velike (≥ 6 mm) (Tabela 1). Budući da periapeksne lezije obuhvataju reaktivno tkivo koje se sastoji uglavnom od granulomatoznog inflamatornog tkiva koje zamenjuje normalnu kost, nije postojao pravi tkivni ekvivalent koji bi služio kao negativna kontrola.

Pre primene lokalnog anestetika zubi, gingiva i sluzokoža oko zuba su očišćeni hlorheksidinom u koncentraciji od 0,12%, a pacijent je ispirao usta istim rastvorom 30 sekundi. Uzorci periapeksnih lezija su odmah po ekstrakciji sterilnim skalpelom odstranjeni s vrha korena zuba, isprani u sterilnom fiziološkom rastvoru, prosušeni na sterilnoj vati, stavljeni u sterilnu plastičnu ependorf epruvetu i zamrzavani na -70°C . Homogenizacija

je vršena teflonskim tučkom u ledenom fosfatnom puferu vrednosti pH od 7,4, čija je zapremina prilagođena težini tkiva, tako da finalna koncentracija homogenata iznosi 10%. Krupniji detritus je sedimentiran centrifugiranjem na 1.400 obrtaja tokom jednog minuta na -4°C . Supernatant je nakon toga zamrznut na -70°C do izvođenja odgovarajućih analiza.

Koncentracija TNF- α je određivana ELISA testom (R&D Systems Inc. Mineapolis, SAD) prema uputstvu proizvođača. Senzitivnost testa ELISA za TNF- α bila je 0,5–5,5 pg/ml, a koncentracija citokina je analizirana u pogledu simptomatologije i veličine periapeksnih lezija.

Statistička analiza je urađena pomoću Man–Vitnijevog (*Mann–Whitney*) testa sume rangova korišćenjem programa *Sigmastat* i *Origin*. Rezultati su izražavani u vidu srednje vrednosti sa standardnom devijacijom. Statistički značajnim razlikama su smatrane one koje su bile pri $p < 0,05$.

REZULTATI

Ispitivanje koncentracije TNF- α u tkivu periapeksnih lezija pokazalo je statistički značajnu koncentraciju citokina u svim uzorcima. Na grafikonu 1 prikazana je koncentracija TNF- α kod svih uzoraka, a prosečne vrednosti su analizirane u odnosu na simptomatologiju i veličinu. U grupi simptomatskih lezija prosečna koncentracija je bila 15,08 pg/ml, a u grupi asimptomatskih lezija 8,24 pg/ml. Razlika je bila statistički značajna ($p < 0,001$). U grupi velikih lezija prosečna koncentracija TNF- α je bila 13,24 pg/ml, a u grupi malih 9,61 pg/ml. Razlika je i između ove dve posmatrane grupe uzoraka takođe bila statistički značajna ($p < 0,01$).

Na grafikonu 2 prikazane su prosečne vrednosti koncentracije TNF- α u okviru grupa simptomatskih i asimptomatskih lezija. U grupi simptomatskih lezija analizirana je prosečna koncentracija TNF- α između velikih i malih lezija. Ona je kod velikih lezija bila 17,67 pg/ml, a kod malih 12,07 pg/ml. Razlika je bila statistički značajna ($p < 0,05$). I u grupi asimptomatskih lezija zapažena je statistički značajna razlika u koncentracijama TNF- α u odnosu na veličinu lezija. Prosečna koncentracija TNF- α kod velikih lezija bila je 8,96 pg/ml, a kod malih 7,58 pg/ml ($p < 0,01$).

Na grafikonu 3 prikazana je koncentracija TNF- α u okviru grupa velikih i malih lezija, gde je statistička značajnost analizirana u odnosu na simptomatologiju. Analiza je pokazala statistički značajno veću ($p < 0,001$) koncentraciju TNF- α u velikim simptomatskim lezijama (17,67 pg/ml) u odnosu na velike asimptomatske lezije (8,96 pg/ml). Statistički značajna razlika je uočena i kod malih lezija, gde je kod simptomatskih koncentracija TNF- α bila 12,07 pg/ml, a kod asimptomatskih 7,58 pg/ml ($p < 0,001$).

DISKUSIJA

Balans između proinflamatornih i antiinflamatornih citokina u velikoj meri kontroliše odgovore domaćina na antigenu stimulaciju kod hroničnih zapaljenjskih procesa. Dok proinflamatorni citokini, kao što su IL-1, IL-6, TNF- α , TNF- β , hemokini i Th1 citokini, propagiraju inflamaciju u periapeksnim tkivima

i aktiviraju osteoklastnu resorpciju kosti [1, 2], uloga antiinflamatornih citokina je važna za supresiju inflamatornih procesa i procese zarastanja unutar periapeksnih lezija [3, 9, 10]. Takva uloga citokina je proučavana u studiji Gazivode i saradnika [4], gde je dokazano da inflamatorne ćelije iz periapeksnih lezija stvaraju značajne nivoe proinflamatornih (IL-1 β , IL-6, IL-8 i TNF- α) i imunoregulatornih (IL-10 i TGF- β) citokina *in vitro*. Kao značajne individualne razlike koje su posmatrane, autori su ispitali da li je proizvodnja citokina povezana s kliničkim odlikama lezija i sastavom infiltrirajućih ćelija. U skladu s prethodnim rezultatima [10, 11] uočeno je da simptomatske lezije sadrže veći procenat neutrofilnih granulocita. Regrutovanje granulocita u leziju je verovatno izazvano reinfekcijom iz kanala korena i daljom reaktivacijom hroničnog periapeksnog procesa [1, 2]. Granulociti, zajedno s aktiviranim prisutnim i infiltrirajućim makrofagima, proizvode brojne solubilne medijatore, uključujući proinflamatorne citokine [12].

Kao primarni stimulator periapeksne koštane destrukcije navodi se IL-1 [9, 13], citokin koji predominantno stvaraju mononuklearni fagociti, polimorfonuklearni leukociti i vezivnotkivne ćelije u periapeksnim lezijama [14, 15]. Proizvodnja IL-1 u periapeksnim lezijama je regulisana citokinima koji potiču od Th1 ćelija, kakav je interferon gama (IFN- γ). IFN- γ , kao moćni aktivator makrofaga, reguliše ekspresiju IL-1 i TNF- α od strane ovih ćelija. TNF- α izaziva stvaranje IL-1, dok sam IL-1 stimuliše sopstvenu sintezu mehanizmom pozitivne povratne sprege [2].

U ovom istraživanju analizirane su koncentracije proinflamatornog citokina TNF- α u tkivnim homogenatima hroničnih periapeksnih lezija u odnosu na simptomatologiju i veličinu lezija. Rezultati studije, koji pokazuju da su nivoui TNF- α bili statistički značajno viši u simptomatskim lezijama u odnosu na asimptomatske i u velikim lezijama u odnosu na male, govore da je TNF- α medijator odgovoran za razvoj i napredovanje periapeksnih lezija. U istraživanju Gazivode i saradnika [4] nije uočena značajna razlika u nivou TNF- α između simptomatskih i asimptomatskih lezija. Prema njihovom tumačenju, povećano lučenje TNF- α u velikim lezijama može biti u vezi s različitim sastavom infiltrirajućih ćelija. Prema Daninu (*Danin*) i saradnicima [3], aktivirani makrofagi se smatraju glavnim izvorom TNF- α . Suprotno tome, Ma (*Ma*) i saradnici [16] su objavili da u velikim lezijama ima manje makrofaga. Razlog za takve nalaze nije jasan, ali studija Arzeza (*Artese*) i saradnika [7] je pokazala da, iako 41% mononuklearnih inflamatornih ćelija u periapeksnim lezijama čine makrofagi, samo 2–3% njih proizvodi IL-1 β i TNF- α . Danin i saradnici [3] su pronašli značajne nivoe TNF- α kod samo dva pacijenta od 25 ispitanika s periapeksnim lezijama, dok su Safavi (*Safavi*) i Rosomando (*Rosomando*) [6] i Pezelj-Ribarićeva i saradnici [17] otkrili TNF- α u svim uzorcima periapeksnih eksudata. U istraživanju autorke Brekalo-Pršo i saradnika [5] utvrđene su visoke koncentracije TNF- α u svim simptomatskim i asimptomatskim lezijama. Nešto veća koncentracija je uočena u simptomatskim lezijama, međutim, razlika nije bila statistički značajna. Ovakve razlike mogu nastati usled različitih aktivirajućih stanja makrofaga u zavisnosti od kliničkih situacija, ali i kao rezultat različitog porekla stvorenog citokina zbog različitih eksperimentalnih pristupa (tkivni ekstrakt ili kulturni supernatanti inflamatornih ćelija).

ZAKLJUČAK

Klinički simptomatske lezije se manifestuju povećanom proizvodnjom TNF- α u odnosu na asimptomatske. Veća koncentracija TNF- α je dokazana i u velikim lezijama u odnosu na male. Velike

simptomatske lezije su pokazale veću koncentraciju TNF- α u odnosu na male simptomatske lezije, dok su velike asimptomatske lezije imale veću količinu ovog citokina u odnosu na asimptomatske male lezije. Na osnovu ovakvih rezultata može se zaključiti da je TNF- α važan faktor odgovoran za napredovanje lezije.