

# Praćenje nivoa alveolarne kosti u predelu zadržanih zuba kod pacijenata sa donjom totalnom supradentalnom protezom- desetogodišnja longitudinalna studija

DOI:10.2298/SGS0601017B

## Ten Years Longitudinal Study: Comparison of Abutment Alveolar Bone Levels of Overdenture Patients

Snežana Brković-Popović, Darinka Stanišić-Sinobad, Dragoslav Đukanović, Srdjan Poštić

Klinika za stomatološku protetiku, Stomatološki fakultet u Beogradu  
Clinic for Prosthetic Dentistry, School of Dentistry, BelgradeORIGINALNI RAD (OR)  
ORIGINAL ARTICLE

## KRATAK SADRŽAJ

**Cilj:** Cilj ove studije bio je da se izmere efekti supradentalnih proteza na stanje alveolarne kosti u predelu zadržanih zuba za vreme od 10 godina.

**Materijal i metod:** Nakon pripreme svih zadržanih «patrljaka zuba» u donjoj vilici, načinjene su donje totalne supradentalne proteze za 22 pacijenta. Dentalne radiografije tih zuba su urađene na početku, pri predaji proteza, a zatim 6 i 10 godina nakon predaje. Dentalni rentgenski snimci upoređivani su uz pomoć žičane mrežice i držača rentgen filma koji su pripremljeni za svakog pacijenta i svaki zub individualno čime je bila obezbeđena izrada identično pozicioniranih dentalnih radiografija u različitim vremenskim periodima.

**Rezultati:** Dobijeni rezultati ove studije ukazuju da je postignut maksimalan terapijski efekat u pacijenata sa malim brojem preostalih, parodontloski losih zuba.

**Zaključak:** Dobra oralna higijena je ključ uspeha tretmana supradentalnim protezama.

**Ključne reči:** Alveolarna kost, supradentalna proteza

## SUMMARY

**Aim:** The aim of this study was to evaluate the effects of overdentures on the condition of alveolar bone around the remaining teeth over 10 years.

**Materials and Methods:** After preparation of all the remaining abutment teeth in the lower jaw, overdentures were fabricated for 22 patients. The radiographs were made at the delivery stage, then 6 and 10 years after delivery. The radiographs were evaluated using the grid scale and the film holder made it possible to repeat x-ray procedure in every patient in the same manner.

**Results:** We concluded that we achieved the maximum therapeutic effect. **Conclusion:** Good oral hygiene is the key of success with overdentures.

**Key words:** Alveolar bone, Overdenture

Danas se u svakodnevnoj stomatološkoj praksi u slučajevima maksimalne krezubosti veoma često koriste preostali zubi za poboljšanje retencije mobilnih nadoknada. (1,2,3,4,5,6). Međutim, suština ovde primenjenog koncepta je da su preostali zubi zadržani sa ciljem da čuvaju alveolarnu kost, obezbeđujući time trajniju i stabilniju potporu totalnoj protezi. (7,8,9,10,11). Ovo je od posebnog značaja za donju vilicu gde je problem stabilizovanja totalne proteze veoma čest. S druge strane, neadekvatno i preterano optere-

The last remaining teeth are often used in everyday dental practice to aid in the classical retention of removable dentures overloading remaining abutments. It often results in premature extractions (1,2,3,4,5,6).

However, it is well known that preservations of even hopeless remaining teeth, or tooth roots downgrade the alveolar bone reduction and provide a more stable support of complete dentures (7,8,9,10,11). This is of particular

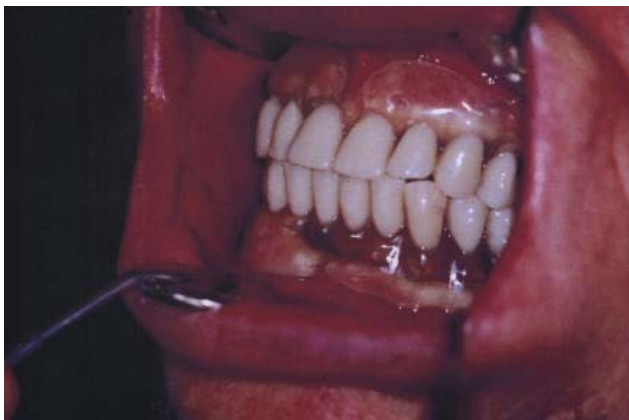ćenje preostalih zuba klasičnim sistemima retencije znatno smanjuje njihov vek i rezultira prevremenim ekstrakcijama.

Zadržavanje poslednjih preostalih zuba i izrada proteze preko njih preporučuju se kod pacijenata kod kojih preostali zubi ne mogu poslužiti kao nosači fiksnih ili drugih mobilnih nadoknada (mali broj preostalih zuba, loš raspored, nepovoljan odnos kruna-koren, odnosno, redukovana alveolarna potpora, početni stepen labavljenja zuba, zubi jako skraćeni abrazijom, pojedinačni devitalizovni zubi ili preostali usamljeni izlečeni korenovi zuba). U ovim slučajevima supradentalna proteza (SDP), izrađena preko izlečenih i konzerviranih korenova zuba je uvek bolja alternativa u odnosu na klasičnu parcijalnu protezu. (12,13,14,15,16,19)

Čuvanje svakog preostalog zuba (korena) posebno je indicirano u slučajevima gde klasični tretman totalnim protezama ne obećava uspeh u pogledu retencije i stabilnosti proteza ( ekstenzivna redukcija rezidualnih grebenova, nerezilijentna pokretna sluzokoža, nepovoljni oblici rezidualnih grebenova, podminirani, oštri, pokretni grebenovi, izrazita nepodudarnost alveolarnih grebenova, veliki interokluzioni prostor). Pažljiva selekcija zuba koji će poslužiti kao potpora supradentalnoj protezi kao i kompletna priprema usta i samog pacijenta za prihvatanje nadoknade predstavljaju ključne momente u sprovođenju tog oblika lečenja i očuvanju njegovih pozitivnih efekata. (17,18).

Ovaj koncept nudi brojne prednosti u protetskoj terapiji maksimalno krezubih pacijenata:

1. prevencija ekstenzivne redukcije alveolarne kosti, (sl.1)
2. obezbeđivanje veće stabilnosti mobilnoj nadoknadi,
3. očuvanje proprioceptivnih svojstava parodontijuma,
4. devitalizovani zubi (korenovi) ispoljavaju osetljivost na okluzalni stimulus kao i oni u vitalnom stanju, a redukovani parodontijum tih zadržanih zuba ispod SDP poseduje značajni proprioceptivni kapacitet.
5. terapija SDP omogućuje u odnosu na terapiju klasičnim parcijalnim protezama smanjen uticaj štetnih horizontalnih sila na zadržane zube što garantuje duži vek tim zubima. (15,19,20,21,22,23,24,25) (sl.2)



Slika 1. Redukcija donjeg alveolarnog grebena u predelu preostalog zuba  
Figure 1. Posterior reduction of mandibular residual ridge with respect to remaining tooth

importance in the lower jaw, because of the very common problem of lower denture stability.

In that respect the idea of this work is that last remaining teeth showed the preserved in order to diminish the alveolar bone reduction.

Preservation of the last remaining teeth and fabrication of overdentures is recommended in patients when the remaining teeth cannot be used as abutments for fixed or removable dentures (small number of remaining teeth, bad alignment, unsatisfactory crown-root ration, reduced alveolar support, the initial state of loosening strongly abraded teeth or remaining treated roots).

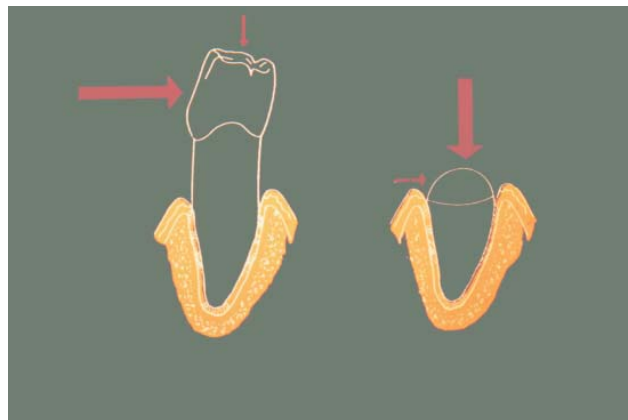
In these cases the overdentures are more beneficial and a better alternative in relation to the classical partial denture (12,13,14,15,16,17).

The preservation of every remaining tooth (root) is particularly indicated in patients when the ordinary complete denture treatment does not promise the successful retention and stability of dentures (the extensive residual ridge reduction, undercut, sharp or flabby ridges, the exenterated incongruence of alveolar ridges, the great interocclusal space).

The careful selection of teeth in supporting the over-denture, complete preparation of the oral cavity and the patient himself are used for the acceptance of the new denture, a cornerstones of this type of treatment and the presentation of its positive effects (17,18).

This concept offers numerous advantages in the prosthetic treatment of patients with maximal tooth lessening (or in patients with a great number of missing teeth):

1. prevents the extensive residual ridge reduction (Fig. 1);
2. provides the better denture stability;
3. prevents the proprioceptive capability of periodontium;
4. the devitalized tooth roots are as sensitive colossal stimulus as vital teeth and their reduced periodontium has a significant proprioceptive capacity;
5. therapy by overdentures in relation to classic acrylic prostheses lays in less danger of harmful horizontal forces effect which guarantees a longer life for the periodontium of the remaining teeth (17,18,19,20,21,22,23,24,25) (Fig. 2).



Slika 2. Umanjeni štetni efekti horizontalnih sila  
Figure 2. Smoler danger of horizontal forces effect

## Cilj

Imajući u vidu značaj zadržanih zuba za funkcionalnu vrednost proteze to je i cilj ovog istraživanja da utvrdi efekte SDP na stanje alveolarne kosti oko zadržanih zuba nakon jednog dužeg vremenskog perioda i na taj način verifikuje vrednost koncepta SDP u protetskom tretmanu krezubih pacijenata.

## Materijal i metod

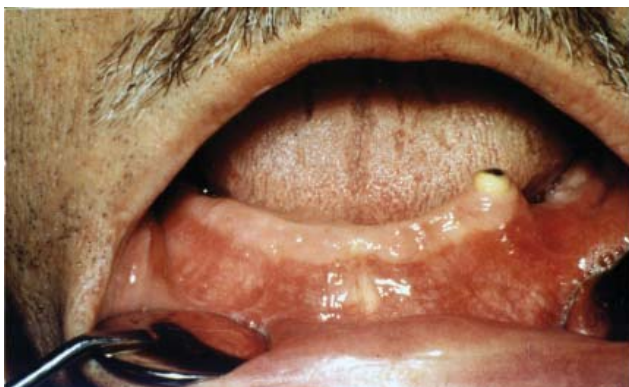Istraživanje je sprovedeno na pacijentima Klinike za Stomatološku protetiku Stomatološkog fakulteta u Beogradu. U opservacionim periodima nakon 6 i 10 godina, uzorak je sačinjavao 22 pacijenta. Posle specifične pripreme (redukcije kliničke krune, endodontske i parodontološke pripreme) svi zadržani zubi su zbrinuti amalgamskim ispunom ili livenim kavicama. Svakom pacijentu je nakon ovakve pripreme urađena donja SDP. (sl.3, sl.4, sl.5, sl.6)

## Aim

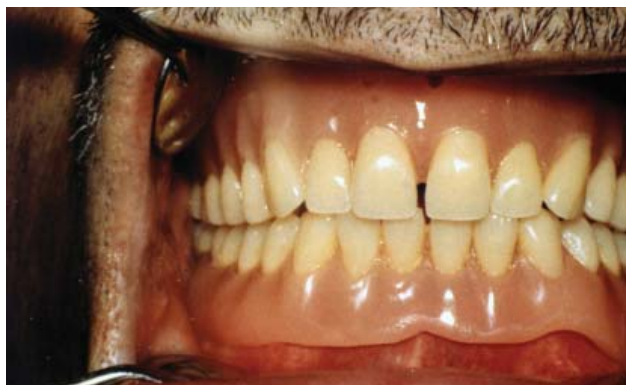Having in mind the significance of preserved teeth for functional validity of removable dentures, the aim of this investigation was to assess the influence of overdentures on the alveolar bone levels surrounding the preserved teeth during a ten year period.

## Material and method

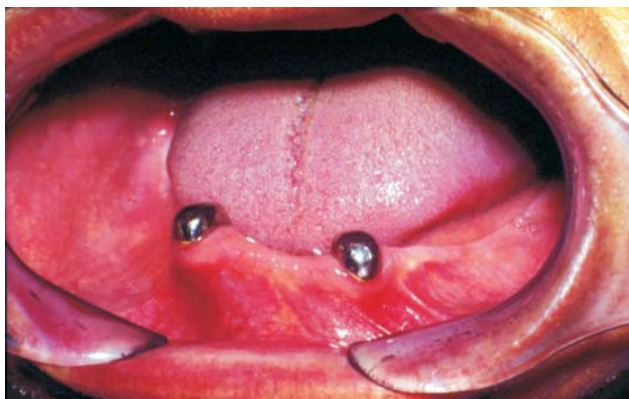
The investigation was carried out in Clinic of Dental Prosthetic, The Faculty of Stomatology, University of Belgrade, from 1994. to 2004. 22 denture-wearing patients, of an average age of 61,75+/- 7,14, were observed from 6 to 10 years. After specific preparation (reduction of clinical tooth crown, endodontic and parodontal preparations) all of the remaining teeth were preserved using casting caps and amalgam restorations (Fig. 3, Fig. 4, Fig. 5, Fig 6).



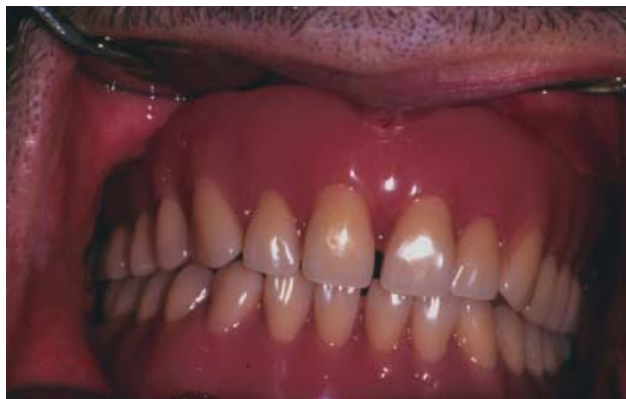Slika 3. Amalgamski ispun na pripremljenom "patrljku" zuba  
Figure 3. Amalgam restoration of the remaining tooth



Slika 4. Supradentalna proteza preko zuba sa amalgamskim ispunom  
Figure 4. Overdenture over the tooth with amalgam restoration  
(in this case)



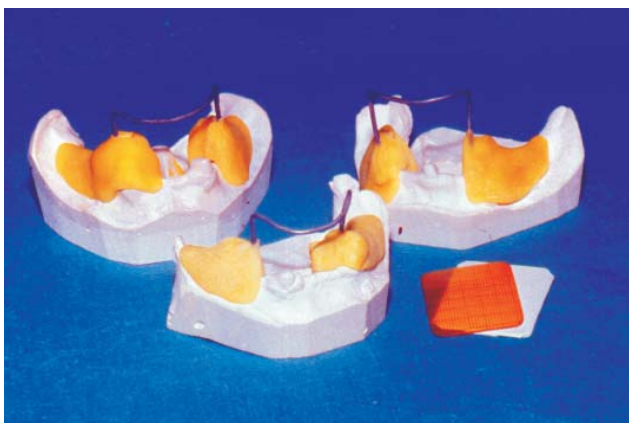
Slika 5. Kapice na pripremljenim "patrljcima" – pacijent B. L.  
Figure 5. Caps on remaining tooth, patient B.L.



Slika 6. Supradentalna proteza u ovom slučaju – pacijent B. L.  
Figure 6. Overdenture, pat. B.L.

U trenutku predaje proteze pripremljeni su specijalni držači Rtg filma za svakog pacijenta i svaki zub ponaosob i načinjen je retroalveolarni snimak zuba. Kao držač poslužila je specijalna kašika izrađena od autopolimerizujućeg akrilata na radnom modelu. Kašika je snabdevena žičanom drškom koja omogućuje jednostavnije držanje i manipulaciju. (sl.7, sl. 8). Posle snimanja držač je vraćan na radni model i tako čuva za naredna rentgen snimanja u posebnim kutijama za svakog pacijenta pojedinačno. 24 h pre svakog snimanja držač je potapan u rastvor dezinficijensa 3% Gigasept FF (Schülke & Mayr, Germany). Pored navedenog, postupak rtg snimanja bilo je moguće ponoviti na identičan način zahvaljujući i tome što je:

- pacijentima prilikom prvog Rtg snimanja zabeležen nagibni i sagitalni ugao upadnog rentgen zraka i svako sledeće je vršeno na identičan način,
- položaj glave pacijenta je uvek bio isti (baza njihove donje vilice je uvek bila paralelna sa podom),
- svako snimanje vršeno je istim dental rentgen-aparatom firme «Heliodont» SIEMENS,
- rastojanje između žiže i filma je regulisano samim aparatom, kada se tubus približi licu pacijenta, to rastojanje je uvek bilo konstantno i iznosilo je 30 cm,
- ekspozicija je uvek iznosila 0,4 s,
- vreme i uslovi razvijanja filma bili su uvek isti, jer su se filmovi uvek razvijali u DÜRR dental aparatu,
- jačina struje i napon su uvek bili fiksni:  $I=7\text{mA}$ , a  $U=70\text{ kV}$ .



Slika 7. Individualni držači za Rtg dental film i žičana mrežica  
Figure 7. Individual dental film holders and grid scale

S obzirom na normiranu poziciju filma i ostale komponente, rentgenski snimak je bilo moguće ponoviti na identičan način.

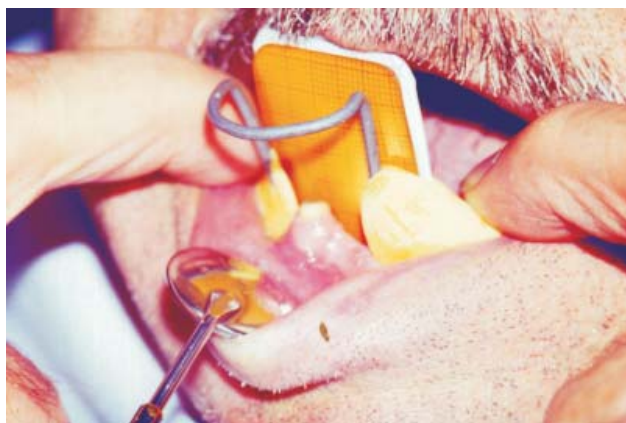Merenja su vršena na svakom rentgenogramu sa mezijalne i distalne strane svakog od prisutnih zuba i to od apeksa korena do koronarne granice alveolarne kosti a uz pomoć mrežice sa milimetarskom podelom koja je uvek identično pozicionirana. (26, 27).

When positioning acrylic dentures into the mouth of patients retroalveolar radiographs were taken using special dental film holder. Specially designed acrylic custom tray was used to provide the same position of dental films, like a Everett and Fixott (26,27).

Film holder was positioned in the surface of acrylic tray to enable easy manipulation (Fig.7, Fig.8). Film holder was positioned back on working cast after exposing the dental radiograph. Film holder was saved for future exposing in special boxes and one hour before each exposing was inserted into 3% disinfectant Gigasept FF (Schülke & Mayr, Germany)

To provide uniformity in procedure of taking radiographs the procedure was extended performing steps in the following manner:

- the relation dental film-object and angulations of the penetrating x-ray stream were standardized;
- the head of each patient was always positioned the same way with his lower jaw parallel to the floor;
- each imaging session was performed using the same dental x-ray apparatus (Heliodont, Siemens, Germany)
- the distance focus-dental film was regulated by the apparatus itself and was determined to be on the distance of 11.8 Inch (30 cm);
- exposition time was 0.4 sec.
- each dental radiograph was processed using the standardized procedure (Dürr dental apparatus for dental film processing);
- conditions were set on 70 kV and 7 mA;



Slika 8. Držač filma, film i mrežica u ustima pacijenta  
Figure 8. The dental film holder, dental film and grid in the mouth

Concerning the position of dental film for each patient and related components, dental radiographs were taken in identical conditions.

The alveolar bone of each examined tooth was measured on the medial and distal, starting from the root apex to the visible border of the alveolar bone using millimetric grid identically positioned. The data received was statistically processed using the arithmetic medium, standard deviation, T test and the variation quotient.

## Rezultati

Rezultati su prikazani tabelarno i grafički. Tabela 1. pokazuje rezultate kod 15 pacijenata koji su praćeni 6 godina. Analizirajući podatke iz tabele 1 utvrđeno je da se u toku 6 god. praćenja:

1. vrednosti kreću mezijalno: od 4,0-10,2 na početku, odnosno 3,5-9,5 posle 6 godina i distalno: od 5,5-10,0 na početku, odnosno, 3,0-9,3 posle 6 godina.
2. prosečne vrednosti se kreću u intervalu: mezijalno od 7,56 1,82 na početku, odnosno 6,15 1,73 posle 6 godina i distalno 7,21 1,39, odnosno, 5,72 1,56 posle 6 godina.

Utvrđena je statistička značajnost prvog.nivoa značaja mezijalno i drugog nivoa značaja distalno između početnog stanja i situacije nakon 6 godina.

Na grafikonu 1. predstavljeno je kojoj vrsti zuba pripadaju 33 zadržana zuba ispod 15 SDP čiji je uticaj na potporna tkiva analiziran u toku 6 god. i to su 16 očnjaka+16 premolara +1 sekutić. Nadalje, na grafikonu 2. je predstavljeno koliko je i kojih zuba izgubljeno u ovoj grupi u opservacionom periodu.

U tabeli 2. su prikazani prosečni nivoi alveolarne kosti kod 7 pacijenata koji su praćeni 10 godina i nisu nadjene statističke značajne razlike. Kako koeficijent varijacije nivoa alveolarne kosti u predelu zadržanih zuba u distalnom predelu prelazi 30 %, ovo ukazuje na činjenicu da je homogenost ovde manje izražena pa možda i ovi rezultati manje pouzdani. Na grafikonu 3 je grafički ilustrovano koliko i kojih zuba je zadržano ispod tih 7 SDP. Ispod tih 7 SDP bilo je 17 zadržanih zuba i to: 7 sekutića+ 7 očnjaka+ 3 premolara. Grafikon 4. pokazuje broj i vrstu izgubljenih zuba kog ispitivanih pacijenata u ovom opservacionom periodu.

## Results

The results are summarized in tables 1, 2 and presented on the graphs 1-4. The table 1 presents the results obtained in fifteen patients wearing the lower overdentures observed during the period of six years.

In the beginning of this investigation the average alveolar bone height amounted messily  $7.56 \pm 1.82$  mm and distally  $7.21 \pm 1.39$  mm. After the six year period of wearing the lower overdenture the average alveolar bone heights in the same regions amounted  $6.15 \pm 1.73$  mm messily and  $5.72 \pm 1.56$  mm distally (Table 1).

Differences were significant on the levels of  $p < 0.05$  for the mesial alveolar heights, and on the level of  $p < 0.01$  for the alveolar heights distally (Table 1).

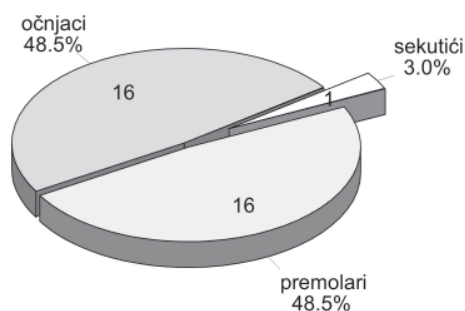
Probability levels of the alveolar bone levels messially and distally were reduced during the period of six years for approximately 0.5-1.5 mm (Table 1).

The average levels of the alveolar bone heights in 7 patients followed a period of ten years (Table 2).

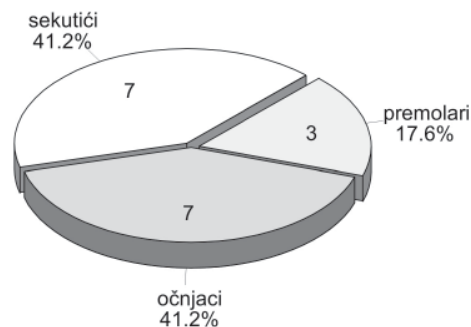
The average initial values of the alveolar bone heights in these patients were  $8.24 \pm 1.36$  messily and  $5.27 \pm 2.55$  distally. After a ten year period these values amounted  $8.11 \pm 2.04$  messily and  $5.42 \pm 2.37$  distally.

According to the T test the differences in the alveolar bone height initially and after ten years following in these 7 patients were not significant.

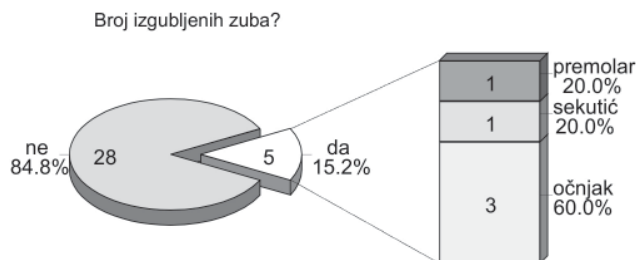
It was realised that only 15% of total number of remaining teeth under 15 overdenture lasted after the observation period of 6 years. Also 30% of total number of remaining teeth under 7 overdentures were lost after observation period of 10 years at the delivery stage. This is shown on diagrams (Graph. 1, Graph. 2).



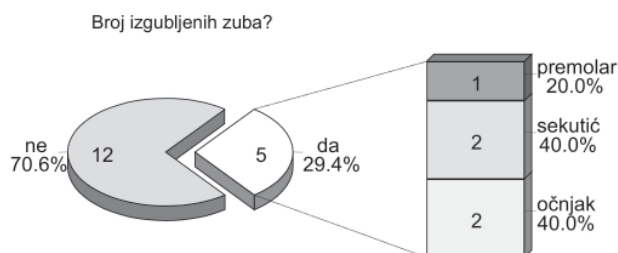
Graf.1 Zadržani zubi kod pacijenata koji su praćeni 6 godina (n=33)  
Graph 1. Remaining teeth after 6 years (n=33)



Graf.3 Zadržani zubi kod pacijenata koji su praćeni 10 godina (n=17)  
Graph 3. Remaining teeth after 6 years at the delivery stage



Graf.2 Zadržani zubi u toku 6 godina praćenja  
Graph 2. Remaining teeth after 10 year (n=17)



Graf.4 Zadržani zubi u toku 10 godina praćenja  
Graph 4. Remaining teeth after 10 years at the delivery stage

Tabela 1. Rtg određen nivo alveolarne kosti sa mezijalne i distalne strane zuba u toku 6-to godišnjeg praćenja

Table 1. Levels of alveolar bone of existing teeth after 6 years

Statistički parametri	Rtg – mezijalno		Rtg - distalno	
	na početku	posle 6 godina	na početku	posle 6 godina
Broj ispitanika	15	15	15	15
Broj zuba	33	28	33	28
Minimalna vrednost	4.0	3.5	5.5	3.0
Maksimalna vrednost	10.2	9.5	10.0	9.3
Prosečna vrednost	7.56	6.15	7.21	5.72
Standardna devijacija	1.82	1.73	1.39	1.56
Koeficijent varijacije u %	24.08	28.09	19.27	27.26
Značajnost razlika u prosečnim vrednostima	$t = 2.174$ $p < 0.05$		$t = 3.596$ $p < 0.01$	

Tabela 2 Rtg određen nivo alveolarne kosti sa mezijalne i distalne strane zuba u toku 10-to godišnjeg praćenja

Table 2. Levels of alveolar bone of existing teeth after 10 years

Statistički parametri	Rtg – mezijalno		Rtg – distalno	
	na početku	posle 10 godina	na početku	posle 10 godina
Broj ispitanika	7	7	7	7
Broj zuba	17	12	17	12
Minimalna vrednost	6.5	4.7	2.0	2.5
Maksimalna vrednost	10.2	10.0	9.2	9.0
Prosečna vrednost	8.24	8.11	5.27	5.42
Standardna devijacija	1.36	2.04	2.55	2.37
Koeficijent varijacije u %	16.45	25.16	48.48	43.66
Značajnost razlika u prosečnim vrednostima	$t = 0.140$ $p > 0.05$		$t = 0.114$ $p > 0.05$	

## Diskusija

Problem redukcije rezidualnog alveolarnog grebena je veliki i ozbiljan kod pacijenata koji su izgubili veliki broj prirodnih zuba. U našoj jednogodišnjoj studiji gde je praćen nivo alveolarne kosti u predelu zadržanih zuba ispod totalnih SDP zaključeno je da ovako kratak period za ovu vrstu istraživanja, nije značajno uticao na promenu nivoa alveolarne kosti u predelu zadržanih zuba. Takođe,

## Discussion

The excessive residual ridge reduction (RRR) is one of the serious problems in the prosthetic treatment of patients who have lost the majority of these natural teeth (7, 8, 10). Regarding the presentation of every natural tooth (root), fabrication of overdentures offers more beneficial results concerning the preservation of the residual alveolar bone as well as in obtaining the better denture stability.

zaključeno je da je dobra oralna higijena značajan faktor koji doprinosi dobrom parodontalnom stanju u obe ispitivane grupe: grupe sa SDP i grupe sa klasičnim parcijalnim protezama pri istim kliničkim uslovima. Tako, odsustvo inflamacije oko zuba sačuvanih ispod SDP u pacijenata eksperimentalne grupe ukazuje da su ovakvi sačuvani zubi vredni zubi za potporu SDP bez obzira na inicijalno nepovoljno parodontološko stanje. (28)

Kako se dakle nisu desile značajne promene nakon 1 godine praćenja, ova studija je proširena na duži niz godina. Naravno, suočili smo se, kao i mnogi drugi istraživači, sa problemima velikih longitudinalnih studija (9,10,29,30,31,32,33,34,35,36,37,38): nemogućnost da se otprate ove studije zbog gubitka pacijenata zbog bolesti, preseljenja pa i smrti jer se radi o starijim pacijentima. Takođe, kako je problem redukcije rezidualnog alveolarnog grebena veoma kompleksan, odnosno, na njega utiče veoma veliki broj faktora to je i prilično teško stvoriti homogene grupe i pratiti ovaj problem. No mi smo eto ipak uspjeli da 15 pacijenata pratimo 6 godina i svega njih 7- 10 godina i u tom opservacionom periodu ipak utvrdili neke značajne promene.

Naime, prilikom statističke obrade podataka, što je i u tabelama prikazano, pojedinačni podaci unutar svakog stratuma, međusobno su homogeni što pokazuje i koeficijent varijacije koji je manji od 30%. Ovakav homogeni uzorak pogodan je za statističko zaključivanje.

I dakle, može se utvrditi da postoji statistički značajna razlika u nivou alveolarne kosti u predelu zadržanih zuba u trenutku predaje proteze i 6 godina nakon predaje i to mezijalno na nivou verovatnoće  $p < 0,05$  i distalno na nivou verovatnoće  $p < 0,01$ . Iako su ovo značajne razlike, imajući u vidu da je to ipak u pitanju relativno dug opservacioni period a i činjenicu da to nije najviši stepen značaja ovaj rezultat ipak ne treba shvatiti kao neuspeh.

Takođe, kod 7 pacijenata koji su praćeni 10 godina nije utvrđena statistički značajna razlika ni mezijalno ni distalno u predelu zadržanog zuba.

Kada su u pitanju bezubi pacijenti, takođe, treba imati u vidu da su prednji delovi oba alveolarna grebena posebno podložni resorpciji, a stanje izazvano intenzitetom i smerom resorptivnih promena posebno stvara teškoće u izradi donje totalne proteze. (7,8,9,10,11,12). Zato je u ovom radu istraživanje sprovedeno kod pacijenata koji imaju donje totalne supradentalne proteze.

Nadalje, zadržani zubi su ključ uspeha terapije supradentalnim protezama. Zato izuzetnu pažnju treba posvetiti selekciji tih preostalih zuba, odnosno, doneti pravu odluku koji od njih će preostati da posluže još jedan izvestan period kao potpora supradentalnoj protezi. Postoje opšte prihvaćeni stavovi kojih se treba pridržavati pri selekciji zuba. Kada se za potporu supradentalnoj protezi koristi veći broj preostalih zuba, onda su i one uspešnije. Najčešća situacija je kada su prisutna 2 zuba i sigurno je da je njihova bilateralna lokalizacija povoljnija od unilateralne. Imajući, međutim, u vidu značaj zadržavanja zuba, čak i

Our previous studies which followed the alveolar bone heights surrounding the last preserved teeth of 12 patients during the 12 months showed that the one year period of wearing overdentures did not influence significantly the levels of the alveolar bone in the regions of the present teeth (18).

The proper oral hygiene and absence of mucosal inflammation in the region of preserved teeth seemed to be the most significant factors in preservation of the parodontal health in the examined patients (28).

The absence of the significant differences in these alveolar bone levels of the preserved teeth in patients followed during the 1 year period and the good parodontal status of these teeth were the motives for prolonging this study of the 10 years period.

As many other investigations in this field, we were faced with many problems which usually follow the longitudinal studies. First of all a number of polder patients was lost because of illness or death.

Moreover, the very wide spectra of factors influencing the processes of RRR made it difficult to obtain the homogenous groups of patients in order to follow the influences of overdentures on these processes.

In spite of these problems we managed to form a sample of 15 patients who were observed in the 6 years period and 7 patients who were observed during a 10 year period. According to the quotient of variation (lower than 30%) data obtained in the analysis of these samples were relatively homogenous (Table 1, Table 2, Graph 1, Graph 2) indicating the reliability in this phase of the comparison of modus operandi.

In patients observed during the six year period the significant differences were obtained in the alveolar bone heights comparing baseline and the next six years period indicated significance to motivate patients and to educate patients within the oral hygienic course of therapy.

However, having in mind the long observation period these differences seem to point to the relatively minor changes in the alveolar bone levels.

Surrounding the preserved teeth in patients wearing the overdenture(??). In 7 patients who were observed during 10 years there were no significant differences between the initial alveolar bone levels surrounding the preserved teeth and the levels after the 10 years. Related to the complete denture therapy in edentulous patients these results can be accepted as a success of overdenture therapy. According to these results the preservation of every tooth or root, and fabrication of an overdenture can be recommended in all patient with satisfactory parodontal status and other well known conditions accepted in selection of teeth which should be used in supporting overdentures. The more teeth used in supporting overdentures, the more successful the therapies with overdenture would be.

The bilateral alignment of remaining teeth to (canines in the lower jaw) is always more beneficial than the unilateral one. However, the results of this investigation, as well

prisustvo samo jednog zuba, pa makar to bio i centralni donji sekutić, može obezbediti zadovoljavajuću stabilnost. (2,14,15,16,17,18,19,20,22).

Postoje više i manje vredni zubi po lokalizaciji, ali je praktično vredan svaki koji je nakon redukcije kliničke krune relativno čvrst i koji je okružen sa bar 5 mm zdravog koštanog tkiva. Ako i ovaj minimalni zahtev nije zadovoljen onda se ovi zubi eksrahiraju, jer se kao takvi smatraju «beznadežnim» (13, 15) (sl.9)

Kada je u pitanju vrsta zadržanih zuba, tvrdnja da se najčešće zadržavaju očnjaci (2,13,15), potvrđena je i u ovom radu jer oni imaju veliku površinu korena, a samim tim i veću širinu pripojnog epitela. Zahvaljujući svom položaju i obliku korena oni najduže ostaju u vilici i najduže usporavaju reduktivne procese, ne samo oko njih, nego i između njih. I mi smo kod naših pacijenata zadržali najviše očnjaka. Od 33 zadržana zuba kod 15 pacijenata koji su praćeni 6 godina 16 zuba su bili očnjaci, a od 17 zuba sa dužim opservacionim periodom, njih 7 su bili očnjaci.

U ovoj studiji su zadržani frontalni zubi pa i premolari kada su oni bili jedini preostali zubi ili pak u kombinaciji sa nekim zubom iz frontalnog regiona jer se to pokazalo značajnim u povećanju potpore za donju totalnu supradentalnu protezu, a i endodontski tretman je obično uvek bilo moguće sa uspehom sprovesti na jednokorenim zubima.

Čak i sekutići kojih ima najmanje, značili su mnogo pacijentima kod kojih su to bili jedini preostali zubi. U grupi praćenoj 6 godina bio je svega 1 sekutić, dok je u grupi sa dužim opservacionim periodom bilo čak 7 zadržanih sekutića.

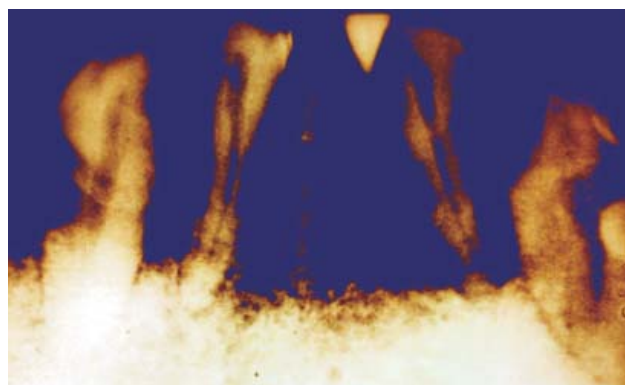
Što se tiče izgubljenih zuba, svakako je nepovoljnija situacija u grupi sa većim opservacionim periodom jer je procenat izgubljenih zuba veći. Ovi naši rezultati su prilično logični imajući u vidu duži opservacioni period i prisustvo većeg broja sekutića zadržanih u ovoj grupi, a oni se smatraju biološki slabijim zubima.

Svi pacijenti koji su bili u studiji dolazili su na kontrolne preglede i bili su pod stalnim nadzorom lekara u toku celog opservacionog perioda tako da su apsolutno saradivali i sprovodili oralnu higijenu na način kako su svi u početku identično edukovani. Relativno dobri rezultati mogu se pripisati i ovom faktoru. (39, 40, 41, 42)

Prateći nivo alveolarne kosti u predelu zadržanih zuba u velikim opservacionim periodima uviđa se da se on nije drastično promenio, odnosno smanjio na štetu zuba, a procenat izgubljenih zuba u studiji govori u prilog logične činjenice da je veći procenat izgubljenih zuba nakon dužeg opservacionog perioda i to približno je duplo veći procenat nakon približno dvostruko dužeg opservacionog perioda.

as our clinical experiences suggest that even preservation of only one lower incisor is more beneficial concerning the stability of dentures than having edentulous lower ridges (15,18,20,21,22,23,24,25).

According to the position and places in the lower jaw the remaining teeth can be more or less valid. However every tooth surrounded with minimum 5 mm (0,185 Inch) of healthy bone and relatively stable after reduction of its crown can offer the valuable overdenture support. If there were no such minimum conditions to convince the supporting bone these “hopeless” teeth would have to be extracted (Fig. 9).



Slika 9. Dentalni snimak “beznadežnih” zuba  
Figure 9. Dental radiogram of the “hopeless teeth”

As well as the class of the preserved teeth, it is considered that the canines are most often preserved. They have relatively great root surface, a great periodontal attachment and also a wider attached epithelium. In the majority of cases they are the only remaining teeth in the lower jaw increasing the reduction processes in surrounding bone as well as in the bone between them particularly. In this investigation among the 33 preserved in 15 patients observed during 6 years, 16 were canines. Among the 17 teeth observed during 10 years 7 were the canines.

In the experimental group observed during the 10 year experimental period the percentage of last teeth was greater. These results can be explained by the long conservative period and the fact that among the preserved teeth there was a great number of preserved lower incisors which have a lower biological validity. All examined patients included in this study were controlled during the whole observation period. All of them were educated to perform the identical and proper oral hygiene measures. This fact also explains very good results obtained in this investigation (30, 31, 32, 33) However, the results and problems of other researchers in longitudinal studies are similar to ours. (34, 35, 36, 37, 38, 39, 40, 41, 42).



## Zaključak

Imajući sve ovo u vidu, može se zaključiti da je u pacijenata sa maksimalnom krezubošću i redukovanim parodontijumom preostalih zuba, supradentalna proteza metoda izbora naime za relativno duže vreme obezbeđuje kvalitetnije i komfornije služenje ovakvom nadoknadom u prelaznom periodu ka bezubom stanju, odnosno, za izvesno vreme odlaže izradu klasične totalne proteze.

## Conclusions

On the base of the validity of the preserved teeth and the influences of their preservation on residual bone it can be concluded that overdenture is always the method to choose in this cases. It provides a better stability, better conformity and function in the transition period before the state of the edentulism.

## Literatura / References

- Jumber JF. An atlas of overdentures and attachments, chapter 4: Abutment and coping considerations. Chicago: *Quintessence*, 1981: 45–50.
- Mascola RF. The root retained complete denture. *JADA* 1976;92:586–587.
- Mensor MS. Removable partial overdentures with mechanical (precision) attachments, *Dent ClinNorthAm*, 1990; 34(4):669-681.
- Gendusa NJ. Magnetically retained overlay dentures. *Quintessence Int* 1988;19: 265–271.
- Preiskel HW. Stud attachments and magnets. In: Preiskel HW.(eds).Overdentures made easy. London: *Quintessence*, 1996, 81–139.
- Pardo GI, Renner RP. The telescoped overdentures: advantages and limitations. *JADA* 1980;101: 932–934.
- Atwood AD. Some clinical factors related to rate of resorption of residual ridges, *J.Prosth.Dent*, 2001; 86(2):119-125.
- Atwood AD, Coy AW. Clinical, cephalometric and densitometry study of residual ridges. *J Prosthet Dent* 1971; 26:280–295.
- Crum RJ, Ronny GE. Alveolar bone loss in overdentures: a 5 year study. *J Prosthet.Dent* 1978; 40:610–613.
- Tallgren A. The continuing reduction of the residual alveolar ridges in complete denture wearers: a mixed-longitudinal study covering 25 years. *J Prosthetic Dent*, 2003; 89;5:427-435.
- Delvin H, Ferguson MWJ. Alveolar ridge resorption mandibular atrophy. A review of the role of local and systemic factors. *Brit.Dent.J* 1990; 170:101–104.
- Glišić B, Stanišić-Sinobad D. Reconstruction of Initial Dimensions of the Lower Residual Ridge and Classification of reduction in Vertical Direction. (abstract in English) *Stom Glas S* 1989; 36:262–265.
- Brewer AA, Morrow RM. Overdentures, ed.2. St. Louis: The C.V. Mosby , 1980:44–51.
- BaskerRM, Harrison A, Ralph JP. Part I The evidence for overdentures. In: BaskerR.M, Harrison A, Ralph J.P. Overdentures in general dental practice. *Br Dent J* 1983, 154:285–287
- BaskerRM, Harrison A, Ralph JP. Part II Indications for overdentures: Patient selection, in BaskerR.M, Harrison A, Ralph J.P. Overdentures in general dental practice. *Br Dent J* 1983, 154: 321–324
- BaskerRM, Harrison A, Ralph JP. Part VI Clinical evaluation and maintance, in BaskerR.M, Harrison A, Ralph J.P. Overdentures in general dental practice. *Br Dent J* 1983, 155:50–54
- Preiskel HW.: Advantages of preserving teeth or roots in Overdentures made easy. London: *Quintessence*, 1996: 12-15.
- Brković-Popović S.: Ispitivanje potpornog aparata zuba ispod mobilnih supradentalnih proteza. Master Thesis (Summary in English). Beograd 1994.
- Dodge CA. Prevention of complete denture problems by use of overdentures. *J Prosthet Dent* 1973; 30:403–11.
- Stewart JR. Treatment planning for the overdenture. *Gen Dent* 1988; 37:397–401.
- Winkler S, Wongthai P.: «Overdentures» *Dent.Clin.of North Am*. IV 1984; 28:(349–60).
- Walters RA Design, preparation and maintenance of overdenture abutments. *Dent Clin North Am* 1990; 34: 631-644.
- Renner RP. The overdenture concept. *Dent Clin North Am* 1990; 34: 593- 600.
- Best HA. Mandibular overdenture treatment— Case report. *Australian Dent J* 1990; 35:125–7.
- Amzalag G, Batarec E, Schorendorf R. et all. Proteses supradiculaire: Overdentures. Paris: Editions CdP 1988:1–19.
- Everett FG, Fixott HC. The incorporated millimeter grid in oral roentgenograms, *Quintessence international* 1975; 6(5):53-58.
- Fixott HC, Watkins RF. Refinements in diagnostic X-ray technics with use wire grids, *J Am Dent Assoc* 1969; 78:122–125.
- Brkovic-Popovic S, Stanisic-Sinobad D. Comparison of the alveolar bone level in patients with overdentures and patients with conventional acrylic partial dentures, *Balkan J of Stomatology* 1999; 3:111–115.
- Fenton AH, Hahn N. Tissue response to overdenture therapy. *J Prosthet Dent* 1978; 40: 492–498.
- Tolson LB, Smith DE. A 2 year longitudinal study of overdenture patients, partI: Incidence and control of caries an overdenture abutments. *J Prosthet Dent* 1978; 40: 486–491.
- Tolson LB, Smith DE. A 2 year longitudinal study of overdenture patients, part II: Assessment of the periodontal health of overdenture abutments. *J Prosthet Dent* 1982; 47: 4–11.
- Renner RP, Gomes BC. Periodontal health, prosthodontic factors and microbial ecology of patient treated with overdentures ( a 2,5 year report). *Quintessence Int* 1984; 645–652 (report 2311).
- Reith PV, Weiner MG, Levin B. An overdenture survey: second report. *J Prosthet Dent* 1980; 43:457–462.
- Ettinger RL, Qian F. Abutment tooth loos in patients with overdentures. *J Am Dent Assoc*. 2004;135(6):739-746.

35. Ettinger RL, Taylor TD, Scardrett FR. Treatment needs of overdenture patients in a longitudinal study: five year results. *J Prosthet Dent* 1988; 59:532–536.
36. Tolson LB, Smith DE.: A five year longitudinal study of patient treated with overdentures. *J Prosthet Dent* 1983; 49:749–756.
37. Tolson LB, Taylor TD. A 10 year report of a longitudinal recall of overdenture patients. *J Prosthet Dent* 1989; 62:179–181.
38. Fenton A.H. The decade of overdentures: 1970-1980, *J Prost Dent* 1998; 79(1):31-36.
39. Budtz-Jorgensen E. Prognosis of overdenture abutments in elderly patients with controlled oral hygiene: a 5 year study. *J Oral Rehabil* 1995; 22:3–8.
40. Budtz-Jorgensen E. Prognosis of overdenture abutments in the aged : effects of denture wearing habits. *Community Dent Oral Epidem* 1992; 20:302–6.
41. Budtz-Jorgensen E. Effect of controlled oral higiene in overdenture wearers: a 3 year study. *Int J Prosthodont* 1991; 4: 226-231.
42. Mericske EA, Mericske-Stern R. Overdenture abutments and reduced periodontium in elderly patients- a retrospective study. *Schweiz Monatsschr Zahnmed* 1993; 103:1245–1251.

### Autor odgovoran za korespondenciju

Snežana Brković-Popović  
Klinika za stomatološku protetiku, Stomatološki fakultet  
Rankeova 4, 11000 Beograd  
Tel: 011/2699-209  
E-mail: koki13@ptt.yu

### Address for correspondence

Snežana Brković-Popović  
Clinic for Prosthetic Dentistry, School of Dentistry Belgrade  
Rankeova 4, 11000 Belgrade, Serbia and Montenegro  
Tel: +381 11 2699-209  
E-mail: koki13@ptt.yu