

**Case Study****AYURVEDIC MANAGEMENT OF CERVICAL EROSION THROUGH YONIDHAVAN WITH TRIPHALA AND DARUHARIDRA KWATH, APAMARGA KSHAR PRATISARAN WITH JATYADI TAILPICHU – A CASE STUDY****Akanksha Mahesh Naik^{1*}, Seema Chandrakant Mehere²**¹13rd Year PG Scholar, ²Professor and HOD Dept. of Prasuti Tantra & Stri-roga, Y.M.T Ayurveda Medical College and Hospital, Kharghar, Navi Mumbai.**KEYWORDS:** Cervical Erosion, *Triphala*, *Daruharidra Kwath*, *Apamarga Kshar Pratisaran*, *Jatyadi Tailpichu*.**ABSTRACT**

In chronic cervicitis, there is marked thickening of the cervical mucosa with underlying tissue oedema. These thickened tissues tend to push out through the external os along the direction of least resistance. The entity is most marked where the cervix has already been lacerated. In such conditions, the longitudinal muscle fibres are free to act unopposed. As a result, the lips of cervix curl upwards. Now a days number of females has developed cervicitis very fast and symptoms are like per vaginal white discharge with foul smell, and dyspareunia. This cervical erosion further leads to dyspareunia and then to infertility also. There is no disease given in Ayurveda classics which can directly correlate with cervical erosion. But in some aspect of symptoms and signs this can correlate with *Karnini yonivyapad* and hence treatment can be according to that. In this article case study of cervical erosion described which was treated with Ayurvedic *Sthanik chikitsa- Yonidhavan* by *Triphala* and *Daruharidra kwath*, *Apamarga kshar pratisaran* and *Jatyadi tail pichu* for 7 days for 3 conjugative cycles. With this combined therapy of *Sthanik chikitsa* cervical erosion has been completely cured. Hence clinical trial can be done in large number of patients to see further results.

Address for correspondence*Dr Akanksha Mahesh Naik**

3rd Year PG Scholar,

Dept. of Prasuti Tantra & Stri-roga, Y.M.T Ayurveda Medical college and Hospital, Kharghar, Navi Mumbai.

Email:

akankshavishe1992@gmail.com**INTRODUCTION**

Chronic Cervicitis is variously estimated to be present some degree in 35-85% of women. Now a days number of females has developed cervicitis very fast and symptoms are like per vaginal white discharge with foul smell, and dyspareunia. This cervical erosion further leads to dyspareunia and then to infertility. Allopathic medicines such as a antibiotics and pessaries gave relief for temporarily but patient again developed the same symptoms after cessation of treatment. There is no disease given in Ayurveda classics which can directly correlate with cervical erosion. But in some aspect of symptoms and signs this can be correlated with *Karnini yonivyapad* and hence treatment can be given according to that. In this article case study of cervical erosion described which was treated with Ayurvedic *sthanik chikitsa- Yonidhavan* by *Triphala* and *Daruharidra kwath*, *Apamarga kshar pratisaran* and *Jatyadi tail pichu* for 7 days for 3 conjugative

cycles. With this combined therapy of *Sthanik chikitsa* cervical erosion has been completely cured. Hence clinical trial can be done in large number of patients to see further results.

Aim and Objective**Aim-** To study the effect of *Sthanik chikitsa* in cervical erosion.**Objective**

1. To study the efficacy of *Yonidhavan*, *Triphala* with *Daruharidra*, *Apamarga kshar pratisaran* and *Jatyadi Tail Pichu*.
2. To study *Karnini yonivyapad* in detail and cervical erosion.

Material and method**Case description**

A 30 years old female patient, visited with complaints of p/v white discharge with foul smell,

Dysparunia, itching around the vulva and generalized weakness since 4 months.

Patient had taken allopathy treatment for 3 months but got temporary relief from the symptoms and faced number of side effects such as nausea, weakness due to the treatment. Then patient came to YMT Ayurvedic hospital for further management.

Past medical history: No H/O DM/HTN/Bronchial asthma/hypothyroidism.

Pat surgical history: No h/o any past surgical illness.

Past H/O allergy: No h/o any past allergy

Family history: Nil

Menstrual history: 2-3 days bleeding/each menstrual cycle. The regular cycle was of 28-32 days with painful, moderate bleeding (3-4 pads/day). The patient was married in 2016.

Coital history- 2 times/ week (painful/ Dysparunia)

Contraception history - male partner using Condom

General examination findings:

G.C.- stable

Temperature- afebrile

Pulse- 76/ min

BP- 120/70 mm hg

Height- 5ft

Weight- 54kg

Systemic Examination

RS - Aebe Clear

CVS - S1S2 Normal

CNS - conscious, oriented

P/ S -

Cervix - erosion + + + +

Curdy white discharge + +

Result

Foul smell present

P/V- uterus anti-verted, anti-flexed

Normal sized

Fornix- tenderness + + + +

Treatment given

1) *Yonidhavan* with *Triphala* + *Daruharidra kwath*

2) *Apamarga kshara pratisarana*

3) *Jatyadi taila pichu*

These three *Karmas* were done as combined therapy in patient and this treatment done for 3 conjugative cycles after menses.

Pathya

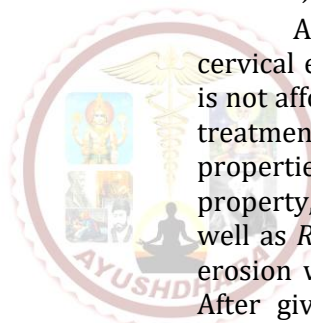
Patient was instructed to avoid extra oily food items, outside snacks, salty food etc.




And also advised to maintain her personal hygiene and avoid common toilets.

DISCUSSION

This cervical erosion has correlated with *Karnini yoniwyapad* and different Acharyas gave that the treatment of *Karnini yonivyapad* should be *Shodhan, Shleshmaha*.

According to allopathy treatment for cervical erosion or cervicitis is cauterisation which is not affordable to all the patients and hence above treatment was given. *Triphala* is *Kaphapittashamak* properties; *Daruharidra* is *Kaphapittaghna* property, *Apamarga kshar* acts as *Lekhan dravya* as well as *Ropan*. And *Jatyadi tail Pichu*- will heal the erosion with *Snighndha guna* and *Ropan* property. After giving this treatment patient got complete relief from the symptoms and dyspareunia also cured.



	Before treatment	During the treatment	After treatment
P/S-			
Signs	Cervix - erosion + + + + White discharge present	Redness Reduced	Cervical erosion completely healed

CONCLUSION

Yonidhavan with *Triphala kwath* and *Daruharidra* and *Apamarga kshar pratisaran* Along with *Jatyadi taila pichu* for 7 days for 3 conjugative cycles is effective in above case.

This treatment had no side effects and also treatment is cost effective also.

REFERENCES

1. D.CDatta's Textbook of Gynaecology (sixth edition) Edited by Hiralal Konar. PG no. 160
2. Jefcoate's Principles of Gynaecology (ninth international edition) Revised and updated by Narendra Malhotra, Jaideep Malhotra, Richa Saxena, Neharika Malhotra bora. Page no. 405.
3. Charak Samhita dvitiya bhag – chikitsasthan (acahrya priyavat sharma) chaukhamba sanskrt prakashan. Page no. - 742
4. Sushrutsamhita (ayurved tattva sandipika) kaviraj shastri A.D. Chaukhamba Sanskrit sansthan. Page no. 231.
5. Ayurvedic pharmacology and therapeutic uses of medicinal plants dravayagunavignyan (Vaidya V. M. Gogate) Chaukhamba publication . Page no. 294,394

Cite this article as:

Akanksha Mahesh Naik, Seema Chandrakant Mehere. Ayurvedic management of cervical erosion through Yonidhavan with Triphala and Daruharidra kwath, Apamarga kshar pratisaran with Jatyadi tailpichu – A case study. AYUSHDHARA, 2019;6(6): 2477-2479.

Source of support: Nil, Conflict of interest: None Declared

Disclaimer: AYUSHDHARA is solely owned by Mahadev Publications - A non-profit publications, dedicated to publish quality research, while every effort has been taken to verify the accuracy of the content published in our Journal. AYUSHDHARA cannot accept any responsibility or liability for the articles content which are published. The views expressed in articles by our contributing authors are not necessarily those of AYUSHDHARA editor or editorial board members.

