

**Case Study****EFFICACY OF CHEDANA AND LEKHANAKARMA IN PALPEBRAL FORM OF VERNAL KERATOCONJUNCTIVITIS (VKC) – A CASE STUDY****Sreekumar.K^{1*}, Arathi S Nair²**¹Assistant Professor, ²Final M.S (Ay) Scholar, Department of Shalakyatantra, Govt. Ayurveda College, Tripunithura, Kerala, India.**KEYWORDS:** Vernal kerato conjunctivitis (VKC), *Vartma sharkara, Chedana, Lekhana.***ABSTRACT**

Ocular allergy is often under-diagnosed but has a significant impact on the quality of life and vision in all ages especially in childhood. Although its incidence varies by geographical location, the prevalence is difficult to gauge as allergies tend to be underreported compounded by the difficulty in classification. Vernal keratoconjunctivitis (VKC) is one of the most commonly occurring types of allergic conjunctivitis. It usually appears in three forms i.e., palpebral, bulbar and mixed and predominantly occurs in younger age group between 4-20 years. This chronic disease is characterized by the formation of giant papillae which constantly irritates the cornea and predispose to ectatic corneal disorders like keratoconus and cause myopia and astigmatism. Topical corticosteroids relieve itching, redness and edema but should be used with caution as their constant use are known to cause glaucoma, cataracts, secondary bacterial; viral and fungal infections and delayed wound healing. In *Ayurveda*, the disease *Vartmasharkara* shows clinical features similar to this disease and *Acharya Susruta* has suggested *Chedana* followed by *Lekhana* to manage this condition. This article describes the case report of a 12 year old male child who had complaints of palpebral form of VKC. In the present study, it is observed that Ayurvedic management along with *Chedana* and *Lekhanakarma* has provided significant relief in all signs and symptoms of allergic conjunctivitis.

Address for correspondence*Dr K Sreekumar**Assistant Professor,
Department of Shalakyatantra,
Govt. Ayurveda College,
Tripunithura, Kerala, India.

Email:

drsreekumarmsayu@yahoo.co.in

Mob: 09447295858

INTRODUCTION

Vernal keratoconjunctivitis is a type of bilateral allergic conjunctivitis found in younger individuals usually boys^[1]. Burning sensation, itching, lacrimation and photophobia are the chief symptoms^[2] accompanied by a characteristic white ropy discharge^[3]. Some young adults develop severe manifestations of this disease associated with indefinite recurrences^[4]. Two typical forms are seen viz., the palpebral and the bulbar or limbal form; but sometimes both forms may occur together in the same patient^[5]. The palpebral form is easily recognized by the cobble stone appearance of the hypertrophied papillae^[6]. Both types can be complicated by a fine diffuse superficial punctate keratitis^[7]. Even though the prognosis is good, some individuals show very severe recurrences for several years leading to the development of severe dry eyes, corneal ulcers^[8], keratoconus and keratoglobus^[9]. The available treatment is symptomatic with use of antihistamine eye drops and steroid drops, usually 4-6 hourly^[10]. Even though this offers instantaneous relief, recurrence is very common after the cessation of such drops. Further, chronic steroid usage puts the patient at serious risk of silently developing steroid induced glaucoma^[11].

In Ayurvedic classics, conditions presenting with burning sensation, itching, lacrimation and photophobia with development of large *Pitakas* involving eyelids are mentioned under the broad heading of *Vartmagata rogas*^[12]. Surgical procedures like *Lekhana*, *Chedana* and *Bhedana* hold a main line of management in such conditions. This may be due to the fact that structural deformities on the conjunctival surface are the end result of such pathologies. *Varmasharkara* is a condition similar to palpebral form of VKC due to its characteristic papillae formation^[13]. Considering the chronic nature of this disease and the side effects of current management of VKC in modern ophthalmology, Ayurvedic line of management including the surgical procedures is very much promising to tackle this condition to a certain extent.

AIMS AND OBJECTIVESTo study the efficacy of *Chedana* and *Lekhana karma* in palpebral form of vernal keratoconjunctivitis (VKC).**MATERIALS AND METHODS**

A 12 year old male child patient of allergic conjunctivitis was selected and consent was obtained from the parents.

Review of Literature

Vernal keratoconjunctivitis

VKC is a chronic ocular surface inflammatory condition most commonly observed in young males before puberty living in dry, warm climates^[14]. It is usually bilateral and characterized by seasonal or perennial symptoms that exacerbate with recurrences in 60% of individuals during spring, early autumn and winter. Prolonged inflammation, more than 3 years, dispose to a greater chance of developing perennial symptoms.

During exacerbations, intense itching is the predominant feature, followed by photophobia, tearing, and sticky mucus discharge (Bonini et al., 2000). VKC include a wide spectrum of clinical features and all of them need not be necessarily present at the time of visit, and could be a manifestation of disease evolution. The disease may primarily involve the tarsal or limbal conjunctiva leading to different forms of VKC: tarsal (palpebral), limbal (bulbar) or mixed forms.

- In tarsal VKC, there will be hyperemic conjunctiva, chemosis and hypertrophic papillae 0.5-0.75 mm in size with a cobblestone appearance constituting the hallmark of this disease. Typical Maxwell-Lyons sign is recognized for thick strands of mucus over papillae.
- In limbal VKC, gelatinous yellow-gray infiltrates are observed on the limbus, the circumference of which might appear thickened and opaque, with a peripheral and superficial neovascularization. Horner Trantas dots are white, calcareous-like cellular infiltrates with eosinophil reaction occurring on the edge of limbal conjunctiva and also on top of nodules^[15]. Corneal involvement includes superficial punctate keratopathy,

corneal erosions, indolent superficial ulcer (shield ulcers) which develops with opaque edges and plaque formation through deposition of mucus and cells, mainly located at the superior quadrants^[16]. VKC can also be associated with keratoconus, which in fact should be a mandatory condition to search, because 6% of patients might end up with permanent reduction in visual acuity as a result of the cornea compromise. The higher incidence of compromise due to persistent disease at the ocular surface occurs with chronic limbal inflammation leading to gradual loss of stem cell function as a result of insufficient stromal support, ending up with limbal stem cell deficiency, and conjunctival fibrosis (Sangwan et al., 2005).

• Ayurvedic concept

In *Ayurveda*, this disease can be taken as one among the 21 *Vartmagata rogas*. Intense itching, watering, heaviness & edema of the lids, along with redness, discoloration and conjunctival growth should be considered for the exact diagnosis. *Pothaki*, *Vartma-sharkara*, *Bahalavartma*, *Varmavabandha* and *Shyavavartma* are the main diseases showing similar clinical features. As the formation of follicles (*Pitaka*) over the tarsal conjunctiva is the cardinal feature of palpebral form of vernal keratoconjunctivitis (VKC), the most appropriate diagnosis will be *Vartma sharkara*. *Acharya Susruta* has considered *Vartma sharkara* as a *Sannipathaja vyadhi* characterized by *Khara* and *Sthoola Pitakas* on the inner surface of *Vartma* (*Vartmano anthae*)^[17]. The disease *Vartmavabandha* is also a *Tridoshaja vyadhi* and shows the peculiar feature of itching and edema, but without the development of *Pitakas*^[18].

Comparative table showing Lakshanaand Dosha vitiation of different Vartmagata rogas

| Disease | Symptoms | Dosha vitiation | Signs |
|-------------------------------------|---|---------------------|---|
| <i>Pothaki</i> ^[19] | Discharge, itching, pain | <i>Kaphaja</i> | <i>Rakthasarshapa sannibha pitaka</i> |
| <i>Bahalavartma</i> ^[20] | Not specifically mentioned | <i>Sannipathaja</i> | smooth and even <i>Pitaka</i> |
| <i>Vartmavabandha</i> | Itching, dull pain, edema | <i>Sannipathaja</i> | Profuse edema of lids |
| <i>Shyavavartma</i> ^[21] | Pain, burning sensation, edema, itching | <i>Sannipathaja</i> | Blackish discoloration of lids |
| <i>Vartmasharkara</i> | Not specifically mentioned | <i>Sannipathaja</i> | <i>Khara</i> , <i>Sthoola</i> and <i>Khana pitaka</i> |

From the above table it is evident that dull pain, burning sensation/photophobia and itching are the cardinal features of *Sannipathajavyadhis* contributed by each *Doshas* i.e., pain can be attributed to *Vata*, burning sensation/photophobia to *Pitta* and itching to *Kapha*. Hence, even if not specifically mentioned, these three features should be considered in all *Sannipathaja vyadis*. *Acharya Madhavakara* has mentioned that *Vartma-sharkara* is "*Vartmadushaka*" i.e., it will cause permanent deformities in eyelids^[22]. The term "*Sharkara*" denotes rough, large and multiple growths on the eyelids and it is evident that chronic palpebral form of VKC will eventually lead to conjunctival fibrosis and giant papillary conjunctivitis (GPC) causing permanent derangement in lid structure and function. Both these

complications may be correlated to the term *Vartmadushaka* of *Madhavanidana*.

Case Study

A boy aged 12 years consulted in OPD, Dept of *Salakya tantra*, Govt Ayurveda College, Tripunithura, Kerala, India, complaining of severe itching of both eyes associated with watering and photophobia of 2 years duration. The boy had a habit of playing football and later on developed itching of both eyes. Photophobia and watering were also started meanwhile. He consulted nearby ophthalmologist and got symptomatic relief after instilling topical eye drops but the condition aggravated after cessation of drops. He again met with similar episodes multiple times since the last two years. So he consulted Ayurveda expecting a better relief.

Chief Complaints and Associated Symptoms

Itching of both eyes since 2 years associated with severe watering and photophobia. Just after waking up in the morning, the child was able to open his eyes only after a long time. There was also associated sticky discharge and redness of Eye.

Personal History

- Bowel – regular
- Appetite – less
- Micturition – regular
- Sleep –disturbed

History of Previous Illness

No history of previous illness

Family History

Nothing relevant

Investigations

Vision – 6/9 N6 (OD) and 6/9 N6 (OS)

Slit lamp examination :

- **Eye lids** – large flat topped papillae arranged like cobble stone in the upper tarsal conjunctiva of both eyes. White ropy discharge was also noted.
- **Cornea** – Slightly hazy and punctate epithelial lesions were seen which showed positive fluorescein staining in both eyes.

DIAGNOSIS

Vartma sharkara (Vernal keratoconjunctivitis – Palpebral form)

LINE OF MANAGEMENT

Vartma sharkara is a *Lekhyasadhya vyadhi*^[23].

Acharya Susrutha has advised *Chedana* followed by *Lekhana* in three specific diseases i.e. *Kumbika*, *Sharkara* and *Utsangi*^[24]. Here, considering the big size of

follicles which were constantly irritating the cornea, *Chedana* followed by *Lekhana* was performed.

In this patient, due to the early presentation of *Ama lakshanas*, the following treatments were done mainly intended to reduce the corneal lesions and conjunctival discharge. The treatments given were:

- *Seka* with *Triphala yasti kasaya* – twice daily
- *Aschyothana* with *Chandanadi Aschyotana*^[25]–twice daily (after *Seka*)
- *Guloochadi kashaya*^[26] 60ml with *Vaiswanara churna*^[27] 5gm - twice a day- half an hour before food.

After developing the proper appetite and reduction in the photophobia, *Accha snehapaana* was done.

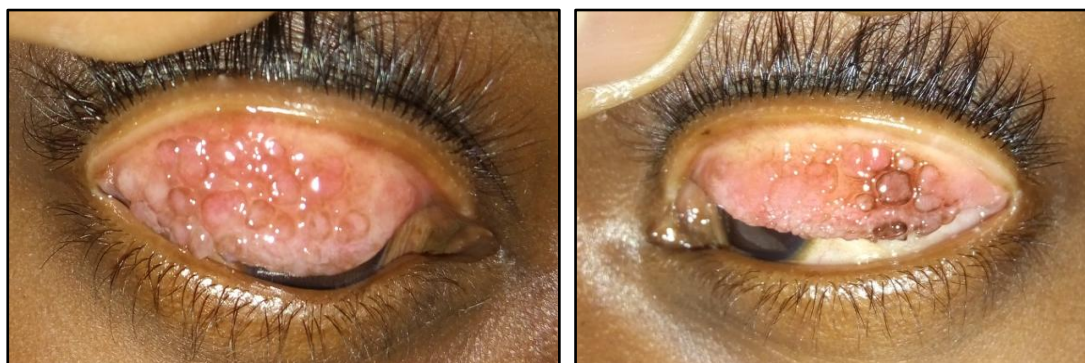
- *Accha snehapaana* with *Indukantha gritha*^[28] for 7 days. Starting from 15gm up to 120gm 6 am in the morning in empty stomach.
- *Ksheerabala taila*^[29] *Abhyanga* and *Ushnodaka snana* were done for 03 days.
- *Virechana* was done with *Avipathi churna*^[30] 15gm mixed with honey, after *Sneha sweda*.
- *Marsanasya* was done with *Anutaila*^[31] for 7 days

After the *Kaya sodhana* and *Shirashodana*, *Chedana* of the big follicles was done using conjunctival scissors under topical anaesthesia.

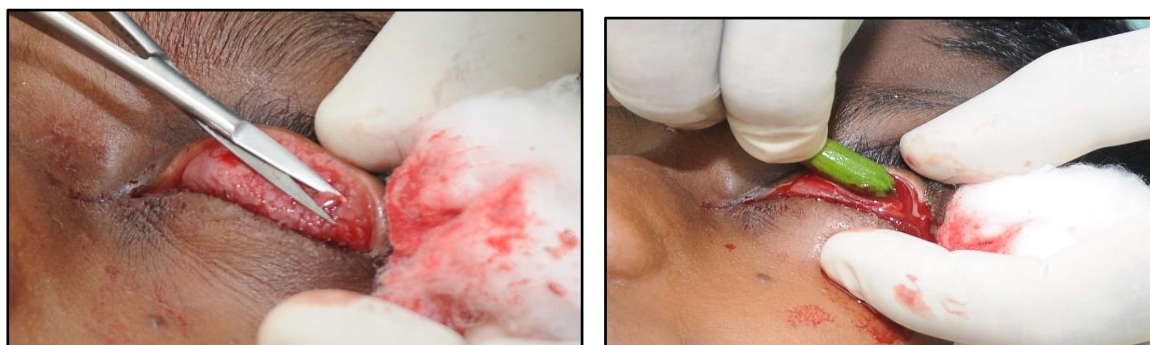- *Lekhana* was done using *Japakusuma* till tarsal conjunctiva attained a smooth surface. The procedure was followed by *Prathisarana* with *Saindhava* and *Madhu*. Bandaging was done with *Durvaghrita*^[32] and *Madhu*. *Kshalana* and bandaging was done for five days post operatively.

- The patient was instructed to avoid milk, curd, sweet and sour drinks and dishes.

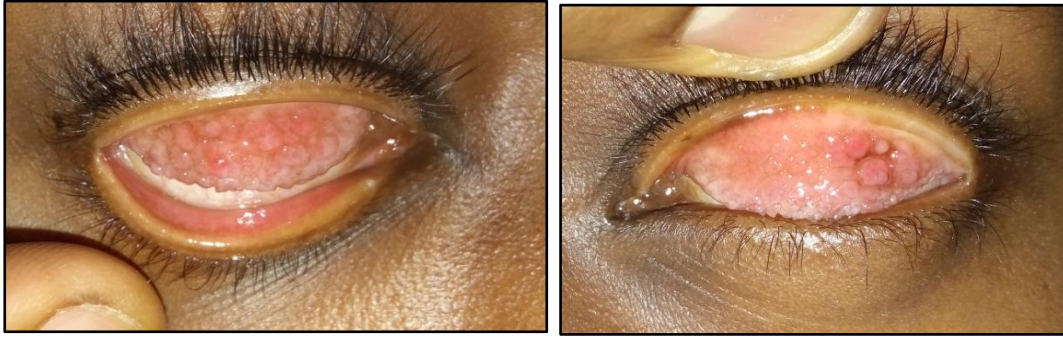Before treatment



Procedure of Chedana and Lekhana



After treatment

**OBSERVATION AND RESULT**

After the procedure, patient got complete relief from photophobia and watering. Itching and sticky discharge were considerably reduced. The vision improved to 6/6 in both eyes with marked reduction in the size of follicles. He was advised to take *Indukantha Ghrita* 15gm with *Rajanyadi Churna*^{33]} 5gm HS and to do *Triphalayashti Kashaya Seka* for two weeks. After the follow up, cornea was clear and photophobia and watering did not reoccur. The child showed only minimal itching and occasional ropy discharge during morning time.

DISCUSSION

Allergic ocular diseases have become a special concern for clinical and basic research. Their impact on quality of life among individuals, annually represent an important issue of investment to find better treatments, particularly to control the effects of chronic diseases which could threaten vision and negatively influence day to day activities.

The corneal epithelial damage occurring due to the irritation caused by the follicles was completely relieved as the conjunctival surface became smooth after the *Lekhana karma*. In this condition it is important to perform *Chedana* before *Lekhana* as the hard follicles will not respond initially to *Lekhana*. *Chedana* will be highly beneficial to remove the elevation and *Lekhana karma* leaves the surface smooth.

CONCLUSION

As the topical steroids are widely used in VKC, a lot of complications are reported because of long term use without the advice of the doctor. As this disease is very much distressing to the child, a better alternative is highly promising. By analyzing this case, it is proven that *Chedana* followed by *Lekhana* is highly effective to cure the condition. Even though it may require multiple sittings to repeat the procedure which is essential to attain permanent cure, it can be very much beneficial to the patients as they can avoid steroids with dreaded complications.

REFERENCES

1. Ramanjit Sihota Radhika Tandon. Parsons' Diseases of the Eye. Edition-XXII. NewDelhi; Reed Elsevier Private Limited; 2015. P. 180
2. Ibid
3. A K Khurana. Comprehensive Ophthalmology. Edition-IV. New Delhi; New Age International (P) Limited; 2007. P. 74
4. Ramanjit Sihota Radhika Tandon. Parsons' Diseases of the Eye. Edition-XXII. New Delhi; Reed Elsevier Private Limited; 2015. P. 180
5. Ibid
6. A K Khurana. Comprehensive Ophthalmology. Edition-IV. New Delhi; New Age International (P) Limited; 2007. P. 74.
7. Ramanjit Sihota Radhika Tandon. Parsons' Diseases of the Eye. Edition-XXII. New Delhi; Reed Elsevier Private Limited; 2015. P. 180
8. Ibid
9. L C Dutta Nitin K Dutta. Modern Ophthalmology. Vol.1. Edition-III. New delhi; Jaypee Brothers Medical Publishers (P) Ltd; 2014. P. 94
10. A K Khurana. Comprehensive Ophthalmology. Edition-IV. New Delhi; New Age International (P) Limited; 2007. P. 76
11. A K Khurana. Comprehensive Ophthalmology. Edition-IV. New Delhi; New Age International (P) Limited; 2007. P. 234
12. Susruta. Susruta Samhita with Nibandhasangraha Commentary of Sri Dalhanacharya Edited by Vaidya Jadavji Trikamji Acharya, Narayan Ram Acharya 'Kavyatirtha'. Edition: Reprint 2015. Varanasi; Chaukambha Sanskrit Sansthan. p.599
13. Susruta. Susruta Samhita with Nibandhasangraha Commentary of Sri Dalhanacharya Edited by Vaidya Jadavji Trikamji Acharya, Narayan Ram Acharya 'Kavyatirtha'. Edition: Reprint 2015. Varanasi; Chaukambha Sanskrit Sansthan. p. 600.
14. Jack J Kanski Brad Bowling. Clinical Ophthalmology. Edition-VII. China; Elsevier Limited; 2011. P. 145.
15. Ibid
16. Jack J Kanski Brad Bowling. Clinical Ophthalmology. Edition-VII. China; Elsevier Limited; 2011. P. 146.
17. Susruta. Susruta Samhita with Nibandhasangraha Commentary of Sri Dalhanacharya Edited by Vaidya Jadavji Trikamji Acharya, Narayan Ram Acharya 'Kavyatirtha'. Edition: Reprint 2015. Varanasi; Chaukambha Sanskrit Sansthan. p. 600.
18. Ibid
19. Susruta. Susruta Samhita with Nibandhasangraha Commentary of Sri Dalhanacharya Edited by Vaidya Jadavji Trikamji Acharya, Narayan Ram Acharya

- 'Kavyatirtha'. Edition: Reprint 2015. Varanasi; Chaukambha Sanskrit Sansthan. p. 599.
20. Susruta. Susruta Samhita with Nibandhasangraha Commentary of Sri Dalhanacharya Edited by Vaidya Jadavji Trikamji Acharya, Narayan Ram Acharya 'Kavyatirtha'. Edition: Reprint 2015. Varanasi; Chaukambha Sanskrit Sansthan. p. 600.
21. Ibid
22. Madhava Acharya. Madhavanidana (Malayalam) with Sararthadeepika Commentary. Edition: Reprint 7th 2006. Sivakasi; Modern offset printers. p. 443.
23. Susruta. Susruta Samhita with Nibandhasangraha Commentary of Sri Dalhanacharya Edited by Vaidya Jadavji Trikamji Acharya, Narayan Ram Acharya 'Kavyatirtha'. Edition: Reprint 2015. Varanasi; Chaukambha Sanskrit Sansthan. p. 610.
24. Susruta. Susruta Samhita with Nibandhasangraha Commentary of Sri Dalhanacharya Edited by Vaidya Jadavji Trikamji Acharya, Narayan Ram Acharya 'Kavyatirtha'. Edition: Reprint 2015. Varanasi; Chaukambha Sanskrit Sansthan. p. 620.
25. Dr Lal Krishnan. Arogya Raksha Kalpadrumah. Edition I. Varanasi; Chowkhamba Krishnadas Academy. p. 317.
26. Vagbhata. Ashtanga Hrudaya with Sarvangasundara of Arunadatta and Ayurvedarasayana of Hemadri Edited by Pt. Hari Sadasiva Sastri Paradakarav Bhisagacarya. Edition reprint 2012. Varanasi; Chaukambha Sanskrit Sansthan. p. 235.
27. Vagbhata. Ashtanga Hrudaya with Sarvangasundara of Arunadatta and Ayurvedarasayana of Hemadri Edited by Pt. Hari Sadasiva Sastri Paradakarav Bhisagacarya. Edition reprint 2012. Varanasi; Chaukambha Sanskrit Sansthan. p. 687.
28. Anekkalil. S. Gopalapillai. Chikitsasarasarvaswam with Sujanapriya Commentary. Edition XXVI. Alapuzha; Vidyarambham Publishers. p. 322.
29. Vagbhata. Ashtanga Hrudaya with Sarvangasundara of Arunadatta and Ayurvedarasayana of Hemadri Edited by Pt. Hari Sadasiva Sastri Paradakarav Bhisagacarya. Edition reprint 2012. Varanasi; Chaukambha Sanskrit Sansthan. p. 732.
30. Vagbhata. Ashtanga Hrudaya with Sarvangasundara of Arunadatta and Ayurvedarasayana of Hemadri Edited by Pt. Hari Sadasiva Sastri Paradakarav Bhisagacarya. Edition reprint 2012. Varanasi; Chaukambha Sanskrit Sansthan. p. 743.
31. Anekkalil. S. Gopalapillai. Chikitsasarasarvaswam with Sujanapriya Commentary. Edition XXVI. Alapuzha; Vidyarambham Publishers. p. 269.
32. Dr. K. Lalithamma Editor. Pharmacoeoeia. Revised edition 1996. Thiruvananthapuram; Kerala Government Ayurvedic Publications. p. 108.
33. Vagbhata. Ashtanga Hrudayam Utharasthanam (Malayalam) Commentary by Cheppatt Achutha variyar. 11th Reprint 2006. Sivakasi; Modern offset printers. p. 37.

Cite this article as:

Sreekumar.K, Arathi S Nair. Efficacy of Chedana and Lekhanakarma in Palpebral Form of Vernal Keratoconjunctivitis (VKC) – A Case Study. AYUSHDHARA, 2016;3(6):972-976.

Source of support: Nil, Conflict of interest: None Declared