

Received: 29 April 2020


Revised: 1 June 2020

Accepted: 3 June 2020

DOI: 10.1111/cge.13795

 Check for updates**SHORT REPORT** **WILEY**

# Expanding the phenotypic spectrum consequent upon de novo *WDR37* missense variants

Eleanor Hay<sup>1</sup> | Robert H. Henderson<sup>2,3</sup> | Sahar Mansour<sup>4</sup> | Charu Deshpande<sup>5</sup> | Rachel Jones<sup>5</sup> | Savita Nutan<sup>6</sup> | Kshitij Mankad<sup>7</sup> | Rodrigo M. Young<sup>3</sup> | Mariya Moosajee<sup>2,3,8</sup> | Genomics England Research Consortium<sup>9</sup> | Gavin Arno<sup>3,8</sup> 

<sup>1</sup>Department of Clinical Genetics, Great Ormond Street Hospital, London, UK

<sup>2</sup>Department of Ophthalmology, Great Ormond Street Hospital, London, UK

<sup>3</sup>University College London Institute of Ophthalmology, London, UK

<sup>4</sup>Department of Clinical Genetics, St George's Hospital, London, UK

<sup>5</sup>Department of Clinical Genetics, Guy's Hospital, London, UK

<sup>6</sup>London North Genomic Laboratory Hub, Great Ormond Street Hospital, London, UK

<sup>7</sup>Department of Neuroradiology, Great Ormond Street Hospital, London, UK

<sup>8</sup>Moorfields Eye Hospital NHS Foundation Trust, London, UK

<sup>9</sup>Genomics England, London, UK

**Correspondence**

Gavin Arno, University College London Institute of Ophthalmology, London, UK.  
Email: [g.arno@ucl.ac.uk](mailto:g.arno@ucl.ac.uk)

**Funding information**

Fight for Sight (UK), Grant/Award Number: 5045/46; National Institute for Health Research Biomedical Research Centre at Great Ormond Street Hospital Institute for Child Health; National Institute for Health Research Biomedical Research Centre at Moorfields Eye Hospital and UCL Institute of Ophthalmology

**Peer Review**

The peer review history for this article is available at <https://publons.com/publon/10.1111/cge.13795>.

**Abstract**

Structural eye disorders are increasingly recognised as having a genetic basis, although current genetic testing is limited in its success. *De novo* missense variants in *WDR37* are a recently described cause of a multisystemic syndromic disorder featuring ocular coloboma. This study characterises the phenotypic spectrum of this disorder and reports 2 *de novo* heterozygous variants (p.Thr115Ile, p.Ser119Tyr) in three unrelated Caucasian individuals. All had a clinical phenotype consisting of bilateral iris and retinal coloboma, developmental delay and additional, variable multisystem features. The variants fall within a highly conserved region upstream of the WD-repeat domains, within an apparent mutation cluster. Consistent with the literature, intellectual disability, structural eye disorders, epilepsy, congenital heart disease, genitorenal anomalies and dysmorphic facial features were observed. In addition, a broader developmental profile is reported with a more specific musculoskeletal phenotype described in association with the novel variant (p.Thr115Ile). We further expand the phenotypic spectrum of *WDR37*-related disorders to include those with milder developmental delay and strengthen the association of ocular coloboma and musculoskeletal features. We promote the inclusion of *WDR37* on gene panels for intellectual disability, epilepsy and structural eye disorders.

**KEYWORDS**

anterior segment disease, coloboma, developmental, molecular genetics

This is an open access article under the terms of the Creative Commons Attribution License, which permits use, distribution and reproduction in any medium, provided the original work is properly cited.

© 2020 The Authors. Clinical Genetics published by John Wiley & Sons Ltd.

## 1 | INTRODUCTION

Ocular coloboma has an estimated prevalence of 1 in 5000 live births<sup>1,2</sup> and may occur in isolation or form part of a multisystem syndromic disorder.<sup>3</sup> A significant proportion are likely to have a genetic aetiology, although diagnosis is impeded by incomplete penetrance, variable expressivity and genetic heterogeneity and only around 25% of syndromic forms have a clinically recognisable disorder.<sup>4,5</sup> Characterising the genetic aetiology of this diverse cohort is crucial to reduce the diagnostic odyssey, inform reproductive counselling and potentially alter management.

Recently, a total of seven unrelated individuals with four *de novo* missense mutations in *WDR37* were reported with a syndromic disorder featuring intellectual disability, epilepsy, craniofacial dysmorphism and developmental eye anomalies.<sup>6,7</sup> Here, we identify three individuals with *de novo* missense variants in *WDR37*, who present with syndromic features overlapping those reported. We further expand the phenotypic spectrum to include those with milder developmental delay and strengthen the association of *WDR37* variants with ocular coloboma and musculoskeletal features.

## 2 | MATERIALS AND METHODS

### 2.1 | Patients

Informed consent for Whole Genome Sequencing (WGS) was obtained in accordance with approval from the HRA Committee East of England—Cambridge South (REC Ref 14/EE/1112). Written, informed consent was taken for publication from the patient's legal guardians. Detailed phenotyping was undertaken by the recruiting physicians and authors of this study (details available on request).

### 2.2 | Sequencing and segregation analysis

Trio (each parent and child) WGS was performed through the Genomics England 100 000 Genomes Project (GE100KGP) as previously described.<sup>8</sup> From the undiagnosed dataset, rare, *de novo* variants predicted to have a protein altering affect were reviewed in individuals recruited with bilateral ocular coloboma. Alamut-v.2.6 (<https://www.interactive-biosoftware.com/alamut-visual/>) was utilised in variant interpretation. Variants were confirmed by interrogation of the individual paired-end reads using the Integrative Genomics Viewer (IGV).<sup>9</sup>

## 3 | RESULTS

### 3.1 | Clinical phenotyping

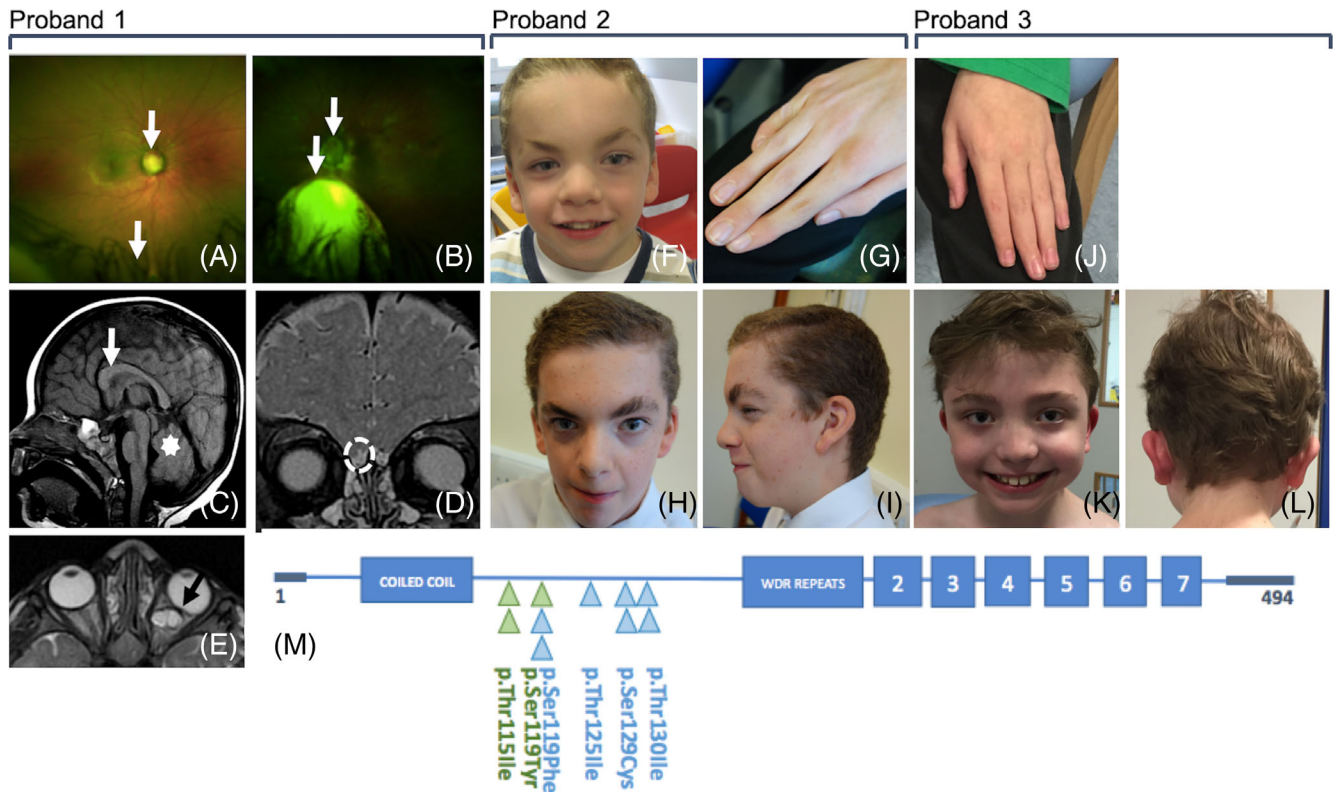
The three individuals were born at term following uncomplicated pregnancies. Family histories were uninformative and there was no

parental consanguinity. Ocular coloboma, low tone and delay in reaching developmental milestones were noted in all three from infancy and additional congenital anomalies prompted referral to ophthalmology and clinical genetics specialties. A range of investigations, including neurometabolic screening, brain MRI, skin biopsy, chromosome microarray (CMA) and varied genetic testing were performed and all were recruited to the GE100KGP. Clinical, neuroradiological and ophthalmic images are presented in Figure 1.

Proband 1, a 3-year-old girl, was noted to have a left iris coloboma at 2 weeks of age. Bilateral retinal and optic disc coloboma were later confirmed, alongside chorioretinal hyperpigmentation, left amblyopia and myopia (Figure 1A,B). She developed tonic-clonic seizures aged 11 months. Brain MRI showed the coloboma with extension into a left developmental cyst, mild corpus callosum and cerebellar vermian dysplasia (Figure 1C,D,E). At review, she had mild intellectual disability, long slender toes, brachycephaly and a unilateral duplex kidney, although no reported cardiac, genital or skeletal abnormalities. Growth parameters were tracking the 25th to 50th centiles. CMA revealed a small *de novo* 17q12 copy number gain of uncertain significance, involving eight genes. Smaller than the typical 17p12 microduplication region, this reduced penetrance neurosusceptibility locus is associated with wide ranging congenital anomalies (although not typically coloboma) in one third of individuals.<sup>10</sup>

Proband 2, a 15-year-old boy, had a perimembranous ventricular septal defect and borderline Tetralogy of Fallot identified as a neonate with a later identified mildly dilated aorta. He had a single febrile convulsion aged 2 years, moderate learning disability, autistic spectrum disorder and challenging feeding habits. Hypoplastic genitalia were identified at birth, although became less apparent with age, and he required operative repair of umbilical and left inguinal hernias and bilateral orchidopexy. Renal ultrasound was normal. At last review, he had bilateral iris and retinal coloboma, astigmatism, myopia and distinctive facial features (Figure 1F-I). He additionally had a broad neck, mild thoracolumbar scoliosis, pectus excavatum, long, slender fingers, joint hypermobility and ligament laxity. Growth parameters tracked the 25th to 50th centiles.

Proband 3, a 14-year-old boy, developed medication responsive seizures on day 10 of life. He discontinued antiepileptics aged 11 years and has remained seizure free with a normal EEG. His development was globally delayed and at review he had a moderate intellectual disability, four limb motor disorder, low central tone and an anxiety-induced tremor. Neurodevelopmental assessment was suggestive of a sensory processing disorder, reflected in his avoidant, restrictive food intake. He had a structurally normal heart and no known renal anomalies. A unilateral undescended testes and mild umbilical hernia/everted umbilicus were noted at birth. He had bilateral iris and retinal coloboma and astigmatism, brachycephaly and lambdoid and metopic synostosis. Distinctive facial features are documented in Figure 1K,L. He additionally had a broad neck, mild thoracic scoliosis, long, slender fingers, joint hypermobility and ligament laxity. Growth parameters tracked between the 9th and 25th centiles.



**FIGURE 1** Clinical and radiological features and WDR37 schematic. Probands 1 (A-E): Ocular images showing bilateral optic nerve coloboma and inferior chorioretinal coloboma (A, B, arrows). Brain MRI images (12 months) highlighting mild corpus callosum dysgenesis (C, arrow) and very mild superior cerebellar vermis dysplasia (C, star), hypoplastic olfactory nerves (D, right side encircled) and bilateral optic nerve coloboma with left developmental cyst (E, arrow). Probands 2 (F-I): Clinical images aged 7 years (F) and 13 years (H, I) showing prominent, interrupted eyebrows, broad nasal bridge, simple ears with thickened helices, wide mouth, thin upper lip, smooth philtrum and micrognathia. Probands 3 (J-L) aged 11 years showing prominent eyebrows, broad nasal bridge, thickened helices/lobes of the ears, wide mouth, thin upper lip, short philtrum, prominent central incisors and micrognathia. Connective tissue disorder features were observed in Probands 2 and 3, including long slender fingers (G, J). Simplified protein schematic (M-not to scale) highlights the colocalization of previously reported variants in unrelated individuals (blue triangles) and the three from this study (green triangles), between the coiled coil domain and seven WD40 repeats [Colour figure can be viewed at [wileyonlinelibrary.com](http://wileyonlinelibrary.com)]

WGS revealed a candidate *de novo* missense variant in WDR37, c.236C>A, p.(Ser119Tyr) (Figure 1M) in proband 1 following negative gene panel analysis. Similar analysis of proband 2 and 3 identified, in both, a novel *de novo* missense variant in WDR37, c.344C>T, p.(Thr115Ile) (Figure 1M). Both variants were absent from gnomAD, affected a highly conserved amino acid and were predicted to be damaging by *in silico* tools (SIFT, Polyphen2 and MutationTaster). The variants collocated to the same region of unknown function previously shown to harbour pathogenic variants, between the coiled coil domain and the WD40 repeats (Figure 1M).

Table 1 summarises the clinical features of our cases, alongside the previously reported individuals. All individuals had eye abnormalities with the majority (9/10) including ocular coloboma. Corneal/lens anomalies and astigmatism, were also common. Non-ocular head and neck features were frequently observed, with the most consistently reported dysmorphisms including broad nasal bridge (9/9), ear anomalies with low set and/or thickened helices (8/9), thin upper lip (7/8), smooth philtrum (6/7), broad or webbed neck (6/8), wide mouth (4/5)

and prominent or arched eyebrows (4/7). Microcephaly was present in five of nine reviewed.

Developmental delay and/or intellectual disability were universal and typically in the moderate to severe spectrum. 70% to 80% additionally had a seizure disorder of varying severity and central hypotonia. Of the individuals with MRI imaging, the most consistent features were hypoplasia of the cerebellar vermis (8/8) and corpus callosum (7/8). Musculoskeletal features from six individuals revealed five with hypermobility, joint laxity and/or joint dislocations, five with digital anomalies and four with scoliosis.

Challenging feeding was reported in 90% of cases and congenital heart disease in 70%, principally septal defects or persistent ductus arteriosus. 40% were reported to have structural renal anomalies and all five males had genital anomalies, predominantly undescended testes and micropenis.

Our cohort's neurodevelopmental phenotype was less severe overall, with the youngest showing only mild intellectual disability and minor, although consistent MRI changes. Growth parameters in all three were within the normal range. Whilst no consistent genotype to

**TABLE 1** Clinical features of individuals with heterozygous de novo missense variants in WDR37 identified in this study, compared with those previously reported in medical literature [R1-R3 (Proband 1-3 in Reference 6) and K2-K5 (Proband 2-5 in Reference 7)]

	P1	P2	P3	R1	R2	R3	K2	K3	K4	K5
Variant details	c.356C>A p.Ser119Tyr	c.344C>T p.Thr115Ile	c.344C>T p.Thr115Ile	c.356C>T p.Ser119Phe	c.389C>T p.Thr130Ile	c.374C>T p.Thr125Ile	c.386C>G p.Ser129Cys	c.356C>T p.Ser119Phe	c.386C>G p.Ser129Cys	c.389C>T p.Thr130Ile
Age at review	3 y	14 y	15 y	30 y	22 mo	8 y	6 y	8 mo	19 y	4 wk
<b>Ocular features</b>										
Iris coloboma	+ (UL)	+ (BL)	+ (BL)	+ (UL)	+ (BL)	+ (BL)	+ (UL)	+ (BL)	+ (BL)	-
Retinal coloboma	+ (BL)	+ (BL)	+ (BL)	-	+ (BL)	+ (BL)	+ (BL)	+ (BL)	+ (BL)	-
Optic nerve coloboma	+ (BL)	-	-	-	+ (BL)	+ (BL)	-	+ (BL)	+ (BL)	-
Microphthalmia	-	-	-	-	+	-	+	-	-	+
Small or cloudy cornea	-	-	-	+	+	+ (Peters)	-	-	-	+
Lens defect	-	-	-	+	+	+	-	-	-	+
Astigmatism	-	+	+	u	u	+	u	u	u	u
<b>Head and neck features (non-ocular) features</b>										
Microcephaly	-	-	-	+	+	+	+	-	+	u
Craniosynostosis	-	-	+	-	+	-	-	u	-	u
Micrognathia	-	+	+	-	+	-	-	u	-	u
Prominent eyebrows	u	+	+	+ (arched)	u	+ (arched)	-	-	?	u
Wide mouth	u	+	+	+	u	u	-	u	+	u
Thin upper lip	u	+	+	+	+	+	+	+	-	u
High arch palate	u	+	+	u	u	+	u	u	u	u
Broad nasal bridge	u	+	+	+	+	+	+	+	+	+
Ear anomalies	u	+	+	+	+	+	+	+	-	+
Web/broad neck	u	+	+	u	+	+	-	+	-	+
Hypertelorism	-	+	-	-	-	u	+	+	-	-
Sensorineural hearing loss	-	-	-	u	u	-(cond)	+	-	-	u
Smooth philtrum	u	+	-	u	+	+	+	+	+	u
<b>Neurological and developmental features</b>										
Seizures	+	-	+ (feb x1)	+	+	+	+	+	+	+
Developmental delay	+	+	+	+	+	+	+	+	+	+
Intellectual disability	+	+ (mod)	+ (mod)	+ (sev)	+ (sev)	+ (sev)	+ (sev)	NA	+ (sev)	NA
Autistic spectrum	NA	+	+	u	NA	u	u	NA	u	NA
Central hypotonia	-	+	+	+	+	u	+	+	+	-
Absent speech	-	-	-	+	+	+	+	NA	+	NA
Abnormal gyration	-	NA	NA	-	+	+	+	NA	+	+

TABLE 1 (Continued)

	P1	P2	P3	R1	R2	R3	K2	K3	K4	K5
Delayed myelination	-	NA	NA	+	+	+	u	u	u	u
AbN corpus callosum	+ (mild)	NA	NA	-	+	+	+	+	+	+
AbN cerebellar vermis/	+ (mild)	NA	NA	+	+	+	+	+	+	+
Dandy Walker variant	-	NA	NA	+	+	+	-	-	-	-
Connective tissue and skeletal anomalies										
Hypermobility	+	+	+	u	u	u	u	u	u	u
Joint laxity/dislocations	u	+	+	+	u	+	+	u	u	u
Scoliosis	-	+	+	+	+	u	u	u	u	u
Pectus anomaly	-	+	-	+	u	u	u	u	u	u
Syndactyly	-	-	-	-	+	+	u	u	u	u
Contractures	-	-	-	+	+	+	u	u	u	u
Long digits	u	+	+	-	- taper	u	u	u	u	u
Abdominal hernia	-	+	-	u	u	u	u	u	u	u
Cardiovascular anomalies										
Septal defect (ASD/VSD)	-	+ (TOF)	-	+	+	-	+	+	-	+
PDA	-	-	-	+	-	+	+	+	-	-
Aortic root dilation	u	+ (mild)	u	u	u	u	u	u	u	u
Genitourinary anomalies										
Structural renal	+	-	-	u	+	+	u	u	+	u
Undescended testes	NA	+	+	+	NA	+	NA	NA	NA	+
Micropenis	NA	+	u	+	NA	+	NA	NA	NA	+
Other features										
Feeding issues	-	+	+	+	+	+	+	+	+	+
Intestinal malrotation	-	-	-	-	-	+	-	-	-	-

Abbreviations: ASD, Atrial Septal Defect; BL, bilateral; cond, conductive; feb, febrile; mod, moderate; NA, not applicable; PDA, Patent ductus arteriosus; sev, severe; TOF, tetralogy of Fallot; u, unknown; UL, unilateral; VSD, Ventricular septal defect.

phenotype correlation was evident, the two probands in our study with the same variant had a more specific musculoskeletal phenotype.

## 4 | DISCUSSION

The WDR37 protein belongs to the WD40 domain-containing protein family, comprising around 1% of the human proteome.<sup>11</sup> Their seven-blade structures have roles in protein-protein interaction and molecular recognition in widespread biological processes, including transcription regulation, signal transduction and histone modification.<sup>12</sup> Over 60 WD40 proteins are classified as OMIM morbid, with dominant and recessive inheritance recognised.

To date, there are 10 unrelated probands reported with six de novo missense variants in WDR37 upstream of the WD repeats (Figure 1M). This region is highly conserved with complete sequence homology (residues 107-137) from zebrafish to human. The probability of loss of function intolerance (pLI) of WDR37 is 0.57<sup>13</sup> (<http://gnomad.broadinstitute.org/>) and 70 patients in Decipher (<https://decipher.sanger.ac.uk>) have heterozygous deletions inclusive of WDR37, suggesting a haploinsufficient model of disease is unlikely. The effect of the missense variants is as yet unknown but they may alter the protein conformation, potentially adding an additional propeller blade.<sup>7</sup> Of note, there is one individual in gnomAD with p.Ser119Pro, a presumed benign variant at the same residue as three affected individuals (p.Ser119Tyr and p.Ser119Phe), suggesting the effect may be residue specific.

The International Mouse Phenotyping Consortium (IMPC), showed murine *Wdr37* knockout to have proportionately decreased overall body weight, abnormal spinal curvature, decreased grip strength and biochemical/haematological disturbance.<sup>14</sup> Reis et al reported a detrimental effect on growth and viability of zebrafish with missense *wdr37* variants, as opposed to the minimal effects observed with heterozygous frameshift variants.<sup>6</sup> Kanca et al recapitulated the results of the IMPC in drosophila, with knockout flies showing significant bang sensitivity (analogous to human seizures) and lower grip strength.<sup>7</sup>

Similar to other syndromic eye disorders, there is a broad phenotypic spectrum in WDR37-disease. This study supports the key phenotypic features previously reported with WDR37 variants, broadens the clinical spectrum to include those with a milder neurodevelopmental and radiological phenotype and highlights a more significant connective tissue like phenotype with joint hypermobility, hernias and aortic root dilatation (in one) in association with p.Thr115Ile. Further work is required to establish the full phenotypic range of individuals with WDR37 variants.

Inclusion of WDR37 to relevant diagnostic panels will improve diagnostic yield in the syndromic developmental eye disorder cohort, essential in providing accurate reproductive risk to couples, reducing unnecessary investigations and ensuring early renal and cardiac assessment to look for associated systemic features. Given the broad spectrum of clinical presentation, WDR37 variants should be

considered in patients presenting with multisystem syndromic disorders, intellectual disability, epilepsy and anterior segment anomalies, particularly ocular coloboma.

## ACKNOWLEDGEMENTS

We thank the families for their contribution and support. This study was funded by the NIHR-BRC at Great Ormond Street Hospital, NIHR-BRC at Moorfields Eye Hospital and UCL Institute of Ophthalmology. GA is supported by a Fight for Sight (UK) Early Career Investigator Award. This research was made possible through access to the data and findings generated by the GE100KGP.

## CONFLICT OF INTEREST

The authors declare no conflicts of interest.

## DATA AVAILABILITY STATEMENT

The genome data is available in the GE100KGP data safe haven. Clinical data and imaging are stored within the respective NHS trust's electronic patient records.

## ORCID

Gavin Arno  <https://orcid.org/0000-0002-6165-7888>

## REFERENCES

- Morrison D, FitzPatrick D, Hanson I, et al. National study of microphthalmia, anophthalmia, and coloboma (MAC) in Scotland: investigation of genetic aetiology. *J Med Genet.* 2002;39(1):16-22.
- Nakamura KM, Diehl NN, Mohny BG. Incidence, ocular findings, and systemic associations of ocular coloboma: a population-based study. *Arch Ophthalmol.* 2011;129(1):69-74.
- Williamson KA, FitzPatrick DR. The genetic architecture of microphthalmia, anophthalmia and coloboma. *Eur J Med Genet.* 2014;57(8):369-380.
- Skalicky SE, White AJ, Grigg JR, et al. Microphthalmia, anophthalmia, and coloboma and associated ocular and systemic features: understanding the spectrum. *JAMA Ophthalmol.* 2013;131(12):1517-1524.
- Deml B, Reis LM, Lemyre E, Clark RD, Kariminejad A, Semina EV. Novel mutations in PAX6, OTX2 and NDP in anophthalmia, microphthalmia and coloboma. *Eur J Hum Genet.* 2016;24(4):535-541.
- Reis LM, Sorokina EA, Thompson S, et al. De novo missense variants in WDR37 cause a severe multisystemic syndrome. *Am J Hum Genet.* 2019;105(2):425-433.
- Kanca O, Andrews JC, Lee PT, et al. De novo variants in WDR37 are associated with epilepsy, Colobomas, Dysmorphism, developmental delay, intellectual disability, and cerebellar hypoplasia. *Am J Hum Genet.* 2019;105(3):672-674.
- Taylor RL, Arno G, Poulter JA, et al. Association of Steroid 5alpha-Reductase type 3 congenital disorder of glycosylation with early-onset retinal dystrophy. *JAMA Ophthalmol.* 2017;135(4):339-347.
- Robinson JT, Thorvaldsdottir H, Wenger AM, Zehir A, Mesirov JP. Variant review with the integrative genomics viewer. *Cancer Res.* 2017;77(21):e31-e34.
- Mitchell E, Douglas A, Kjaegaard S, et al. Recurrent duplications of 17q12 associated with variable phenotypes. *Am J Med Genet A.* 2015;167A(12):3038-3045.
- Stirnemann CU, Petsalaki E, Russell RB, Muller CW. WD40 proteins propel cellular networks. *Trends Biochem Sci.* 2010;35(10):565-574.

12. Zou XD, Hu XJ, Ma J, Li T, Ye ZQ, Wu YD. Genome-wide analysis of WD40 protein family in human. *Sci Rep.* 2016;6:39262.
13. Karczewski KJ, Francioli LC, Tiao G, et al. The mutational constraint spectrum quantified from variation in 141,456 humans. *Nature.* 2020; 581(7809):434–443.
14. Dickinson ME, Flenniken AM, Ji X, et al. High-throughput discovery of novel developmental phenotypes. *Nature.* 2016;537(7621): 508–514.

**How to cite this article:** Hay E, Henderson RH, Mansour S, et al. Expanding the phenotypic spectrum consequent upon de novo WDR37 missense variants. *Clin Genet.* 2020;98: 191–197. <https://doi.org/10.1111/cge.13795>