

THE DISTRIBUTION OF PHOSPHORUS IN THE HUMERUS OF THE WHITE RAT  
(RATTUS NORVEGICUS ALBINUS) WHOSE GROWTH HAS BEEN ACCELER-  
ATED BY GROWTH HORMONE. III. TWELVE HOURS AFTER  
A SINGLE INJECTION OF RADIOACTIVE PHOSPHORUS

by

ROBERT LOUIS SALISBURY  
B. S., Ottawa University, 1952

---

A THESIS

submitted in partial fulfillment of the

requirements for the degree

MASTER OF SCIENCE

Department of Zoology

KANSAS STATE COLLEGE  
OF AGRICULTURE AND APPLIED SCIENCE

1953

Docu-  
ment  
LD  
2668  
T4  
1953  
S25  
C.2.

TABLE OF CONTENTS

INTRODUCTION AND REVIEW OF LITERATURE .....	1
MATERIALS AND METHODS .....	6
EXPERIMENTAL RESULTS .....	15
DISCUSSION .....	27
SUMMARY .....	28
ACKNOWLEDGMENT .....	30
BIBLIOGRAPHY .....	31

## INTRODUCTION AND REVIEW OF LITERATURE

Phosphorus is found in all parts of the body combined with other elements to form both organic and inorganic compounds. Approximately 80 percent of the phosphorus in the body is found in the bones and teeth in combination with calcium.

The bones serve not only as supportive structures but also as storage sites of calcium and phosphorus which may be mobilized at times when the assimilation of those minerals is inadequate to meet bodily needs. Therefore the mineral metabolism of the bone involves not only the deposition of calcium and phosphorus during growth, but also processes of storage and mobilization which occur throughout life.

Atomic energy has been successfully employed in various phases of research especially using radioactive isotopes of elements that are biologically important. One of the more common of the isotopes used as tracers is radioactive phosphorus, atomic weight 32. Phosphorus 32 has a half-life of 14.3 days. This makes its use more desirable than some of the other isotopes for the disposal problem is not difficult. This also enables the researcher to carry out his experiment without due haste.

In a typical long bone such as the humerus, the diaphysis or shaft consists of a cylindrical mass of compact bone surrounding a central cavity filled with fatty bone marrow. The epiphysis is the portion of the bone that in early life is distinct from the shaft. It is separated from the diaphysis by the epiphyseal

cartilage plate, which is united with the relatively compact bone of the diaphysis by trabeculae of spongy bone, often referred to as the metaphysis. The epiphyseal cartilage, together with the spongy bone of the metaphysis, forms a growth apparatus responsible for the growth in length of the long bones. When the cells of the epiphyseal cartilage place cease to multiply, the cartilage becomes entirely replaced by bone, the epiphysis unites with the diaphysis, and growth ceases. This is commonly referred to as the closing of the epiphysis. The modified connective tissue that covers bone is the periosteum. It is in the deeper layers of the periosteum, that undifferentiated mesodermal elements differentiate into osteoblasts, and bone is deposited subperiosteally, resulting in an increase in the bone diameter. A somewhat similar tissue, the endosteum lines the marrow spaces, including those in spongy bones.

The meshwork of trabeculae of the spongy bone constitute a reserve of calcium and phosphorus which may be mobilized to meet needs not currently supplied by the diet. The work of Bauer, Aub, and Albright (1929) has shown this clearly. The trabeculae are most numerous at the epiphyseal ends of the bone where the blood supply is the greatest. During the time when the mineral salts are used from the trabeculae for rapid growth, there seems to be no physiological harm done. Their mineral content is readily restored with an adequate diet during periods when bodily need for these materials is lower.

There is a constant interchange of calcium between blood and

the bones resulting in a fairly constant calcium ion concentration in the plasma. The interstitial substance of any bone acts as a storage place for the calcium. Calcium, once deposited in the form of bone salts, may be available to the blood only by destruction of osseous tissue; for the most part, that of the spongy bones near the epiphysis of the long bones.

Silberberg and Silberberg (1941) indicated that the growth of bone is markedly influenced by the growth hormone of the anterior pituitary gland. They stated that anterior pituitary extracts accelerate and intensify the processes of skeletal ageing by a temporary stimulation of the proliferation of cartilage in growing animals. This is associated with a shortening of the growth period.

Hyperpituitarism, an overactivity of the anterior lobe of the pituitary gland, may occur either during childhood or any time during adult life. If overactivity of the anterior lobe of the pituitary gland occurs during adult life, after union of the epiphysis and diaphysis has taken place and bone length has been fixed, the bones cannot further increase in length. A subperiosteal ossification may take place, resulting in a thickening of the bones which is especially noticeable in the face, feet, and hands. This enlargement of the extremities is known as acromegaly. Giantism results when hyperpituitarism takes place in childhood before the closure of the epiphysis takes place.

Evans and Long (1921) first induced giantism experimentally in the rat by injection of extracts from the anterior pituitary

gland. A growth-promoting hormone in the extract was thought to be the cause of the excessive growth produced. The isolation of the pure growth hormone was accomplished by Li, Evans, and Simpson (1945) and the phenomenon of an overgrowth of the normal body was steadily confirmed (Evans, Simpson, Li, 1948). Additional work by Evans, et al. (1948) found that continued daily injection of growth hormone into normal "plateaued" female rats resulted in continuous growth for a 437 day period. This growth rate was not, however, as rapid at the end of the period as at the beginning.

Evans, et al. (1948) illustrated that rats injected with growth hormone were significantly longer than controls; both trunk and tail contributed to this increase in length. The injected animals had larger skulls and greater size of the thoracic cage, pelvis, vertebral column, tail, and long bones. Skeletal growth was continuing slowly at the end of the 437 day period of daily injection of growth hormone.

Pecher (1941) in experiments in the deposition of radioactive isotopes of calcium and strontium has shown that the distribution of these two elements in body tissues is similar. In the work of Marx and Reinhardt (1942) it was found that growth hormone did not affect the total amount of strontium deposited in the mandible and femur of hypophysectomized rats.

It was first shown by Teel and Watkins (1929) and later by others<sup>1</sup> that growth hormone produces an increase in the inorganic

---

<sup>1</sup> Anderson, Oastler (1938); Li, Geschwind, Evans (1949); Reifenstein, Kinsell, Albright (1946).



phosphorus of the blood and hypophysectomy causes a sharp reduction of this level.

Manly and Bale (1939) found that there is normally a rapid deposition of blood phosphorus in the bones. The epiphysis acquired almost twice as much of the radioactive phosphorus per gram of inorganic tissue as the diaphysis in the first day following administration. These findings confirmed and extended the work of Hahn, Hevesy, and Lundsgaard (1937). Former workers also showed that the diaphysis had greater retention of acquired phosphorus after the labeled phosphorus in the blood had fallen to negligible amounts.

The material reviewed brings out the possibility that growth hormone may be influential in the metabolism of inorganic phosphorus in bone. This experiment was carried on as a phase of investigations begun by Buchholtz (1950) and Kaufman (1950) considering the role of growth hormone in accelerating the growth of bone. Previous studies by Buchholtz and Kaufman considered the site of phosphorus 32 in growth hormone injected rats and in control rats 19 and 80 hours after a single injection of phosphorus 32. The present problem was to consider the site of phosphorus at an earlier time, namely 12 hours after a single injection of radioactive phosphorus.

## MATERIALS AND METHODS

White Wister rats that had been interbred for several generations were used in this experiment.

The animals were given Purina Dog Chow in the checkered form. This diet contained all of the necessary nutrients for normal growth. Small quantities of lettuce and carrots added to the diet of pregnant animals seemed to aid in the health of the litter. Water was available to the animals at all times from bottles attached to the side of each cage.

For this phase of the project eight animals of approximately the same age were selected and ranged from 82 days to 108 days old. The average age of the animals at the first injection of growth hormone was 91 days old.

The animals were segregated as to sex and divided into groups, and, for identification purposes, were colored with dilute solutions of picric acid, gentian violet, methylene blue, and aceto-carmines dyes.

Rats numbering one through four were experimentals and were injected with growth hormone and radioactive phosphorus. Rats numbering 17 through 20 were injected only with the radioactive phosphorus and were maintained as controls.

The experimentals were injected with one rat unit of growth hormone, twice daily for four days beginning on April 24, 1953, and ending on April 29, 1953.

The growth hormone was generously supplied by the Parke-



Davis Company, Inc. and was prepared for injection by dissolving a quantity of the powdered hormone in a sodium hydroxide solution of a pH of 10.0. When the powdered hormone was completely dissolved, the pH of the solution was determined with a Coleman potentiometer and the solution was adjusted to a pH of 9.0 by the addition of a phosphoric acid solution at a pH of 6.0. Injections were made intraperitoneally.

On April 29, 1953, all rats were injected with approximately 50 microcuries of radioactive phosphorus obtained from the Atomic Energy Commission and prepared as a solution of disodium monohydrogen phosphate. The dilution was made by the isotope laboratory at Kansas State College. These injections were made intraperitoneally also. Various safety precautions as suggested by the Atomic Energy Commission were followed at all times while working with the radioactive material.

The animals were sacrificed by chloroforming them. The legs were removed and the bones scraped free of excess flesh before immersion in 99 percent isopropyl alcohol. Other tissues to be examined at a later date were placed in Bouin's fixative.

The bones used in this study were the right and left humeri of each rat together with the proximal portion of the ulna and radius, still articulated with the humerus.

Since decalcification in the ordinary celloidin method of bone sectioning would remove phosphate salts and thus the radioactive phosphorus, the bones were imbedded in bioplastic and sectioned according to the method of Buchholtz and Kaufman (1950).

The bones were transferred from the 99 percent alcohol to anhydrous ether and kept there for several hours. Following this immersion they were transferred to individual glass dishes containing uncatalyzed bioplastic and allowed to infiltrate for approximately 24 hours. During this time the specimens were subjected alternately to a vacuum in a vacuum desiccator and warming in a paraffin oven to remove the ether.

While the bones were being prepared for imbedding, a mixture of catalyzed monomer was prepared to form a supporting layer for the tissue. One drop of catalyst was used to every 10 cubic centimeters of plastic. For this work Ward's Bioplastic was used. The catalyzed mixture was poured into a refrigerator ice-cube tray that had been thoroughly coated inside with petroleum jelly to prevent any sticking of the plastic blocks to the sides of the tray. The basement layer of plastic was allowed to partially harden during the infiltration period aided by slight warmings in a paraffin oven. The bones were then transferred from the uncatalyzed monomer to the basement plastic layer in the ice-cube tray and additional catalyzed plastic was poured over the bones to completely cover them. Within 30 hours after being placed in the catalyzed monomer and kept in a paraffin oven for most of the time, the blocks of plastic hardened thoroughly and shrank from the sides of the tray, facilitating their removal. Any petroleum jelly left on the cubes was easily removed with a dry cloth. With the aid of a coping saw and an electric grinder the cubes were cut down and sanded so that there was only a thin shell of

plastic remaining around the bone. At the distal end an excess of plastic was left to facilitate clamping the block of tissue into the jaws of the microtome, for sectioning.

A slight modification was made of the sectioning method used by Buchholtz and Kaufman. An ordinary microtome minus the knife and knife-holder was used to hold, and to advance the block of tissue. An assembly holding a fractional horsepower motor with a circular saw mounted on its shaft was used for making the bone sections. Both the motor assembly and the microtome were fitted to a board surface to eliminate any unnecessary movement of the apparatus. As the block containing the imbedded bone moved downward over the saw, a thin section of the block was sawed off.

The cut sections of a uniform thickness of 500 micra were placed on celluloid strips which had been cut to a size of one inch by three inches. Four and sometimes five sections were placed in this manner on each of the celluloid strips. Acetone was allowed to seep under the sections and dissolved some of the plastic which remained around the bone section. The acetone on contact with the celluloid dissolved a slight amount of the latter and the subsequent evaporation of the acetone left the bone section firmly attached to the celluloid strip.

After sectioning, the celluloid strips containing the bone sections were placed in contact with the emulsion of Eastman Kodak Portrait Panchromatic photographic film. This type of film was selected by Buchholz (1950) and Kaufman (1950) because it gave a high resolution to the radioautograph. The film was cut

to the same size as the strips of celluloid. The end of the film strip and the end of the celluloid strip were then cemented together using Le Page's airplane cement. The bond on this film-celluloid joint was found to be quite weak so that subsequently the film was fixed to the end of the celluloid strip by stapling with metal staples, using an ordinary paper stapler.

The film-bone-celluloid strips were next placed in a specially constructed light-proof box with a one-quarter inch layer of cotton directly over the film. Next, a sheet of bakelite was used as a separator between layers. These layers were repeated, one on top of the other, until all of the strips were stacked. On top of each stack pieces of lead were placed to serve as additional weights. In this manner intimate contact between the bone sections and film emulsion was assured. The top of the light-proof box was replaced and the box with its contents was set aside.

After an exposure of approximately 15 days, the film was developed by ordinary photographic processes using Kodak D-50 developer. In order to avoid unnecessary immersion of the bone sections in the developing solutions, a special carrier was devised (Plate I). This consisted of a piece of Prestwood of suitable size to fit over the developer and fixative tanks. Slots were made in the Prestwood to accommodate the film, and the celluloid "slides" were spaced apart by wire brads. This made insertion of the film into the slot easier in the dark.

EXPLANATION OF PLATE I

Carrier devised to hold slides during processing  
of exposed film.

## PLATE I






EXPLANATION OF PLATE II

View of microtome-saw assembly. Plastic block holding tissue against face of saw disc.

## PLATE II



Enlargements were made of radioautographs of bone sections through similar regions of the humeri of control and experimental rats of both sexes. This afforded a more detailed study of the two and made it possible to determine more exactly the localization of the radioactive phosphorus. In addition, photomicrographs were made of corresponding bone sections.

#### EXPERIMENTAL RESULTS

The animals considered in this experiment were sacrificed 12 hours after injection of radioactive phosphorus.

The radioautographs of the bone sections of rats injected with the growth hormone were markedly different from those of the controls.

In comparison to radioautograph (Plate III, Fig. 4) of a cross-section of the proximal half of the right humerus from a non-growth hormone injected rat, a radioautograph (Plate III, Fig. 2) of a similar section of a growth hormone injected rat, shows a higher concentration of the isotope in the periosteum especially at the site of the ossification center of the greater tubercle and of the crest, both regions of increased bone deposition. There is a small but still noticeable concentration of the phosphorus in the region of the endosteum of the hormone injected rat. In the non-injected control, it is evident that most of the phosphorus is in the region of the endosteum.

In Plate IV, Fig. 2, the radioautograph enlargement of a

cross-section of the distal half of the diaphysis of the left humerus of a growth hormone injected rat shows that there was a high concentration of the phosphate in the periosteum. A similar bone section (Plate IV, Fig. 3) from a non-growth hormone injected rat had most phosphorus deposited in the endosteum as shown in Plate IV, Fig. 4.

A comparison of the radioautographs of humeri of experimental and control animals in Plates V, VI, and VII shows results comparable to those discussed for Plates III and IV. These plates show representative examples of the many radioautographs prepared for this experiment.

### EXPLANATION OF PLATE III

Positives of photomicrographs of bone sections and enlargements of radioautographs made from rats sacrificed 12 hours after injection of radiophosphorus.

1. Photomicrograph of section 2 of the proximal half of the right humerus of a growth hormone injected rat, No. 1.
  - a. The periosteum.
  - b. The endosteum.
  - c. Osseous tissue.
2. The radioautograph of the bone section shown in Fig. 1.
3. Photomicrograph of section 8 of the proximal half of the right humerus of a non-growth hormone injected rat, No. 20.
  - a. The periosteum.
  - b. The endosteum.
  - c. Osseous tissue.
4. The radioautograph of the bone section shown in Fig. 3.

## PLATE III



Fig. 1



Fig. 2



Fig. 3



Fig. 4



#### EXPLANATION OF PLATE IV

Positives of photomicrographs of bone sections and enlargements of radioautographs made from rats sacrificed 12 hours after injection of radiophosphorus.

1. Photomicrograph of section 12 of the distal half of the diaphysis of the left humerus of a growth hormone injected rat, No. 3.
  - a. The periosteum.
  - b. The endosteum.
  - c. Osseous tissue.
2. The radioautograph of the bone section shown in Fig. 1.
3. Photomicrograph of section 2 of the distal half of the diaphysis of the right humerus of a non-growth hormone injected rat, No. 18.
  - a. The periosteum.
  - b. The endosteum.
  - c. Osseous tissue.
4. The radioautograph of the bone section shown in Fig. 3.

## PLATE IV



Fig. 1



Fig. 2

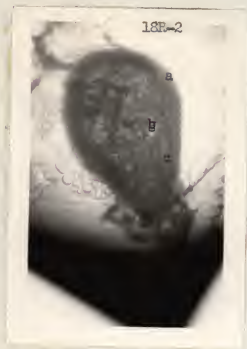

Fig. 3



Fig. 4

#### EXPLANATION OF PLATE V

Positives of photomicrographs of bone sections and enlargements of radioautographs made from rats sacrificed 12 hours after injection of radiophosphorus.

1. Photomicrograph of section 4 of the proximal half of the diaphysis of the right humerus of a growth hormone injected rat, No. 3.
  - a. The periosteum.
  - b. The endosteum.
  - c. Osseous tissue.
2. The radioautograph of the bone section shown in Fig. 1.
3. Photomicrograph of section 5 of the proximal half of the diaphysis of the left humerus of a non-growth hormone injected rat, No. 18.
  - a. The periosteum.
  - b. The endosteum.
  - c. Osseous tissue.
4. The radioautograph of the bone section shown in Fig. 3.

## PLATE V

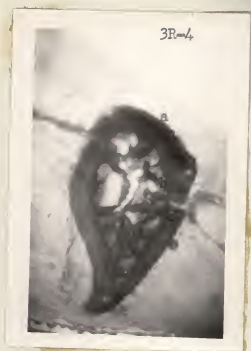

Fig. 1



Fig. 2



Fig. 3



Fig. 4

#### EXPLANATION OF PLATE VI

Positives of photomicrographs of bone sections and enlargements of radioautographs made from rats sacrificed 12 hours after injection of radiophosphorus.

1. Photomicrograph of section 14 of the distal half of the right humerus of a growth hormone injected rat, No. 4.
  - a. The periosteum.
  - b. The endosteum.
  - c. Osseous tissue.(Break in section occurred subsequent to exposure of radioautograph, Fig. 2.)
2. The radioautograph of the bone section shown in Fig. 1.
3. Photomicrograph of section 7 of the distal half of the left humerus of a non-growth hormone injected rat, No. 18.
  - a. The periosteum.
  - b. The endosteum.
  - c. Osseous tissue.
4. The radioautograph of the bone section shown in Fig. 3.

## PLATE VI



Fig. 1



Fig. 2



Fig. 3



Fig. 4



## EXPLANATION OF PLATE VII

Positive of photomicrographs of bone sections and enlargements of radioautographs made from rats sacrificed 12 hours after injection of radiophosphorus.

1. Photomicrograph of section 4 of the proximal half of the right humerus of a growth hormone injected rat, No. 2.
  - a. The periosteum.
  - b. The epiphyseal line.
  - c. Osseous tissue.
2. The radioautograph of the bone section shown in Fig. 1.
3. Photomicrograph of section 1 of the proximal half of the left humerus of a non-growth hormone injected rat, No. 17.
  - a. The periosteum.
  - b. The epiphyseal line.
  - c. Osseous tissue.
4. The radioautograph of the bone section shown in Fig. 3.

## PLATE VII



Fig. 1

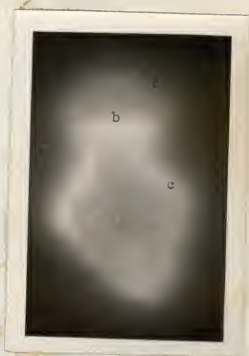

Fig. 2

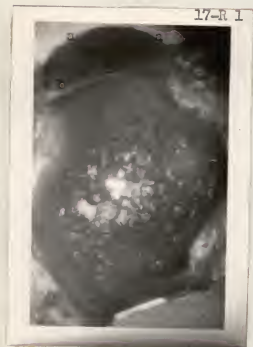

Fig. 3



Fig. 4

## DISCUSSION

The radioautographs extend and confirm what is known of bone phosphorus metabolism. Previous work (Hahn, Hevesy, and Lunds-gaard, 1937) has shown that phosphorus is first stored in the epiphysis and endosteum. This phosphorus is then remobilized and deposited in the epiphyseal line, the diaphysis, and the perios-teum during bone growth.

Since bone deposition involves the utilization of phosphates, the presence of increased amounts of radioactive phosphorus at the sites of deposition will indicate such activity. Growth hor-mone is known to accelerate growth and by making use of the processes responsible for gross manifestations of growth, the elongation of the bones, is best suited to demonstrate the activ-ity of the hormone. The results of the experiment indicate that this is true.

Time appears to be an important factor in the distribution of phosphorus in growing rats. The phosphorus 32 injections made by Kaufman (1950) showed that 80 hours after injection the process of phosphorus mobilization in growth hormone injected rats con-tinued, as was indicated by a very marked area of the phosphorus under the periosteum. Much more activity of phosphorus mobiliza-tion was shown at 80 hours after isotope injection than at 12 or 19 hours following phosphorus 32 injections in growth hormone in-jected animals.

In rats whose growth had been accelerated by growth hormone,

the distribution of the phosphorus appears concentrated under the periosteum and in the epiphyseal disc. In control rats the phosphorus appeared concentrated somewhat in the region of the endosteum or diffused throughout the epiphysis and metaphysis. There was a mobilization of the phosphorus from the sites it occupied in the control rats to the regions of accelerated bone growth in the experimentals as shown in Plates III, Fig. 2; IV, Fig. 2; V, Fig. 2; VI, Fig. 2; and VII, Fig. 2.

The results of this work indicate that growth hormone does accelerate the mobilization of the bone phosphorus, and that the greatest activity appears at the sites where new bone is formed. This occurs under the periosteum and along the epiphyseal plate in young animals when growth is accelerated by injection of growth hormone of the anterior lobe of the pituitary gland.

Evidence of a differential rate of phosphorus metabolism in animals injected with growth hormone as compared with those not injected can be detected as early as 12 hours after an injection of phosphorus 32.

#### SUMMARY

1. The radioactive isotope, phosphorus 32, and the growth stimulating hormone of the anterior pituitary gland were used in an experiment to determine the effect of the hormone on the mobilization of bone phosphorus.
2. White rats (*Rattus norvegicus albinus*) were selected and

grouped for the purposes of injection with the substances used.

3. Growth hormone was injected twice daily for four days followed by a single intraperitoneal injection of approximately 50 microcuries of radioactive phosphorus on the fifth day.

4. The rats studied were sacrificed 12 hours after the isotone injection.

5. Humeri of experimental and control animals were imbedded in Bioplastic and cross-sections were made of the right and left humeri of each rat.

6. The bone sections were mounted on celluloid "slides" and placed in contact with photographic emulsion for the production of radioautographs.

7. Photomicrographs of the bone sections and enlargements of the radioautographs were made.

8. Comparison of the photomicrographs and radioautograph enlargements indicates that within 12 hours after injection of the radioactive phosphorus, growth hormone begins to accelerate the mobilization of phosphorus from the epiphysis and endosteum to the epiphyseal line and the sub-periosteal bone of the diaphysis.

## ACKNOWLEDGMENT

The author expresses his sincere appreciation to his major adviser, Dr. Edward J. Wimmer, for suggesting the problem and for his assistance during the course of the experiment; to Dr. Robert H. MacFarland and Dr. Richard E. Hein of the Kansas State College Isotope Laboratory for their technical assistance; and to Parke-Davis and Company for the donation of the growth hormone.



## BIBLIOGRAPHY

- Anderson, A. B., and E. G. Oastler.  
The effect of hypophysectomy on the blood calcium and phosphorus of the rat. *Jour. Physiol.* 92:124. 1938.
- Bauer, Walter, J. C. Aub, and F. Albright.  
Studies of calcium and phosphorus metabolism. V. A study of the bone trabeculae as a readily available reserve supply of calcium. *Jour. Expt. Med.* 49:145-161. 1929.
- Buchholz, Robert H.  
The distribution of phosphorus in some bones of the white rat (*Rattus Norvegicus Albinus*) whose growth has been accelerated by growth hormone. I. 19 hours after a single injection of radioactive phosphorus. Unpublished Master's thesis, Kansas State College, Manhattan, Kansas. 1950.
- Evans, H. M., and J. A. Long.  
The effect of the anterior lobe administered intraperitoneally upon growth, maturity and oestrous cycles of the rat. *Anat. Rec.* 21:62-63. 1921.
- Evans, H. M., H. Becks, C. W. Asling, M. E. Simpson, and C. H. Li.  
The gigantism produced in normal rats by injection of the pituitary growth hormone. IV. Skeletal changes: tibia, costochondral junction and caudal vertebrae. *Growth.* 12:43-54. 1948.
- Evans, H. M., M. E. Simpson, and C. H. Li.  
The gigantism produced in normal rats by injection of the pituitary growth hormone. I. Body growth and organ changes. *Growth.* 12:15-32. 1948.
- Gaebler, O. H., and W. H. Price.  
Effects of an anterior pituitary growth preparation on protein metabolism. *Jour. Biol. Chem.* 121:497. 1937.
- Hahn, L., G. Hevesy, and E. C. Lundsgaard.  
The circulation of phosphorus in the body revealed by application of radioactive phosphorus as indicator. *Biochem. Jour.* 31:1705. 1937.
- Hamilton, J. G.  
The use of radioactive tracers in biology and medicine. *Radiology.* 39:531. 1942.
- Jones, L. M., and G. Y. Shinewara.  
Serum inorganic phosphate and "alkaline" phosphatase activity in hypophysectomized rats. *Jour. Biol. Chem.* 142:935. 1942.

- Kamen, Martin D.  
Radioactive Tracers in Biology. New York: Academic Press, 1948.
- Kaufman, Victor.  
The distribution of phosphorus in some bones of the white rat (*Rattus norvegicus albinus*) whose growth has been accelerated by growth hormone. II. Eighty hours after a single injection of radioactive phosphorus. Unpublished Master's thesis, Kansas State College, Manhattan, Kansas, 1950.
- Li, C. H., H. M. Evans, and M. E. Simpson.  
Isolation and properties of anterior hypophyseal growth hormone. *Jour. Biol. Chem.* 159:353-366. 1945.
- Li, C. H., J. Geschwind, and H. M. Evans.  
The effect of growth hormone on the inorganic phosphorus levels in the plasma. *Endocrinol.* 44:67-70. 1949.
- Manly, M. L., and W. F. Bale.  
The metabolism of inorganic phosphorus of rat bones and teeth as indicated by the radioactive isotope. *Jour. Biol. Chem.* 129:125-134. 1939.
- Marx, W., and W. C. Reinhardt.  
Lack of effect of growth hormone on deposition of radiostrontium in bone. *Soc. Expt. Biol. and Med. Proc.* 51:112-114.
- Pecher, C.  
Biological investigations with radioactive calcium and strontium. *Soc. Expt. Biol. and Med. Proc.* 46:86. 1941.
- Reifenstein, E. C. Jr., L. W. Kinsell, and F. Albright.  
Observation on the use of the serum phosphorus level as an index of pituitary growth hormone activity. *Endocrinol.* 39:71. 1946.
- Ross, E. S., and F. C. McLean.  
The influence of the growth hormone of the anterior pituitary upon growth activity in the long bones of the rat. *Endocrinol.* 27:329-339. 1940.
- Silberberg, M., and R. Silberberg.  
Effects of hormones on the skeleton of mice, guinea pigs and rats. *Endocrinol.* 29:475-482. 1941.
- Teel, H. M., and O. Watkins.  
The effect of extracts containing the growth principle of the anterior hypophysis upon the blood chemistry of dogs. *Amer. Jour. Physiol.* 89:662. 1929.

THE DISTRIBUTION OF PHOSPHORUS IN THE HUMERUS OF THE WHITE RAT  
(RATTUS NORVEGICUS ALBINUS) WHOSE GROWTH HAS BEEN ACCELER-  
ATED BY GROWTH HORMONE. III. TWELVE HOURS AFTER  
A SINGLE INJECTION OF RADIOACTIVE PHOSPHORUS

by

ROBERT LOUIS SALISBURY

B. S., Ottawa University, 1952

---

AN ABSTRACT OF A THESIS

submitted in partial fulfillment of the

requirements for the degree

MASTER OF SCIENCE

Department of Zoology

KANSAS STATE COLLEGE  
OF AGRICULTURE AND APPLIED SCIENCE

1953

A study was made to determine the effects, if any, of the growth-stimulating hormone from the anterior lobe of the pituitary gland on the mobilization of phosphorus in the humeri of white rats, 12 hours after an injection of radioactive phosphorus.

Eight animals were used for this phase of the work and for identification purposes were colored with dilute solutions of dyes. Four rats were maintained as experimentals and were injected with growth hormone and phosphorus 32. The remaining animals received only the radiophosphorus injection and served for control purposes.

One rat unit of growth hormone was injected into the experimentals twice daily for four days. At the end of this period all of the rats were injected with approximately 50 microcuries of radioactive phosphorus, prepared as a solution of disodium monohydrogen phosphate.

Twelve hours after the phosphorus 32 injection the animals were sacrificed, the legs removed, and the humeri were scraped free of excess flesh before immersion in 99 percent isopropyl alcohol. The bones were imbedded in Ward's Bioplastic and sectioned with a rotary saw blade mounted on the shaft of a fractional horsepower motor. The cut bone sections were affixed to celluloid strips and then placed in contact with the emulsion of Eastman Kodak Portrait Panchromatic photographic film which had been cut to the same size as the celluloid. The film-bone-celluloid strips were allowed to expose for approximately 15 days

after which the film was developed by ordinary photographic processes.

Photomicrographs of the bone sections and enlargements of the radioautographs were made.

The radioautographs of the bone sections of rats injected with the growth hormone were markedly different from those of the controls. Attempts were made to select similar bone sections from both groups and to compare their radioautographs.

Radioautographs of cross-sections of the diaphyses of the right and left humeri of the growth hormone injected rats showed high concentration of the phosphorus 32 in the region of the periosteum. Similar sections in uninjected controls showed the phosphorus concentrated in the region of the endosteum and that it had not been mobilized for growth purposes within 12 hours following the isotope injection.

The results of this work indicate that growth hormone does accelerate the mobilization of the bone phosphorus within 12 hours of radiophosphorus injection and that the greatest activity appears at the sites where new bone is formed. This occurs in the sub-periosteal region and along the epiphyseal plate in young animals when growth is accelerated by injection of growth hormone of the anterior lobe of the pituitary gland.

This study confirms the results of previous work done on this problem at Kansas State College and extends the observations to a shorter interval of action of phosphorus 32.