



Endoscopic ultrasound-guided ascites aspiration in the hands of the chest physician using the EBUS endoscope in the oesophagus

Nessar, Rafi; Toennesen, Louise L.; Bodtger, Uffe; Christiansen, Ida Skovgaard; Clementsen, Paul Frost

Published in:
Respiratory Medicine Case Reports

DOI:
[10.1016/j.rmcr.2020.100998](https://doi.org/10.1016/j.rmcr.2020.100998)

Publication date:
2020

Document version
Publisher's PDF, also known as Version of record

Document license:
[CC BY-NC-ND](https://creativecommons.org/licenses/by-nc-nd/4.0/)

Citation for published version (APA):
Nessar, R., Toennesen, L. L., Bodtger, U., Christiansen, I. S., & Clementsen, P. F. (2020). Endoscopic ultrasound-guided ascites aspiration in the hands of the chest physician using the EBUS endoscope in the oesophagus. *Respiratory Medicine Case Reports*, 29, [100998]. <https://doi.org/10.1016/j.rmcr.2020.100998>



Case report

Endoscopic ultrasound-guided ascites aspiration in the hands of the chest physician using the EBUS endoscope in the oesophagus

Rafi Nessar^a, Louise L. Toennesen^{a,c}, Uffe Bodtger^{a,d,e}, Ida Skovgaard Christiansen^{a,*}, Paul Frost Clementsen^{a,b,f}

^a Department of Internal Medicine, Zealand University Hospital, Roskilde, 4000, Roskilde, Denmark

^b Copenhagen Academy for Medical Education and Simulation (CAMES), Rigshospitalet, 2100, Copenhagen, University of Copenhagen and the Capital Region of Denmark, Denmark

^c Department of Pulmonary Medicine, Bispebjerg University Hospital, 2400, Copenhagen, Denmark

^d Department of Respiratory Medicine, Naestved Hospital, 4700, Naestved, Denmark

^e Institute for Regional Health Research, University of Southern Denmark, 5000, Odense, Denmark

^f Department of Clinical Medicine, University of Copenhagen, Denmark



ARTICLE INFO

Keywords:

Ascites
Endoscopic ultrasound-guided fine needle aspiration
EUS-B-FNA
Interventional pulmonology
Lung cancer

ABSTRACT

Background: The use of the endobronchial ultrasound (EBUS) scope in the oesophagus, the so-called EUS-B procedure, for the diagnosis and staging of lung cancer is quickly gaining ground.

Case presentation: We here present a case demonstrating that EUS-B guided aspiration of intraperitoneal fluid (ascites) is possible. This has never been described before.

The procedure was performed with the use of a 22 G needle in a 71 years old woman suspected of lung cancer. No complications were seen.

Conclusion: We hereby demonstrate that EUS-B fine needle aspiration from ascites fluid is feasible and appears to be safe.

1. Background

Pulmonologists have traditionally been reluctant to perform transesophageal endoscopic ultrasound (EUS) using the larger gastrointestinal scope [1], whereas transesophageal endoscopic ultrasound fine needle aspiration biopsies with the smaller EBUS endoscope (EUS-B-FNA) is quickly gaining ground. However, the experiences with the latter are still relatively sparse. EUS-B guided aspiration of ascites fluid has never been described before.

2. Case presentation

A woman aged 71 years was referred to our department because of infiltration in the middle lobe. Five years earlier she had been operated for breast cancer. Computed Tomography (CT) also showed enlarged mediastinal lymph nodes station 4R and 4L (1.5 cm short axis) and small amounts of ascites. Systematic bronchoscopy and endobronchial ultrasound guided transbronchial needle aspiration (EBUS-TBNA) were performed and the enlarged lymph nodes were biopsied. Cytopathological

evaluation revealed no malignant cells. In the same session EUS-B was performed. The ascites fluid in the perihepatic region (Fig. 1) was visualized. A 22G needle was introduced into the ascites, traversing the wall of the stomach (Fig. 2), and 10 mL was aspirated. Cytopathological evaluation showed mesothelial cells and chronic inflammation. No complications were seen. A few weeks later bone metastases – probably from the breast cancer - were demonstrated. The patient quickly lost her strength and died. Autopsy was not performed. In this case, aspiration of ascites by EUS-B-FNA spared the patient for percutaneous ascites aspiration.

3. Discussion

There is increasing evidence for the feasibility and safety of EUS-B-FNA from multiple sites outside the mediastinum such as liver, left adrenal gland or lung [2–4]. Our case story demonstrates that EUS-B-FNA from ascites fluid in a patient suspected of lung cancer is possible in the same session as bronchoscopy and EBUS-TBNA. Traditionally diagnostic aspiration of ascites fluid is done percutaneously guided by ultrasound or by the use of EUS [5]. There are no randomized studies comparing

* Corresponding author. Department of Internal Medicine, Zealand University Hospital, Roskilde, Sygehusvej 10, 4000, Roskilde, Denmark.

E-mail address: ids@regionsjaelland.dk (I.S. Christiansen).

<https://doi.org/10.1016/j.rmcr.2020.100998>

Received 27 December 2019; Received in revised form 3 January 2020; Accepted 5 January 2020

Available online 7 January 2020

2213-0071/© 2020 The Authors.

Published by Elsevier Ltd.

This is an open access article under the CC BY-NC-ND license

(<http://creativecommons.org/licenses/by-nc-nd/4.0/>).

Abbreviations

CT	Computed Tomography
EBUS	endobronchial ultrasound
EUS	transesophageal endoscopic ultrasound
EUS-B	EUS with EBUS endoscope
FNA	fine needle aspiration biopsies
TBNA	transbronchial needle aspiration

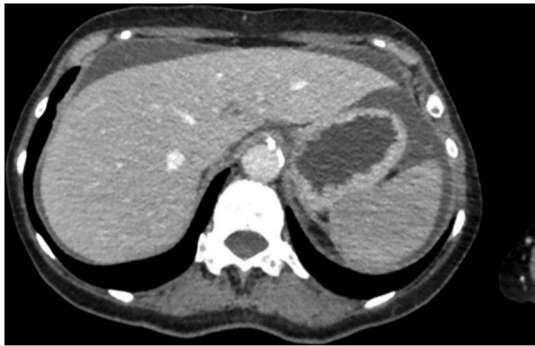

Fig. 1. CT-scan of the patient showing ascites fluid in the perihepatic region.

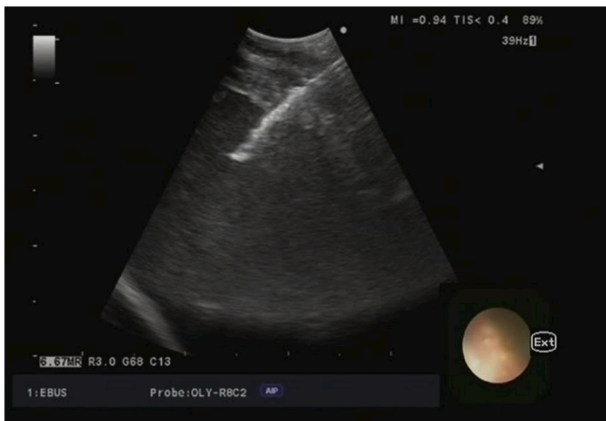


Fig. 2. Transesophageal bronchoscopic ultrasound-guided fine needle aspiration of ascites fluid.

these two techniques. Theoretically, complications to EUS-B-FNA may be bleeding, infection and perforation of the gastrointestinal tract. The EBUS needle is typically 20–40 mm. The risk when using the larger EUS

endoscope (EUS needle length 80–90 mm) is extremely low [6]. In a systematic review of combined EUS-FNA and EBUS-TBNA, severe complications were reported in 0.3% of the patients (one lymph node abscess and one pneumothorax) [7]. No serious complications to EUS-B-FNA have been reported [8].

There are obvious logistical and practical advantages in performing EUS-B guided aspiration of ascites in connection with EBUS. We recommend EUS-B guided aspiration of ascites fluid in patients with indication of both diagnostic ascites aspiration and EUS-B for sampling other structures. This may spare the patient from a superfluous percutaneous ascites aspiration.

In conclusion, we hereby demonstrate that EUS-B-FNA from ascites fluid is feasible and appears to be safe.

Funding

This research did not receive any specific grant from funding agencies in the public, commercial, or not-for-profit sectors.

Authors' contributions

RN performed the procedure. PFC, LLT, UB, ISC and RN reviewed the literature and were major contributor in writing the manuscript. All authors read and approved the final manuscript. All authors approved the submitted version.

Declaration of competing interest

The authors declare that they have no conflicts of interest with respect to the content of this paper.

References

- [1] P. Vilmann, P.F. Clementsen, Combined EUS and EBUS are complementary methods in lung cancer staging: do not forget the esophagus, *Endosc. Int. Open* 3 (4) (2015 Aug) E300–E301.
- [2] M. Fally, R. Nessar, N. Behrendt, P.F. Clementsen, Endoscopic Ultrasound-Guided Liver Biopsy in the Hands of a Chest Physician. *Respiration*, vol. 92, Karger Publishers, 2016, pp. 53–55, 1.
- [3] L.M.M.J. Crombag, J.T. Annema, Left adrenal gland analysis in lung cancer patients using the endobronchial ultrasound scope: a feasibility trial, *Respiration* 91 (3) (2016) 235–240.
- [4] I. Skovgaard Christiansen, J.C. Kuijvenhoven, U. Bødtger, T.M.H. Naur, K. Ahmad, J. Singh Sidhu, et al., Endoscopic ultrasound with bronchoscope-guided fine needle aspiration for the diagnosis of paraesophageally located lung lesions, *Respiration* (2018 Sep 25) 1–7.
- [5] M. Stukan, Drainage of malignant ascites: patient selection and perspectives, *Cancer Manag. Res.* 9 (2017) 115–130.
- [6] S. Lakhakia, Complications of diagnostic and therapeutic endoscopic ultrasound, *Best Pract. Res. Clin. Gastroenterol.* 30 (5) (2016) 807–823.
- [7] R. Zhang, K. Ying, L. Shi, L. Zhang, L. Zhou, Combined endobronchial and endoscopic ultrasound-guided fine needle aspiration for mediastinal lymph node staging of lung cancer: a meta-analysis, *Eur. J. Cancer* 49 (2013) 1860–1867.
- [8] A. Bugalho, M. Santis, A. Szlubowski, A. Rozman, R. Eberhardt, Trans-esophageal endobronchial ultrasound-guided needle aspiration (EUS-B-NA): a road map for the chest physician, *Pulmonol* 24 (1) (2018) 32–41.