



## Research Article

# Anatomical and physiological basis of the reduced occlusion syndrome

Irina V. Voytiatskaya<sup>1,2</sup>, Alexander V. Tscymbalystov<sup>1\*</sup>, Marya G. Gayvoronskaya<sup>3</sup>, Tatyana A. Lopuchanskaya<sup>1,2</sup>, Alexander A. Kopytov<sup>1</sup>

## ABSTRACT

**Aim:** Decrease in the interalveolar distance (IAD) that develops during a period of permanent occlusion as a result of progressive primary dental diseases: Increased abrasion of hard tissues of the teeth, extensive edentulous space, and generalized form of periodontitis is accompanied by morphofunctional changes in the masticatory muscles and the development of temporomandibular joint (TMJ) dysfunction. The objective of the study was to identify development mechanisms of the reduced occlusion syndrome (ROS) that develops as a result of decrease in the IAD caused by primary dental diseases. **Material and Method:** 395 people 28–68 years of age with primary dental diseases of the dentofacial apparatus. Of the overall examined, 293 (74.2%) patients with decrease in the IAD constituted the active treatment group. The control group included 102 patients without sign symptoms of reduced occlusion. Patients in the control group had different types of dental prosthesis in the oral cavity at the time of examination. The morphological examination object included 138 certified skulls with lower jaws. Anamnestic and clinical data were analyzed. Radiological methods were used rehabilitation capabilities of the dentofacial apparatus, a functional and physiological method for determining the jaw relation was applied, facial electromyography of the chewing muscles, and neck muscles was used. **Results and Discussion:** The work presents and scientifically grounds the diagnostic system for integral assessment of morphofunctional linkages of dentofacial apparatus and reduced occlusion syndrome patients, its stomatogenic and general manifestations have been defined, an effective treatment regimens and rehabilitation of reduced occlusion syndrome patients of varying severity have been developed. The combination of resulting data enables to reduce complications developed on the background of primary dental diseases accompanied by a decrease in the interalveolar distance of different origin. **Conclusion:** The study revealed that of 293 examined patients with a decrease in the IAD, 231 (78.8%) patients were diagnosed with the ROS of different severity. The ROS is a persistent pathological process characterized by progressiveness, which includes: Anatomical and functional changes resulting in compression of bilaminar region of the TMJ, as well as in an impaired functions of chewing-speech apparatus with somatogenic and general manifestations, developing on the background of a decrease in the efficiency of vegetative regulation of the region and the patient's body.

**KEY WORDS:** Cerebral hemodynamics, Decrease in the interalveolar distance, Equilibrium function, Neurohumoral regulation, Oral mucosa Microvasculature, Reduced occlusion syndrome, Visual analyzer

## INTRODUCTION

Decrease in the interalveolar distance (IAD) that develops during a period of permanent occlusion as a result of progressive primary dental diseases: Increased abrasion of hard tissues of the teeth, extensive edentulous space, and generalized form of periodontitis is accompanied by morphofunctional changes in

the masticatory muscles and the development of temporomandibular joint (TMJ) dysfunction.<sup>[1-7]</sup>

The analysis of complaints from patients with different dental diseases varies from their absence to serious problems manifested by changes in neurological status, oral mucosa and tongue numbness, hearing and vision loss, dizziness, headaches of different locations, and sleep impairment.<sup>[8-12]</sup>

Correction of occlusal relationships under pathological conditions of chewing-speech apparatus enables not

### Access this article online

Website: [jprsolutions.info](http://jprsolutions.info)

ISSN: 0975-7619

<sup>1</sup>Department of Pediatric and Prosthetic Dentistry, Belgorod State University, 308000, Belgorod, Pobeda Street, 85, Russia,

<sup>2</sup>Department of Orthopedic Dentistry, North-Western State Medical University Named After I.I. Mechnikov 191015, Sankt-Peterburg, Kirochnaya Street, 41, Russia, <sup>3</sup>Medical Faculty, National Medical Research Centre Named After V.A. Almazov, 197341 St. Petersburg, Akkuratova Str., 2, Russia

\*Corresponding author: Aleksandr V. Tsimbalistov, Department of Pediatric and Prosthetic Dentistry, Belgorod State National Research University 85, Pobedy St., Belgorod, 308015, Russia. E-mail: [Tsimbalistov@bsu.edu.ru](mailto:Tsimbalistov@bsu.edu.ru)

Received on: 14-04-2019; Revised on: 15-06-2019; Accepted on: 17-07-2019

only to restore the chewing function, reduce pain intensity in dysfunctional states of TMJ but also makes it possible to eliminate pain in TMJ and muscles of different spine regions, fix the posture of a patient.<sup>[13-18]</sup>

Improvement of clinical manifestations may be due to the elimination or reduction of the impact that chewing apparatus elements have on hemodynamics in the vascular territories of the brain, neck, and upper spine.<sup>[19-20]</sup>

### Objective

The objective of the study was to identify development mechanisms of the reduced occlusion syndrome (ROS) that develops as a result of decrease in the IAD caused by primary dental diseases.

## MATERIALS AND METHODS

We examined 395 people 28–68 years of age with primary dental diseases of the dentofacial apparatus. Of the overall examined, 293 (74.2%) patients with decrease in the IAD constituted the active treatment group. The control group included 102 patients without sign symptoms of reduced occlusion. Patients in the control group had different types of dental prosthesis in the oral cavity at the time of examination. The morphological examination object included 138 certified skulls with lower jaws.

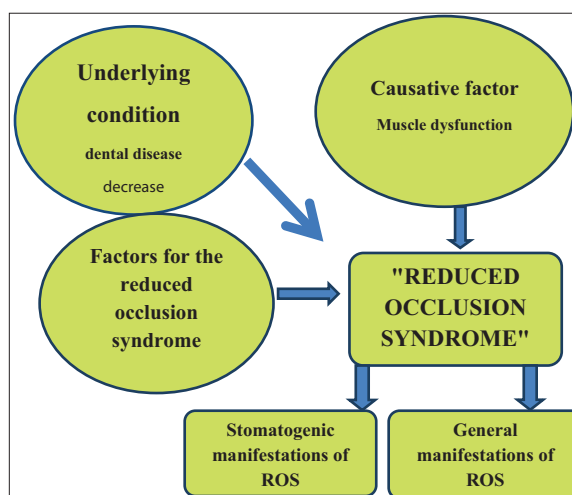
Anamnestic and clinical data were analyzed. Radiological methods were used: Multislice spiral computed tomography (MSCT). To assess the rehabilitation capabilities of the dentofacial apparatus, a functional and physiological method for determining the jaw relation was applied, facial electromyography of the chewing muscles, and neck muscles was used. The complex of diagnostic techniques included: Doppler ultrasound of vascular territories of the head and neck, laser Doppler flowmetry, and optical tissue oximetry of the vessels of the oral mucosa. Computerized stabilometric was used to assess the equilibrium function. Functional assessment of the visual analyzer was performed using automatic computerized perimetry (ACP) and electrophysiological assessment of retinal function. Heart rate variability in patients of the active treatment and control groups was analyzed to assess the rehabilitation resource of the body.

Statistical processing of the material was performed on a computer using a standard applied statistical analysis software package (Statistica for Windows v. 6.0). The critical probability level of the null statistical hypothesis (no significant difference or no effect) was 0.05.

## RESULTS AND DISCUSSION

The main objective of the study was to identify clinical, functional, and morphological components typical of

the ROS as an independent nosological entity. The main factor for the ROS is the presence of the primary dental disease: increased abrasion of hard tissues of the teeth, chronic generalized form of periodontitis, and edentulous space of different locations and extent [Figure 1]. These specified diseases caused by different causative factors are, in fact, the background state for the ROS, since their development leads to a decrease in the IAD. ROS is accompanied by the following clinical somatogenic symptoms: Decrease in the IAD and the lower facial dimensions, dissatisfaction with facial appearance, difficulty chewing and speaking, asymmetry of soft tissues, displacement at the central incisal edge by more than 0.5 mm, and deviation or deflection. According to the results of instrumental examination, the fact that the ROS is characterized by the following somatogenic functional manifestations has been established: Chewing disorders, parafunctions of chewing muscles and neck muscles, decrease in the IAD, deviation of the mandible when joining the teeth of more than 0.5 mm, and distorsion of more than 0.5 mm. Electromyography detected the disturbance of electrogenesis in chewing muscles, which is manifested by acute asymmetry of bioelectric activity, the presence of parafunctions, and the inclusion of neck muscles in the functioning of chewing apparatus. There is a deterioration of oral mucosa microcirculation, indicating tissue hypoxia with a predominance of venular blood flow congestion (increase in the ratio of endothelial and myogenic tone and rate of shunting, decrease in arterial blood saturation). Roentgenographic evidences of the ROS, according to MSCT, are the decrease in the width of superior part of joint space ( $<3.61 \pm 0.12$ ) and the posterior part of joint space ( $<3.02 \pm 0.1$  mm), with acute asymmetry (index of asymmetry more than 0.20). The facts show that the decrease in the IAD is accompanied by more expressed symptomatic functional disorders in making comparative assessment. The present integrated study



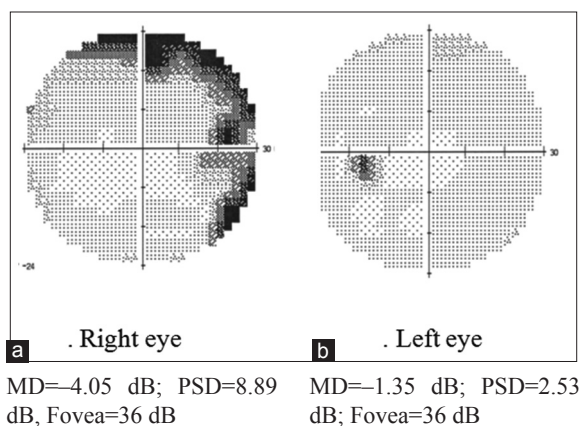
**Figure 1:** Pathogenesis scheme of the reduced occlusion syndrome

has found that the decrease in the IAD is accompanied by a number of general manifestations. The pathogenesis scheme of the ROS is shown in Figure 1.

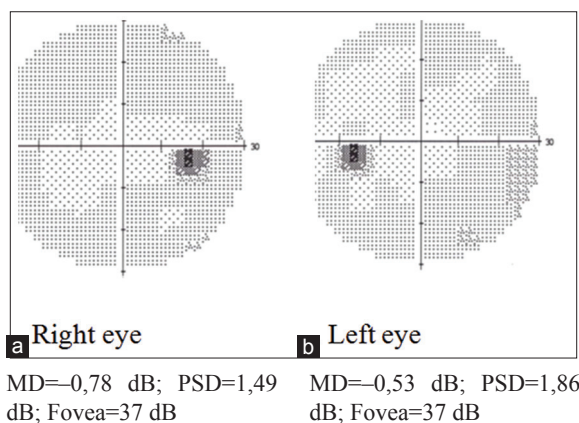
They include changes in the macrocirculation with acute asymmetry of linear blood flow velocity in the siphon and trunk of the internal carotid, vertebral, ophthalmic, supratrochlear, and basilar arteries. When the IAD is normalized, the asymmetry degree is reduced by 2.13 times or more.

According to computerized stabilometric, the development of ROS is accompanied by statokinetic system dysfunction. The high frequency of the balance function impairment in the ellipse surface and in the coefficient of balance function was identified. During dental tests (tests 10 and 12), all 231 (78.8%) patients with the ROS had an impaired equilibrium function of dental origin. During tests 16 and 17, in 97 (33.1%) patients, the involvement of neck muscles was determined, which reflected the severity of the ROS.

When reconstructing the IAD, there is an improvement in the visual analyzer function according to the ACP



**Figure 2:** Results of automatic computerized perimetry in normal occlusion in patient S. before treatment. PSD: Power spectral density



**Figure 3:** Results of automatic computerized perimetry in ideal occlusion in patient S. after treatment. PSD: Power spectral density

data (MD and power spectral density PSD) and the results of the electrophysiological studies of retina by ERG according to ISCEV and pattern ERG standards. Once the jaw relation has been normalized, patients with decreased IAD showed statistically significant improvement in ACP indicators – MD (average reduction in light sensitivity) and PSD (severity of local defects) ( $P < 0.05$ ). The MD increased (from  $-1.57 \pm 0.25$  to  $-0.62 \pm 0.15$  dB) and PSD decreased (from  $2.96 \pm 0.25$  to  $2.51 \pm 0.1$  dB) and thus indicating an improvement in the central visual field. The fovea index characterizing the macular light sensitivity has remained significantly constant. The results of ACP in the normal and ideal occlusion in the patient S. are shown in Figures 2 and 3. It should be noted that the majority of patients showed more symmetrical indices of light sensitivity when applying ACP.

ERG showed a statistically significant improvement in some indices of rod (scotopic) system of retina electrogenesis ( $P < 0.05$ ). The amplitude of b-waves of total ERG increased from  $200.8 \pm 17.52$  mV to  $255.6 \pm 10.8$  mV. The average amplitude of the retinal scotopic system in normal occlusion before treatment was  $73.8 \pm 5.82$  mV, after normalization of the IAD increased up to  $96.2 \pm 6.23$  mV ( $P < 0.05$ ). After the jaw relation has been normalized, the macula functioning indicators have shown improvement: There was a statistically significant increase in the amplitude of the positive component of the macula functioning (P50) from  $3.2 \pm 0.27$  to  $5.0 \pm 0.38$  mV; there was an improvement in the retinal ganglion cells functioning (3<sup>rd</sup> order neuron of visual pathway). The amplitude of the negative component (N95) after treatment was increasing from  $5.1 \pm 1.05$  to  $7.4 \pm 0.80$  mV ( $P < 0.05$ , which was viewed as an improvement).

It is noteworthy that, in addition to changed amplitude and after adjusting the jaw relationship, the indicators of both eyes had become more symmetrical than before treatment.

The main factor imperative for the development of the ROS is the shewing muscles dysfunction, especially m. masseter and m. temporalis, resulting in upper-posterior asymmetric dislocation of the head of mandible into the glenoid fossa with subsequent compression of bilaminar region.

An important condition for the ROS is an unsatisfactory regional autonomic regulation, characterized by sympathetic adrenal type of response, which conditions the specifics of muscle pain, vascular response, and development of muscle dysfunction.

The reduced occlusion symptom is characterized by progressiveness, which includes a morphofunctional pattern affected by the primary dental diseases that cause

a decrease in the IAD. This changes the topography of the heads of mandible into the glenoid fossa, resulting in compression of the bilaminar region, which is combined with changes in macro and microcirculation in the maxillofacial area, functional disorders, somatogenic, and general manifestations posed by decompensation of neurohumoral (autonomic) regulation.

The process of dislocation of the head of mandible is accompanied by compression of bilaminar region, development of vascular disorders, and impaired function of statokinetic tract and the visual analyzer.

Using craniological examination of 138 certified skulls and assessment of the location of petrotympanic fissure in relation to the mandibular fossa, the following has been established: Two options of the location of petrotympanic fissure. The location of petrotympanic fissure at the posterior edge of the mandibular fossa was considered as the first option of topography and at the petrotympanic fissure crossing the mandibular fossa through a medial third - as the 2<sup>nd</sup> option of topography. The chorda tympani is less likely to be compressed under the first location option of petrotympanic fissure, namely at the posterior edge of the mandibular fossa. The existence of this morphological feature leads to compression of the back articular space, which in turn can change reflexively the hemodynamic parameters of macro and microcirculation in the head and neck.

The prognosis of the effectiveness of ROS treatment is based on assessing the type of dependence of energy characteristics and recording the maximum integral index of jaw compression forces when using the AOCO-M device (central occlusion recording device), since it reflects the state of functioning of the masticatory apparatus and the possible level of restoration of masticatory function.

These specified criteria helped to describe the stages of development of the ROS and identify three severity levels of the pathological process. The classification of the ROS by severity level is based on the following: Decrease in the IAD and the response level of the neuromuscular complex, determined by the type of dependence of the jaw compression forces on the change in the IAD. This also allowed to objectively assess the neuroregulatory function severity of the chewing apparatus.

The principal sign when determining the severity of ROS is the decrease in the width of superior and posterior parts of the joint space of the TMJ.

## CONCLUSION

The study revealed that of 293 examined patients with a decrease in the IAD, 231 (78.8%) patients were

diagnosed with the ROS of different severity. The indicators used characterize the ability of regional innervation, regional blood flow, as well as the ability of chewing muscles to react and respond adequately to curative, and rehabilitation measures. The ROS is characterized by a specific clinical pattern that develops against the background of the primary dental diseases, causing a decrease in the IAD.

Thus, the ROS is a persistent pathological process characterized by progressiveness, which includes: Anatomical and functional changes resulting in compression of bilaminar region of the TMJ, as well as in an impaired functions of chewing-speech apparatus with somatogenic and general manifestations, developing on the background of a decrease in the efficiency of vegetative regulation of the region and the patient's body.

## REFERENCES

1. Safonova N, Ashnokova I, Mikhailov V, Kotsiubinskaya J, Lopushanskaya T. Capabilities of electromyography in the dysfunction temporomandibular joint. *Eur J Neurol* 2016;23:784-90.
2. Voytiatskaya IV, Tsimbalistov AV, Oleinik EA, Oganeyan AA. Distant response of the visual analyzer function (visual fields) to the reduction of occlusal vertical dimension in dental patients. *Res J Med Sci* 2015;9:193-6.
3. Kotsiubinskaya YV, Lopushanskaya TA, Mikhailov VA, Ashnokova IA. Principal opening mechanisms in patients with temporomandibular joint pain dysfunction syndrome. *Neurol Bull* 2014;46:11-5.
4. Bazer S, Mesnar M, Morle J. Mandibular advancement and general posture, stabilometric experimental study. *Russ J Biomech* 2013;3:13-28.
5. Bulycheva EA, Chikunov SO, Alpatyeva YV. Development of a system of rehabilitation therapy in patients with different clinical forms of temporomandibular joint disorders complicated by muscle hypertension: Part 3. *Inst Dent* 2013;2:44-5.
6. Sakagami R, Kato H. The relationship between the severity of periodontitis and occlusal conditions monitored by the K6 diagnostic system. *J Oral Rehabil* 1996;23:615-21.
7. Coskun Akar G, Govsa F, Ozgur Z. Examination of the heads of the lateral pterygoid muscle on the temporomandibular joint. *J Craniofac Surg* 2009;20:219-23.
8. Gagey PM, Veber B. Posturologic Regulation and Human Body Balance Disorder. Petersburg: Saint-Petersburg Medical Academy of Postgraduate Studies; 2008.
9. Tsimbalistov AV, Chervotok AE, Lopushanskaya TA, Voytiatskaya IV. Dental status of patients with diseases of the musculoskeletal system. *Inst Dent* 2008;4:10-4.
10. Solovykh EA, Bugrovetskaya OG, Maksimovskaya LN. Information value of functional status of the stomatognathic system for postural balance regulation. *Bull Exp Biol Med* 2012;153:383-7.
11. Tsimbalistov AV, Mikhailova VV, Voytiatskaya IV, Kopytov AA, Oganeyan AA. Microcirculation dynamics of changes in the oral mucosa in the patients with paresthesia during orthopedic dental treatment. *Drug Invent Today* 2017;9:48-52.
12. Slavichek R. The Masticatory Organ. Functions and Dysfunctions. Austria: Klosterneuburg; 2008.
13. Khoroshilkina FY. Orthodontics: Textbook for postgraduate training in specialty of dentistry. In: *Complex Treatment of Dentofacial Abnormalities: Orthodontic, Surgical, Orthopedic*. Moscow: MIA; 2001.
14. Voytiatskaya IV, Tsimbalistov AV, Leontiev VK, Ivanov SY, Kopytov AA. Estimation of stabilometric indicators with a decrease in the interalveolar distance. *Drug Invent Today*

- 2018;10:1673-7.
15. Voytiatskaya IV, Tsimbalistov AV, Gayvoronskaya MG, Kopytov AA, Minyaylo YA. Anatomic X-ray features of the temporomandibular joint elements with a decrease in the interalveolar distance. *Drug Invent Today* 2017;9:69-73.
  16. Palano D. Role of stability in the evaluation of correlations between craniomandibular disorders (MCT) and disorders of equilibrium (TE). *Bull Group Int Rech Sci Stomatol Odontol* 1994;37:23-6.
  17. Ahn HJ, Paik SK, Choi JK, Kim HJ, Ahn DK, Cho YS, *et al.* Age-related changes in the microarchitecture of collagen fibrils in the articular disc of the rat temporomandibular joint. *Arch Histol Cytol* 2007;70:175-81.
  18. Feu D, Catharino F, Quintão CC, Almeida MA. A systematic review of etiological and risk factors associated with bruxism. *J Orthod* 2013;40:163-71.
  19. Voytiatskaya IV. Functional and Physiological Method for Determining Jaw Relation (Analysis of 15 Years of Observations). Belgorod: Tsimbalistov AV, editor. Materials of the 8<sup>th</sup> Scientific and Practical Conference “Odontology of Slavic States”. 2015. p. 63-71.
  20. Tsimbalistov AV, Sinititskiy AA, Lopushanskaya TA, Voytiatskaya IV. Patent, No. 2471417 of the Russian Federation. A Method for Diagnosing Muscle and Joint Dysfunction of Stomatognathic System. Application, No. 2011135719; 2013.

Source of support: Nil; Conflict of interest: None Declared