

# Coronavirus Disease 2019 in Recipient of Allogeneic Hematopoietic Stem Cell Transplantation: Life-threatening Features Within the Early Post-engraftment Phase

Chiara Oltolini<sup>1</sup>, Anna Guidetti<sup>2,9</sup>, Marco Ripa<sup>1,8</sup>, Barbara Castiglioni<sup>1</sup>, Chiara Tassan Din<sup>1</sup>, Sara Mastaglio<sup>3</sup>, Diana Canetti<sup>1</sup>, Giacomo Monti<sup>4</sup>, Andrea Andolina<sup>1</sup>, Chiara Molinari<sup>5</sup>, Antonella Poloniato<sup>6</sup>, Andrea Mastrangelo<sup>1,8</sup>, Marica Ferrante<sup>7,8</sup>, Marco Lanzillotta<sup>7,8</sup>, Paolo Scarpellini<sup>1</sup>, Antonella Castagna<sup>1,8</sup>, Paolo Corradini<sup>2,9</sup>, Fabio Ciceri<sup>3,8</sup>

**Correspondence:** Chiara Oltolini (e-mail: [ciceri.fabio@hsr.it](mailto:ciceri.fabio@hsr.it)).

China reported a novel coronavirus, phylogenetically related to severe acute respiratory syndrome coronavirus (SARS-CoV), as the causative agent of an outbreak of pneumonia of unknown etiology in Wuhan. World Health Organization declared Coronavirus disease 2019 (COVID-19) a global pandemic: nowadays, 4,864,881 cases were reported worldwide, 228,006 in Italy with a 14% mortality rate.<sup>1</sup> Retrospective studies on Chinese patients with pneumonia highlighted that cardiovascular diseases, older age, high C-reactive protein (CRP), interleukin-6 and ferritin, low lymphocytes and secondary infections were predictive of death.<sup>2,3</sup>

COVID-19 features in immunocompromised hematological patients are emerging, but data on allogeneic hematopoietic stem cell transplant (allo-HSCT) recipients are still scanty (Table 1).<sup>4-8</sup> Jin et al reported a case of pneumonia in a male with chronic lymphocytic leukemia successfully treated with chemotherapy,

corticosteroids and  $\alpha$ -interferon.<sup>4</sup> Zhang et al described another one in a myeloma patient with favorable outcome after corticosteroids, arbidol and tocilizumab.<sup>5</sup> COVID-19 in an allo-HSCT recipient, developed 7-months after transplant while on maintenance cyclosporine, was firstly published by Huang et al. Despite achieving negative SARS-2-CoV with lopinavir/ritonavir, corticosteroid and immunoglobulins, the patient died with persistently low lymphocytes (T-cell  $< 300/\mu\text{L}$ , CD4  $< 100/\mu\text{L}$ ) and secondary infection.<sup>6</sup> Malard et al reported 25 cases in hematological patients including 2 recipients of allo-HSCT. At a median follow-up of 29-day since symptoms onset, 52% of patients developed acute respiratory distress syndrome (ARDS) and 36% died.<sup>7</sup> The first case series on 6 allo-HSCT recipients, who developed COVID-19 at a median time of 41-months after HSCT, did not report deaths, suggesting that an immunosuppressed status [5/6 patients with chronic graft-vs-host disease (c-GVHD)] may be protective against hyper-inflammation of severe disease (*unpublished data*).

We described a case of severe low respiratory tract infection (LRTI) by SARS-2-CoV in a 64 years-old man with non-Hodgkin lymphoma, which arose on 21-day after allo-HSCT from matched-unrelated donor, whose pre-engraftment phase was uneventful.

At hospital admission, 3 days after previous discharge, he was febrile and piperacillin/tazobactam was introduced. Laboratory tests revealed WBC  $3490/\mu\text{L}$  (neutrophils  $2000/\mu\text{L}$ , lymphocytes  $500/\mu\text{L}$ ), platelets  $189/\mu\text{L}$ , CRP 13 mg/dl, lactic dehydrogenase 710 U/l, normal renal and hepatic functions. The nasopharyngeal swab was negative for community acquired respiratory viruses (CARV), while PCR for SARS-2-CoV resulted positive on 26-day after HSCT with CT scan revealing mild pneumonia (Fig. 1A). The same day lopinavir/ritonavir and hydroxychloroquine were introduced, discontinuing piperacillin/tazobactam. At this time, the patient was in good condition [Modified Early Warning Score (MEWS) 2 points]. Laboratory tests showed CRP 1 mg/dl, lactic dehydrogenase 591 U/l, bilirubin 1 mg/dl, ferritin 5510 ng/ml, pro-calcitonin 0.1 ng/ml, D-dimer 0.83 ng/ml, WBC  $1720/\mu\text{L}$  (neutrophils  $800/\mu\text{L}$ , monocytes  $200/\mu\text{L}$ , lymphocyte  $600/\mu\text{L}$ , CD4  $35/\mu\text{L}$ , CD8  $304/\mu\text{L}$ , CD19  $0/\mu\text{L}$ ). On 33-day, because of major pharmacological interactions, lopinavir/ritonavir was

<sup>1</sup>Clinic of Infectious Diseases, Division of Immunology, Transplantation and Infectious Diseases, San Raffaele Scientific Institute, Milan, Italy

<sup>2</sup>Hematology and Bone Marrow Transplant, Istituto Nazionale Tumori, Milan, Italy

<sup>3</sup>Hematology and Bone Marrow Transplant, San Raffaele Scientific Institute, Milan, Italy

<sup>4</sup>Department of Anesthesia and Intensive Care, San Raffaele Scientific Institute, Milan, Italy

<sup>5</sup>Department of General Medicine, Endocrine and Metabolic Diseases Unit, San Raffaele Scientific Institute, Milan, Italy

<sup>6</sup>Neonatal Unit, San Raffaele Scientific Institute, Milan, Italy

<sup>7</sup>Department of General Medicine, San Raffaele Scientific Institute, Milan, Italy

<sup>8</sup>University Vita-Salute San Raffaele, Milan, Italy

<sup>9</sup>Department of Oncology and Hemato-Oncology, University of Milano, Milan, Italy.

CH, PC, FC, and AG contributed equally to this manuscript.

The authors have no conflicts of interest to disclose.

Copyright © 2020 the Author(s). Published by Wolters Kluwer Health, Inc. on behalf of the European Hematology Association. This is an open access article distributed under the terms of the Creative Commons Attribution-Non Commercial-No Derivatives License 4.0 (CCBY-NC-ND), where it is permissible to download and share the work provided it is properly cited. The work cannot be changed in any way or used commercially without permission from the journal.

HemaSphere (2020) 4:4(e448). <http://dx.doi.org/10.1097/HS9.0000000000000448>.

Received: 30 May 2020 / Accepted: 17 June 2020

Table 1

## Published Clinical Reports of Coronavirus Disease 2019 in Hematological Patients.

Reference Location	Age (years)/Sex Hematological disease Hematological status Hematological treatment	Previous transplant Ongoing corticosteroids Comorbidities	Time between symptoms onset-diagnosis (days) Radiological diagnosis ARDS	Invasive mechanical ventilation COVID-19 management Follow-up since symptoms onset (days) Survival status
Jin et al China <sup>4</sup>	39/male Non Hodgkin lymphoma/CLL Complete remission/Binet Stage C None, 2 months after chlorambucil withdrawn	No No No	4 Positive CT scan Yes	No Chlorambucil, nebulized $\alpha$ -IFN, Ig, MPD 22 Alive
Zhang et al China <sup>5</sup>	60/male Multiple myeloma Complete remission Maintenance thalidomide after 2 VTD cycles	No No No	20 Positive CT scan No	No Umifenovir, MPD, TCZ 42 Alive
Huang et al China <sup>6</sup>	51/male AML Complete remission HSCT, 7 months before	Yes, HSCT No No	3 Positive CT scan Yes	Yes LPV/r, Ig, MPD 22 Dead*
Malard et al France <sup>7</sup>	Twenty-five patients: median age 72/68% male 80% lymphoid tumor, 16% myeloid tumor 40% complete remission, 24% progression 52% ongoing, 16% supportive care	Yes, 2 HSCT <sup>†</sup> , 6 ASCT Yes, 40% 68% hypertension, 32% obesity, 8% COPD	4 (range: 0-22) Positive CT scan: 56% Yes, 52%	Yes, 24% Supportive care 72%, TCZ 12%, LPV/r 16% 29 (range: 14-40) Alive 64%, Dead 36%
Li et al China <sup>8</sup>	Five patients: 47 (range: 41-89)/60% male 100% chronic myeloid leukemia 40% no complete hematological response, 40% major molecular response 60% imatinib, 20% flumatinib, 20% HQP1351	No No 40% hypertension, 20% diabetes	Not available Positive CT scan: 80% Yes, 20%	Not available Not available 16 (range: 11-40) Alive 80%, Dead 20%
Lupo Stanghellini et al Italy (submitted data)	Six patients: median age 50 (range: 32-63)/ 66% male 100% myeloid tumor (5 AML, 1 MDS) 100% complete remission 100% HSCT, median time after HSCT 41-months (range: 30-114)	Yes, 6 HSCT (4 MUD, 2 MMRD) <sup>‡</sup> No 50% hypertension, 33% COPD	3 (range: 0-47) Positive CT scan: 50% No	No LPV/r and HCQ 50%, anakinra 16% 42 (range : 39-50) Alive 100%

AML = acute myeloid leukemia, ARDS = acute respiratory distress syndrome, ASCT = autologous stem cell transplant, CLL = chronic lymphocytic leukemia, COPD = chronic obstructive pulmonary disease, COVID-19 = Coronavirus disease 2019, CT = computed tomography, HCQ = hydroxychloroquine, HSCT = hematopoietic stem cell transplant, IFN = interferon, Ig = immunoglobulin, LPV/r = lopinavir/ritonavir, MDS = myelodysplastic syndrome, MMRD = mismatched-related donor, MPD = methylprednisolone, MUD = matched-unrelated donor, TCZ = tocilizumab, VTD = bortezomib-thalidomide-dexamethasone.

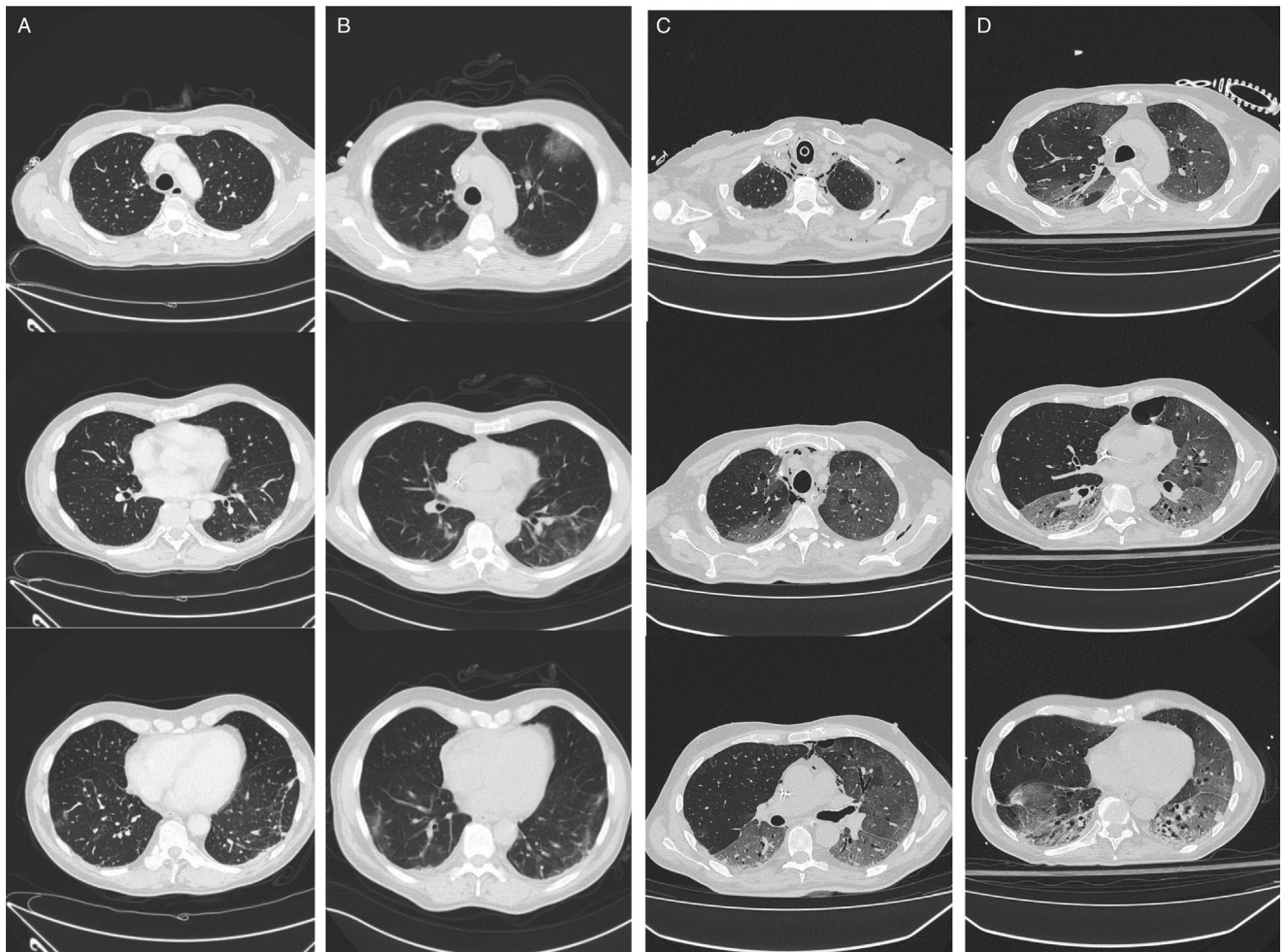
\* COVID-19 onset while on maintenance cyclosporine; despite achieving negative SARS-CoV-2, the patient died with persistently low lymphocytes (T-cell < 300/ $\mu$ L, CD4 < 100/ $\mu$ L) and secondary infection.

<sup>†</sup> 40 years-old female who developed COVID-19 ARDS 9-months after HSCT, alive 23-days after symptoms onset on invasive mechanical ventilation; 61 years-old male who developed COVID-19 ARDS 3-months after chimeric-antigen receptor T-cell therapy (previous ASCT, previous HSCT), alive 38-days after symptoms onset on invasive mechanical ventilation.

<sup>‡</sup> 5/6 patients with chronic graft-vs-host disease, 2/5 ruxolitinib, 1/5 imatinib/methotrexate, 2/5 no systemic immunosuppressive therapy.

replaced with azithromycin and cyclosporine with mycophenolate, detecting cyclosporine serum values  $\geq 200$  ng/ml until 43-day. On 36-day clinical condition worsened (MEWS 3 points), inflammatory markers increased (ferritin 5342 pg/ml, lactic dehydrogenase 836 U/l, D-dimer 0.71 ng/ml) and CT scan showed worsening bilateral infiltrates (Fig. 1B). Therefore, he received a single 6 mg/kg dose of tocilizumab and started methylprednisolone 0.5 mg/kg obtaining fever resolution. COVID-19 rapid immune-chromatographic test for determination of antibodies in whole blood was performed revealing the absence of both IgG and IgM. The patient required a progressive increase of oxygen supply, starting non-invasive ventilation on 41-day (MEWS 5 points). The same day, laboratory tests showed bilirubin 3.3 mg/dl, lactic dehydrogenase 1651 U/l and haptoglobin 0 mg/dl. Because of suspected endothelial activation, probably driven by both thrombotic micro-angiopathy and pulmonary hyper-inflammation, an off-label administration of intravenous defibrotide 6.25 mg/kg q6h was started and methylprednisolone was increased to 1 mg/kg

achieving a decrease of lactic dehydrogenase and stabilization of bilirubinemia and respiratory failure without major and minor bleedings. Since hospital admission, the patient received primary antimicrobial prophylaxis with acyclovir, letermovir, atovaquone and isavuconazole. On 45-day, SARS-2-CoV PCR was still positive, so azithromycin and hydroxychloroquine were discontinued. The clinical course was complicated on 54-day by blood culture negative septic shock (MEWS 8 points), requiring transfer to Intensive Care Unit for invasive mechanical ventilation, inotrope support (adrenaline, noradrenaline) and empiric antibiotic therapy (meropenem, daptomycin); the same day defibrotide was discontinued (bilirubin 3 mg/dl, lactic dehydrogenase 880 U/l). After Ethical Committee approval, on 57-day, the patient received remdesivir 100 mg q24h for compassionate use. Despite a prompt resolution of septic shock and requirement of moderate mechanical ventilation support for extensive bilateral pneumonia (Fig. 1C), a consciousness impairment and hepatic failure have taken over in the next days. Thrombotic micro-angiopathy, GVHD and viral



**Figure 1. (A)** 26-day after transplant, 5-day after symptoms onset: mild pseudo-nodular thickenings with ground-glass opacities affecting the lower lobes sub-pleural lung parenchyma and patchy ground-glass opacities at the upper left lobe. **(B)** 36-day after transplant, 15-day after symptoms onset: peripheral ground-glass opacities associated with smooth interlobular and intra-lobular septal thickening (crazy-paving pattern) at the upper lobes mainly the left one, mild increase of ground-glass opacities affecting the lower lobes. **(C)** 59-day after transplant, 38-day after symptoms onset: extensive ground-glass opacities in both lungs, involving almost the entire lung parenchyma but the upper right lobe, mild bilateral pneumothorax and moderate pneumo-mediastinum, absence of acute pulmonary thromboembolism. **(D)** 66-day after transplant, 45-day after symptoms onset: extensive ground-glass opacities in both lungs, involving almost the entire lower lobes and most of the upper lobes, giving a white lung appearance, with air bronchograms at lower lobes; resolution of pneumothorax and pneumo-mediastinum, presence of pneumatocele at the lingula; absence of acute pulmonary thromboembolism, pleuro-pericardial effusion and mediastinal lymphadenopathies.

infections have been addressed in differential diagnosis, but none was deemed likely for absence, respectively, of schistocytes and renal impairment, gut and skin involvement and viral reactivations (*Cytomegalovirus*, Herpes-virus 6 and *Adenovirus*). On 64-day a sharply increase of bilirubinemia up to 17mg/dl required interruption of both remdesivir and letermovir in suspicion of drug-induced liver injury. Radiological findings on 66-day showed moderate increase of ground-glass opacities (Fig. 1D). The same day high plasmatic concentration of isavuconazole (10mg/L) was detected, so the drug was withdrawn, being partially responsible for liver damage. On 74-day, bronco-alveolar lavage was performed excluding secondary infections (CARV, *Cytomegalovirus*, *Pneumocystis*, aspergillosis, bacteria) with SARS-2-CoV persistently positive, being the only causative pathogen. Bilirubinemia decreased slightly to 13 mg/dl and isavuconazole plasmatic concentration was still 4mg/L. On 75-day, galactomannan on bronco-alveolar lavage was repeated resulting positive (from < 0.5

to 3.3). Despite maximal medical and resuscitation support, the patient died on 78-day.

Several efforts are ongoing to address COVID-19 clinical features and therapeutic options in solid organ transplant (SOT) and HSCT recipients.

An Italian experience on renal transplant recipients reported a mortality rate of 25% (5/20) despite 95%, 55%, and 30% of patients received HIV protease-inhibitors, dexamethasone and tocilizumab, respectively.<sup>9</sup> The Spanish observation on 18 SOT recipients [kidney (44.4%), liver (33.3%), heart (22.2%)], who developed COVID-19 at a median interval since transplantation of 9.3 years, reported a fatality rate of 27.8%.<sup>10</sup> Another Italian report showed a high-mortality in long-term liver transplant recipients (>10 years): 3% (3/111) acquired pneumonia and all died. Conversely, 7.5% (3/40) of short-term liver transplant recipients (<2 years) experienced an uneventful course of disease. Interestingly, only 10% of long-term liver transplant recipients

had a full immunosuppressive therapy (IST) and a higher proportion of them displayed risk factors for COVID-19 mortality, such as hypertension, cardiovascular disease, chronic renal failure, older age.<sup>11</sup>

In allo-HSCT setting, it is plausible that acquiring COVID-19 in late post-engraftment phase, after achieving a good T and B-cell immune-recovery, may not affect the outcome. Probably IST in the context of c-GVHD could prevent the transition from pro-inflammatory towards anti-inflammatory wound-healing macrophages reaction, which usually promote the typical lung tissue damage of ARDS. In our report, since a therapeutic serum level has been maintained until 43-day, we would exclude any role of cyclosporine withdrawal with the hyper-inflammatory rate observed starting from 36-day. For allo-HSCT recipients, we assume that pre-engraftment and early post-engraftment phases are the timeframe at higher risk for fatal outcome due to severe lymphopenia and high risk of progression to LRTI by CARV.<sup>12</sup> Our case suggests, also, an atypical radiological evolution of SARS-2-CoV pneumonia in HSCT recipients, persisting for over 6-weeks since presentation of a predominately crazy-paving ground-glass opacities pattern without evolution in the consolidation phase.<sup>13</sup> This finding may be due to the onset of pneumonia within 30-day after allo-HSCT with anti-thymocyte globulin as part of conditioning regimen, which justifies the absence of acquired immunity determining a persistent viral replication in low respiratory tract, probably resulting in a prolonged virus-induced cytopathic effect. Considering the pivotal role of IL-6 cascade resulting in a cytokine-realized syndrome and of endothelium damage resulting in a pro-coagulative status, the administration of both tocilizumab and defibrotide could at least have contained the inflammatory lung tissue damage. Allo-HSCT setting exposes the recipient in pre-engraftment and early post-engraftment phase to a profound degree of immunosuppression that prevents him from containing virus spread resulting in a severe clinical course and high risk of mortality, due also to the absence of an effective antiviral therapy. The use of convalescent plasma should be evaluated in immunocompromised hosts to replace impaired antibody response.

In conclusion, we report the first case of SARS-2-CoV pneumonia in early post-engraftment phase of allo-HSCT. Facing a complicated clinical course, despite the administration of almost all available therapeutic options except for convalescent plasma against SARS-2-CoV, including the experimental agent remdesivir, we have not succeeded in containing viral replication resulting in patient's death, which was also ultimately due to breakthrough invasive aspergillosis. In the context of a

global pandemic, our experience confirms the role of screening allo-HSCT candidates for SARS-2-CoV infection, as recently stated by European Bone Marrow Transplantation society.<sup>14</sup> For those who test positive, a careful transplant planning delaying the procedure is critical to both limit the risk of progression to severe LRTI in pre-engraftment phase and ensure an optimal care of hematological malignancy.

## References

1. Ministero della Salute (IT). Available at: <http://www.salute.gov.it/portale/home.html>. Accessed May 21, 2020.
2. Zhou F, Yu T, Du R, et al. Clinical course and risk factors for mortality of adult inpatients with COVID-19 in Wuhan, China: a retrospective cohort study. *Lancet*. 2020;395:1054–1062.
3. Ruan Q, Yang K, Wang W, et al. Clinical predictors of mortality due to COVID-19 based on an analysis of data of 150 patients from Wuhan, China. *Intensive Care Med*. 2020;46:846–848.
4. Jin XH, Zheng KI, Pan KH, et al. COVID-19 in a patient with chronic lymphocytic leukemia. *Lancet Haematol*. 2020;7:e351–e352.
5. Zhang X, Song K, Tong F, et al. First case of COVID-19 in a patient with multiple myeloma successfully treated with tocilizumab. *Blood Adv*. 2020;4:307–310.
6. Huang J, Lin H, Wu Y, et al. COVID-19 in post-transplant patients: report of two cases. *Am J Transplant*. 2020;20:1879–1881.
7. Malard F, Genthon A, Brissot E, et al. COVID-19 outcome in patients with hematological disease. *Bone Marrow Transplant*. 2020 May 6. [Epub ahead of print].
8. Li W, Wang D, Guo J, et al. COVID-19 in persons with chronic myeloid leukemia. *Leukemia*. 2020;34:1799–1804.
9. Alberici F, Delbarba E, Manenti C, et al. Management of patients on dialysis and with kidney transplantation during the SARS-CoV-2 (COVID-19) pandemic in Brescia, Italy. *Kidney Int Rep*. 2020;4:580–585.
10. Fernández-Ruiz M, Andrés A, Loinaz C, et al. COVID-19 in solid organ transplant recipients: a single-center case series from Spain. *Am J Transplant*. 2020;20:1849–1858.
11. Bhoori S, Rossi RE, Citterio D, et al. COVID-19 in long-term liver transplant patients: preliminary experience from an Italian transplant centre in Lombardy. *Lancet Gastroenterol Hepatol*. 2020;5:532–533.
12. Hirsch HH, Martino R, Ward KN, et al. Fourth European Conference on Infections in Leukemia (ECIL-4): guidelines for diagnosis and treatment of human respiratory syncytial virus, parainfluenza virus, metapneumovirus, rhinovirus and coronavirus. *Clin Infect Dis*. 2013; 56:258–266.
13. Shi H, Han X, Jiang N, et al. Radiological findings of 81 patients with COVID-19 pneumonia in Wuhan, China: a descriptive study. *Lancet Infect Dis*. 2020;20:425–434.
14. Ljungman P, Mikulska M, de la Camara R, et al. The challenge of COVID-19 and hematopoietic cell transplantation; EBMT recommendations for management of hematopoietic cell transplant recipients, their donors, and patients undergoing CAR T-cell therapy. *Bone Marrow Transplant*. 2020 May 13. [Epub ahead of print].