

Letter to the Editors-in-Chief

## Occurrence of pulmonary embolism in a patient with mild clinical expression of COVID-19



Dear Editor,

We would like to give a further contribution to the current issue concerning the occurrence of a hypercoagulable state and its clinical consequence in the course of the COVID-19 by reporting the clinical case of one of the authors (CV).

CV, a 70 y.o. man, became feverish in the evening of March 11th, but fever completely disappeared the day after. In the following days CV complained of sore throat, severe myalgia, weakness and anorexia. Cough or shortness of breath was not present. Since CV lives in Milan and is a medical doctor having contacts with a lot of people, a SARS-CoV-2 infection was supposed. In accordance with the recommendations of the National and Regional Health Authority for the pandemic outbreak, CV decided to stay at home, assuming only intermittent therapy to improve myalgia (diclofenac). A week after the symptoms progressively improved and only mild sore throat persisted.

On April 2nd dyspnoea, together with increased cardiac rate (110–120 bpm), suddenly appeared and then it was decided to call on the Emergency Room of the Ospedale Maggiore-Policlinico of the University of Milan. Here an arterial blood sample was taken that revealed the signs of respiratory alkalosis together with metabolic acidosis. A chest-x-ray film did not show significant abnormalities. A computed tomography (CT) of the chest with contrast agent was performed. It showed the presence of bilateral pulmonary embolism (PE) involving secondary and segmental branches (Fig. 1). Only few limited sub-pleural ground glass areas were noted. Peripheral blood examination documented the presence of very high level of D-dimer (more than 5 times the normal values), with light reduction of platelet count and a C-reactive protein just above the normal limits.

CV was transferred to an internal medicine unit reserved to COVID-19 suspected patients, since the clinical condition did not require admission to an intensive care unit (ICU). Here treatment with anticoagulant therapy (enoxaparin 8000 U BID) was introduced, and a respiratory support with low flux oxygen (FiO<sub>2</sub> 24%) was given. No signs of significant PAPs increase or overcharge of the right cardiac ventricle were observed on echocardiographic examination. No signs of deep venous thrombosis were found on Doppler examination. A nasal-pharyngeal swab sample taken at the admission time confirmed the presence of SARS-CoV-2 infection.

Rapid improvement of respiratory function and reduction of cardiac rate was recorded in the following few days. CV was then discharged by the hospital on April 7th since oxygen support was no more needed. Anticoagulant therapy was shifted to apixaban 5 mg BID to be continued for six months.

The occurrence of a hypercoagulable state in the course of critically ill ICU patients with COVID-19 is an emerging issue [1]. This may induce a large variety of intravascular thrombotic phenomena ranging

from fatal disseminated intravascular coagulation (DIC) to a more limited venous and arterial thrombosis, namely PE. It has been suggested that many deaths during COVID-19 in patients requiring intensive care unit (ICU) admission could be ascribed to this coagulopathy, and overall to incidental DIC in patients with severe pneumonitis [1]. In the Wuhan cohort, during pandemic outbreak, the presence of coagulation cascade activation was noted [2], and, in a retrospective study [3], it was reported that prophylactic heparin treatment in ICU-admitted patients with proven COVID-19 pneumonia reduced the mortality rate in comparison to the patients that did not receive it.

It has been suggested that infection-related release of large amounts of inflammatory cytokines can cause an endothelial damage, activate the coagulation cascade, and consequently may predispose to thrombotic events that may also occur in pulmonary vasculature [4]. This event may probably contribute to the progression of pulmonary dysfunction and increase the mortality rate in these patients.

These data pushed the International Society on Thrombosis and Haemostasis to propose a guidance on diagnostic and therapeutic approach to coagulopathy in COVID-19 [1]. These guidelines suggest to perform D-dimer, prothrombin time, and platelet count in all patients who present with COVID-19, and to admit to the hospital those patients with important signs of coagulopathy (namely very high levels of D-dimer), also in absence of other concerns. In view of the risk of occurrence of such a hypercoagulable state, the use of prophylactic dose of low molecular weight heparin in all the patients requiring hospitalization for COVID-19, including those not requiring ICU has been proposed [1]. A recent study on ICU-admitted patients with COVID-19 pneumonia has shown that thrombotic events were recorded in 31% of them with a large prevalence of PE (81%). It is worth noting that all of these patients received thromboprophylaxis [5]. As a consequence of these data, an early initiation of therapeutic anticoagulation in critically ill patients with significant coagulation abnormalities could be indicated [4,6]. Furthermore, a more extensive use of CT pulmonary angiography in order to document incidental PE should be considered in all hospitalized patients with laboratory signs of coagulopathy [7].

The present case report may suggest some additional considerations regarding the therapeutic and clinical approach to SARS-CoV-2-infected patients.

- Even patients with mild clinical manifestations, not requiring hospital admission may develop PE in the course of COVID-19. This suggests that inflammation-related endothelial damage could not be related to the presence and severity of COVID-19 pneumonia. Furthermore, the performance of coagulation tests could be indicated in all patients having certain and suspected SARS-CoV-2 infection.
- Hypercoagulable state may persist for long time and also induce late

<https://doi.org/10.1016/j.thromres.2020.05.002>

Received 1 May 2020; Accepted 2 May 2020

Available online 05 May 2020

0049-3848/ © 2020 Elsevier Ltd. All rights reserved.

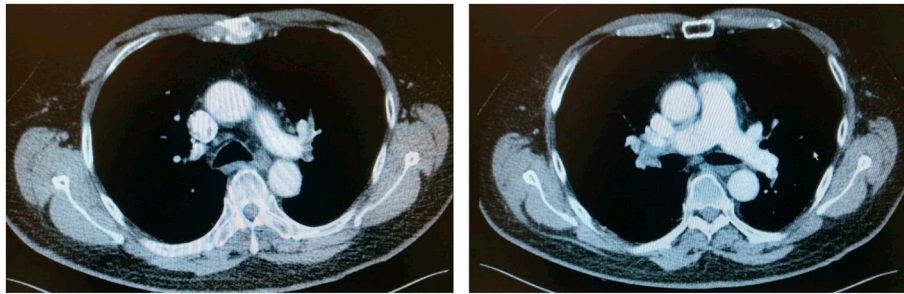


Fig. 1. CT chest showing bilateral pulmonary embolism involving secondary and segmental branches.

thromboembolic events.

- c. At least prophylactic dose of anticoagulant therapy could be introduced in all patients with COVID-19, including non-hospitalized patients.

#### Declaration of competing interest

The authors have no conflict of interest to declare.

#### References

- [1] J. Thachil, N. Tang, N.S. Gando, et al., ISTH interim guidance on recognition and management of coagulopathy in COVID 19, *J. Thromb. Haemost.* 18 (2020) 1023–1026, <https://doi.org/10.1111/JTH.14810>.
- [2] D. Wang, B. Hu, C. Hu, et al., Clinical characteristics of 138 hospitalized patients with 2019 novel coronavirus-infected pneumonia in Wuhan, China, *JAMA* (2020), <https://doi.org/10.1001/jama.2020.1585>.
- [3] N. Tang, H. Bai, X. Chen, J. Gong, D. Li, Z. Sun, Anticoagulant treatment is associated with decreased mortality in severe coronavirus disease 2019 patients with coagulopathy, *J. Thromb. Haemost.* 18 (2020) 1094–1099, <https://doi.org/10.1111/jth.14817>.
- [4] C.D. Barrett, H.B. Moore, M.B. Yaffe, E.E. Moore, ISTH interim guidance on recognition and management of coagulopathy in COVID 19: a comment, *J. Thromb. Haemost.* (2020), <https://doi.org/10.1111/JTH.14860>.
- [5] F.A. Klok, M.J.H.A. Kruip, N.J.M. van der Meer, et al., Incidence of thrombotic complications in critically ill ICU patients with COVID-19, *Thromb. Res.* (2020), <https://doi.org/10.1016/j.thromres.2020.04.013>.
- [6] A. Ciavarella, F. Peyvandi, I. Martinelli, Where we stand with antithrombotic therapy in patients with COVID-19, *Thromb. Res.* (2020), <https://doi.org/10.1016/j.thrombres.2020.04.023>.
- [7] D.C. Rotzinger, C. Beigelman-Aubry, C. von Garnier, S.D. Qanadli, Pulmonary embolism in patients with COVID-19: time to change the paradigm of computed tomography, *Thromb Res.* 190 (2020) 58–59.

Claudio Vitali<sup>a,\*</sup>, Antonina Minniti<sup>b</sup>, Roberto Caporali<sup>b,c</sup>,  
Nicoletta Del Papa<sup>b</sup>

<sup>a</sup> *‘Mater Domini’ Humanitas Hospital, Via Gerenzano 2, 21053 Castellanza, Italy*

<sup>b</sup> *Dept Rheumatology, ASST Pini-CTO, Piazza Cardinal Ferrari 1, 20122 Milan, Italy*

<sup>c</sup> *University of Milan, Dept. of Clinical Sciences and Community Health, Research Center for Adult and Pediatric Rheumatic Diseases, Milan, Italy*

*E-mail addresses: c.vitali@yahoo.it (C. Vitali),  
nicoletta.delpapa@asst-pini-cto.it (N. Del Papa).*

\* Corresponding author.