

Contents lists available at [ScienceDirect](http://ScienceDirect.com)

Journal of Dermatological Science

journal homepage: www.jdsjournal.com

Invited Review Article

Cutaneous manifestations of COVID-19: Report of three cases and a review of literature

Muskaan Sachdeva^{a,1}, Raffaele Gianotti^{b,c,1}, Monica Shah^a, Lucia Bradanini^d, Diego Tosi^e, Stefano Veraldi^c, Michael Ziv^f, Eyal Leshem^{g,h}, Roni P. Dodiuk-Gad^{f,i,j,*}^a Faculty of Medicine, University of Toronto, Toronto, Ontario, Canada^b Institute of Dermatological Sciences, University of Milan, Italy^c Department of Pathophysiology and Transplantation, Università degli Studi, Fondazione IRCCS, Cà Granda Ospedale Maggiore Policlinico, Milan, Italy^d Department of Biomedical and Clinical Sciences "Luigi Sacco", University of Milan, Italy^e Division of Infectious Diseases, ASST Fatebenefratelli Sacco, Luigi Sacco Hospital, Milan, Italy^f Dermatology Department, Emek Medical Center, Israel^g Institute for Travel and Tropical Medicine, Sheba Medical Centre, Israel^h School of Medicine, Tel Aviv University, Israelⁱ Bruce Rappaport Faculty of Medicine, Technion - Institute of Technology, Israel^j Department of Medicine, University of Toronto, Toronto, Ontario, Canada

ARTICLE INFO

Article history:

Received 24 April 2020

Accepted 24 April 2020

Keywords:

Cutaneous manifestations

COVID-19

Skin

Review

ABSTRACT

Background: Various cutaneous manifestations have been observed in patients with COVID-19 infection. However, overall similarities in the clinical presentation of these dermatological manifestations have not yet been summarized.

Objective: This review aims to provide an overview of various cutaneous manifestations in patients with COVID-19 through three case reports and a literature review.

Methods: A literature search was conducted using PubMed, OVID, and Google search engines for original and review articles. Studies written in the English language that mentioned cutaneous symptoms and COVID-19 were included.

Results: Eighteen articles and three additional cases reported in this paper were included in this review. Of these studies, 6 are case series and 12 are case report studies. The most common cutaneous manifestation of COVID-19 was found to be maculopapular exanthem (morbilliform), presenting in 36.1% (26/72) patients. The other cutaneous manifestations included: a papulovesicular rash (34.7%, 25/72), urticaria (9.7%, 7/72), painful acral red purple papules (15.3%, 11/72) of patients, livedo reticularis lesions (2.8%, 2/72) and petechiae (1.4%, 1/72). Majority of lesions were localized on the trunk (66.7%, 50/72), however, 19.4% (14/72) of patients experienced cutaneous manifestations in the hands and feet. Skin lesion development occurred before the onset of respiratory symptoms or COVID-19 diagnosis in 12.5% (9/72) of the patients, and lesions spontaneously healed in all patients within 10 days. Majority of the studies reported no correlation between COVID-19 severity and skin lesions.

Conclusion: Infection with COVID-19 may result in dermatological manifestations with various clinical presentations, which may aid in the timely diagnosis of this infection.

© 2020 Japanese Society for Investigative Dermatology. Published by Elsevier B.V. All rights reserved.

1. Introduction

As of April 20th, 2020, COVID-19 (severe acute respiratory syndrome coronavirus 2 [SARS-CoV-2] or, previously called 2019-nCoV) initially reported in Wuhan, China [1] has been diagnosed in

more than 2.4 million people worldwide [2]. The high rate of infectivity, low virulence and asymptomatic transmission have resulted in its rapid spread across geographic boundaries, leading to a pandemic [3]. The outbreak of COVID-19 has been declared a Public Health Emergency of International Concern by the World Health Organization (WHO) and presents a great challenge for the health care communities across the globe [4].

SARS-CoV 2 is an enveloped virus composed of positive sense single-stranded RNA and belongs to the coronavirus family. [1] The virus enters cells through the angiotensin converting enzyme

* Corresponding author at: Ruth and Bruce Rappaport Faculty of Medicine, Technion Institute of Technology, 1 Efron St., Bat Galim Haifa, 3525433, Israel.

E-mail address: rdodiukgad@gmail.com (R.P. Dodiuk-Gad).

¹ Equal contribution.

2 (ACE2) receptor, found on the surface of cells [1]. The lungs are the primary site of infection for COVID-19, with patients presenting symptoms ranging from a mild flu-like symptoms to fulminant pneumonia and potentially lethal respiratory distress [5].

Interestingly, there have been many COVID-19 cases reporting cutaneous manifestations [6–23]. The purpose of this article is to report three relevant cases and provide a literature review of various cutaneous manifestation in patients with COVID-19.

2. Case 1

A 71-year-old Caucasian woman presented to the Emergency Department in Milan, complaining of fever, productive cough and worsening shortness of breath which started 10 days before. The patient was otherwise healthy with no co-morbidities, medications or previous adverse drug reactions. She was living in Milan with her husband, who was diagnosed with COVID-19. Laboratory tests revealed a normal white blood cells and platelet count (WBC 6470/mm, PLT 290.000/mmc), normal liver and kidney function and an increased C-reactive protein (49.4 mg/L). Blood cultures were negative. Bilateral interstitial pneumonia was found on chest x-ray. Naso-pharyngeal swab tested for SARS-CoV-2 RNA amplification resulted positive. She was admitted to the Infectious Disease Department and started off-label antiviral therapy with lopinavir/ritonavir and hydroxychloroquine, following Italian Society of Infectious and Tropical Diseases (SIMIT) guidelines and empiric antibiotic therapy with third generation cephalosporin (ceftriaxone). Other drugs administered during hospitalization were: rabeprazole, paracetamol, metoclopramide, dihydrocodeine, lactulose and subcutaneous low molecular weight heparin. In the subsequent days, she promptly recovered: she never had fever, we have been able to gradually decrease oxygen flow and on the 30th of march, antiviral and antibiotic therapies were discontinued. Over the following days a maculopapular itchy rash appeared on the trunk resembling a Grover disease (Fig. 1).

3. Case 2

A 77-year-old Caucasian woman was admitted to the hospital in Milan, due to neck lymphonodal enlargement, fever, cough and diffuse maculopapular exanthem (morbilliform) on the trunk (Fig. 2a). One day later during hospitalization, she also developed macular hemorrhagic rash on the legs (Fig. 2b). Naso-pharyngeal swab tested for SARS-CoV-2 RNA amplification were positive. No signs of pneumonia were found on the chest x ray. Treatment consisted of antiviral therapy using lopinavir/ritonavir and hydroxychloroquine and subcutaneous low molecular weight heparin. Gradual spontaneous improvement of skin lesions appeared.

4. Case 3

A 72-year-old Caucasian woman, otherwise healthy, presented to the Emergency Department in Milan with headache, arthralgia, myalgia and fever. Four days later, a papular-vesicular, pruritic eruption appeared on sub-mammary folds, trunk and hips (Fig. 3). Laboratory examination conducted revealed mild increase in WBC, C-reactive protein and erythrocyte sedimentation rate (ESR). COVID-19, tested with naso-pharyngeal swab, was positive. Chest X ray was negative for pneumonia. Complete remission of both general and cutaneous manifestations was observed approximately ten days after the beginning of the clinical picture.

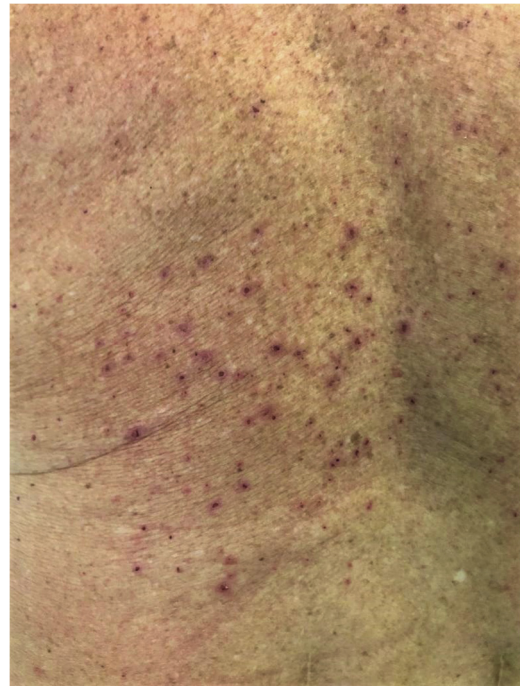

Fig. 1. Cutaneous manifestation of COVID-19 in Case 1.

5. Methods

A literature search was conducted using PubMed, OVID and Google search engines for original and review articles published since the onset of the current COVID-19 epidemic to April 20, 2020. Search terms “COVID-19”, “2019-nCoV”, “SARS-CoV-2” and “coronavirus” were used in combination with “skin”, “dermatology”, “cutaneous”, “urticaria” and “rash”. We also performed extensive hand searching of reference lists of relevant papers and reports. The studies that did not mention cutaneous symptoms or did not include any relevant information in the English language were excluded.

We extracted the following data from included studies: author, publication year, region, number of participants with skin signs, age, sex, suspected or confirmed status for COVID-19, cutaneous signs and its location, timeline and healing duration, associated symptoms, correlation with COVID-19 severity with skin lesions and treatments for COVID-19 infection. When extracting

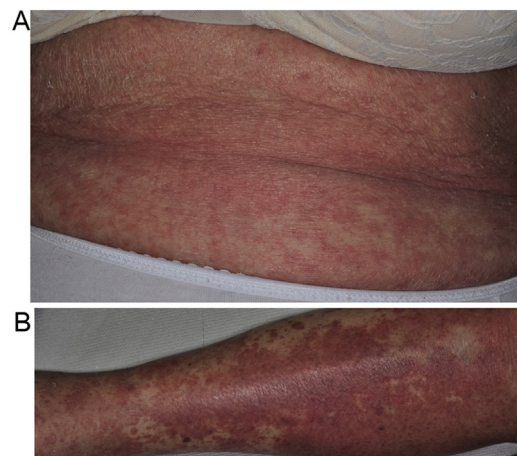


Fig. 2. (a) Cutaneous manifestation of COVID-19 on trunk in Case 2. (b) Cutaneous manifestation of COVID-19 on legs in Case 2.

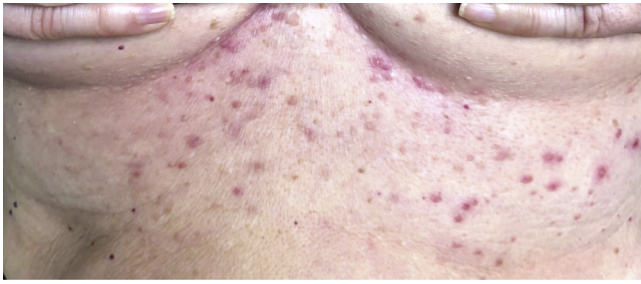


Fig. 3. Cutaneous manifestation of COVID-19 in Case.

information from the studies, pairs of researchers conferred to compare findings and reach consensus. Where consensus was not reached, an independent researcher was consulted. We also searched for grey literature including advisories from professional societies, expert commentaries, blogposts, magazine articles, newspaper articles and social media posts to retrieve relevant information. The information from grey literature was not included in the results section, however, it has been summarized in the Supplemental File 1.

6. Results

Eighteen articles and three additional cases (reported in this review) that met the aforementioned inclusion criteria were summarized in this review. All studies were published during February and April 2020, with 61.1% of articles published in April. There are 6 case series [6–9,16,20], and 12 case reports [10–15, 17–19,21–23]. The mean patient age was 53.6 years, with patients between 15 days and 84 years of age. Males accounted for 38.9% of reported cases, females accounted for 27.8% of cases, and the sex of 37.5% cases was not reported. In terms of COVID-19 diagnosis, 2.8% patients were suspected cases and 97.2% were confirmed cases. Table 1 summarizes the cases with COVID-related cutaneous manifestations in the included articles.

A generalized macular or maculopapular exanthem (morbilliform) appeared to be the most common cutaneous manifestation in COVID-19, with 36.1% (26/72) of patients presenting such lesions on their skin. A papulovesicular rash (vesicles) was seen in 34.7% (25/72) of patients. Urticaria occurred in 9.7% (7/72) of reported patients, and the presence of painful acral red purple papules with or without vesicles was seen in 15.3% (11/72) of patients overall. Lastly, 2.8% (2/72) presented with livedo reticularis lesions, and 1 patient (1.4%) presented with petechiae. Of the 72 cases, lesion location was reported in 67 patients, with the majority of lesions being found on the trunk, hands and feet. Overall, 69.4% (50/72) of patients experienced lesions on the trunk. Additionally, 19.4% (14/72) of patients experienced cutaneous manifestations in the hands and feet.

The timing of skin lesion development ranged between patients, from development 3 days before COVID-19 diagnosis to 13 days after diagnosis. In the examined cases, 12.5% (9/72) of patients presented with cutaneous lesions at diagnosis or onset of COVID-19 symptoms, while 69.4% (50/72) of patients presented with lesions after the onset of respiratory symptoms or of COVID-19 diagnosis. The timing of skin lesion development was not reported in 18.1% (13/72) of patients. Of the 49 patients who developed lesions after respiratory symptom onset or of COVID-19 diagnosis, 74.0% (37/50) developed cutaneous pathology within 7 days, and 6.0% (3/50) reported lesions after 7 days. Of the 50 cases with reported healing times, 100% of patients reported healing of cutaneous lesions, with healing times up to 10 days. 48.0% of lesions healed within 7 days (24/50) and 50.0% of lesions healed

after 7 days (25/50), and healing time was unspecified for one case (2.0%).

Five studies reported on the possible association between COVID-19 and skin lesion severity in 23 patients. In 21 patients (91.3%), the severity of cutaneous lesions was unlikely to be or was not correlated with COVID-19 severity. Contrarily, in 2 separate reports by Mahé [13] and Estébanez [15], COVID-19 and skin lesion severity were linked in 2 patients (8.7%). Also, in most of the included studies, histological findings were not reported.

7. Discussion

Dermatologic manifestations of COVID-19 are rare, with common clinical features including fever, dry cough, shortness of breath, myalgia and fatigue seen in relatively large-scale case studies of COVID-19 pneumonia patients [12,24–26]. Skin manifestations were reported only in case reports and two case series. In this review, we summarized the information of all the 72 COVID-19 patients with cutaneous manifestations, as reported in the literature (Table 1).

The most prominent case study of cutaneous manifestations of COVID-19 published by Recalcati et al. [7] in Lombardy, Italy included 88 patients. In this study, 20.4% of the confirmed COVID-19 patients (18/88) had developed cutaneous manifestations. It was found that most cutaneous presentations were erythematous rash (77.8% or 14/18) with few cases of urticaria (16.7% or 3/18) and vesicle formation (5.6% or 1/18). These findings reflect a similar distribution of cutaneous manifestations as seen in our review.

Cutaneous manifestations are important in the diagnosis of various infectious diseases, such as toxic shock syndrome, meningococemia, rickettsial diseases, measles, and scarlet fever [27–31]. As COVID-19 has a tendency to produce asymptomatic cases for up to 14 days after infection, cutaneous manifestations may serve as an indicator of infection, aiding in timely diagnosis. In this review, 12.5% (9/72) of patients presented with cutaneous lesions at onset. Furthermore, physicians' awareness of the cutaneous symptoms related to COVID-19 infection is critical in preventing misdiagnosis of disease, such as the misdiagnosis of dengue as reported by Joob et al. [10]

The mechanisms of COVID-19 cutaneous disturbances are not yet well known, but some common theories are prevalent. It can be postulated that the viral particles present in the cutaneous blood vessels in patients with COVID-19 infection could lead to a lymphocytic vasculitis similar to those observed in thrombophilic arteritis induced by blood immune complexes that activate cytokines. Keratinocytes may be a secondary target after Langerhans cells activation, inducing a spectrum of different clinical manifestation [6,32]. It can be postulated that the virus does not target the keratinocyte, but rather immune response to infection leads to Langerhans cells activation, resulting in a state of vasodilation and spongiosis [32]. Further theories suggest livedo reticularis-resembling manifestations can result due the accumulation of microthromboses originating in other organs, thus reducing blood flow to the cutaneous microvasculature system [8]. Similarly, low grade disseminated intravascular coagulation and hypoxia-related accumulation of deoxygenated blood in venous plexes may further explain such manifestations [8]. Additionally, pauci-inflammatory thrombogenic vasculopathy with deposition of C5b-9 and C4d as well as co-localization of these with COVID-19 spike glycoproteins was reported by Magro et al. [33]. It is still unclear whether cutaneous symptoms are a secondary consequence of respiratory-related infection or a primary infection of the skin itself. It is more likely that a combination of such mechanisms is responsible for the cutaneous manifestations found in COVID-19+ individuals.

Table 1
Characteristics and cutaneous manifestations of suspected and confirmed COVID-19 cases published in scientific literature.

Author, Publication Year	Region	Patients with Skin Signs (n)	Age, Sex	Suspected or Confirmed COVID-19	Cutaneous Manifestations									
					Signs (n)	Location	Timing	Associated Symptoms	Healing Duration	Correlation of COVID-19 Severity with Skin Lesions	Treatments for COVID-19 Infection			
Gianotti, 2020 [6]	Milan, Italy	5			Cases 1, 2, 4, 5: NR, NR Case 3: NR, M	Case 1-5: C	Case 1: Exanthema Case 2: Purpuric maculo-papulo-vesicular rash Case 3: Papular erythematous exanthema Case 4 and 5: Diffuse maculopapular eruption clinically suggestive for Grover disease	Case 1: Trunk and limbs Case 2: NR Case 3, 4, and 5: Trunk	NR	NR	NR	NR	NR	
Recalcatti, 2020 [7]	Lombardy, Italy	18	NR	C			Erythematous rash (14), Widespread urticaria (3), chickenpox-like vesicles (1)	Trunk	8 developed at onset, 10 after hospitalization	Little to no itching	Healed within a few days	No correlation seen with disease severity	NR	NR
Manalo 2020 [8]	Atlanta, Georgia	2			Case 1: 67, M Case 2: 47, F	Case 1,2: C	Case 1: Transient non-pruritic blanching unilateral livedoid patch resembling livedo reticularis Case 2: Unilateral asymptomatic rash resembling livedo reticularis	Case 1: Right anterior thigh Case 2: Right leg	Case 1: Symptoms began 7 days after initial onset of COVID-19 symptoms, 3 days prior COVID-19 diagnosis Case 2: 10 days after testing positive for COVID-19	Case1,2: NR	Case 1: 19 hours (eruption) Case 2: 20 minutes	NR	NR	NR
Zhang 2020 [9]	Wuhan, China	7	Median age of 59, 4 M/3F	C			Acro-ischemia presentations including finger/toe cyanosis, skin bulla and dry gangrene	Extremities	Median time 19 days (11-23 days)	NR	NR	NR	Low molecular weight heparin treatment	NR
Joob 2020 [10]	Thailand	1	NR, NR	C			Skin rash with petechiae	NR	NR	None	NR	NR	NR	NR
Jimenez 2020 [11]	Madrid, Spain	1	84, F	C			Erythematopurpuric, millimetric, coalescing macules	Flexural regions, peri-axillary	3 days of hospitalization, 11 days since onset	NR	NR	Unlikely	Hydroxychloroquine and lopinavir/ritonavir	NR
Hunt 2020 [12]	New York, USA	1	20, M	C			Diffuse, morbilliform, maculopapular, and nonpruritic rash	Trunk and extremities sparing the face	Along with fever, before diagnosis	NR	NR	NR	NR	NR
Mahé 2020 [13]	Colmar, France	1	64, F	C			Erythematous rash	Antecubital fossa, then to the trunk and axillary folds	Four days after fever	NR	Day 9 of disease	Yes	Paracetamol	NR
Fernandez 2020 [14]	Madrid, Spain	1	32, F	C			Urticariiform rash	NR	6 days after the onset of symptoms	None	Improvement in 5 day-period 10 days	NR	Hydroxychloroquine and azithromycin	NR
Estébanez 2020 [15]	Spain	1	28, F	C			Pruritic lesions/ erythematous-yellowish papules	Confluent Heel	13 days after being diagnosed	Lesions persisted and became erythematous plaques that were both hardened and pruritic	NR	Yes	Paracetamol	NR
Zhang 2020 [16]	Wuhan, China	2	57 years (25-87),	C			Urticaria	NR	NR	NR	NR	Unlikely	NR	NR

Henry 2020 [17]	Orléans, France	1	71 M/ 69F 27, F	C	Disseminated erythematous plaques eruption, urticaria	Face, hand and feet (acral involvement)	48 hours before onset of respiratory symptoms	Pruritis	NR	NR	Paracetamol and antihistamines
Kamali Aghdam 2020 [18]	Tehran, Iran.	1	15- days, M	C	Cutaneous mottling	NR	NR	NR	2 days after entering hospital.	NR	Proper fluid therapy, oxygen therapy, anti-biotic therapy by Vancomycin (10 mg/kg/q8h) and Oseltamivir (3 mg/kg/12 h)
Mazzotta 2020 [19]	Italy	1	13, M	S	Erythematous-violet, rounded lesions of 5-15 mm in diameter, with blurred limits	Plantar surface of 1 st right toe and dorsal surface of the 2 nd toe on both feet	NR	Intense itching and burning on the foot lesions	After a few days	NR	NA
Alramthan 2020 [20]	Qatar	2	Case 1: 27, F Case 2: 35, F	C	Case 1,2: Acral ischemic lesions presenting as red-purple papules	Case 1,2: Dorsal aspect of fingers bilaterally	NR	NR	NR	NR	NR
Najarian 2020 [21]	New Jersey, USA	1	58, M	C	Erythematous macules with islands of normal appearing skin between them, arranged in a morbilliform pattern	Legs, thighs, forearms, arms, shoulders, back, chest, abdomen	1 day after onset of respiratory symptoms	Pain in legs and hands	1 day	NR	Azithromycin (500 mg first day, 250 mg 4 days), benzonatate 100 mg every 6 hours
Kolivras 2020 [22]	Brussels, Belgium	1	23, M	C	Violaceous, infiltrated plaques on an erythematous background	Dorsal aspect of toes and lateral sides of feet	3 days after onset of respiratory symptoms	Pain	NR	NR	NR
Marzano 2020 [23]	Italy	22	Median age 60, 16 M/6F	C	Varicella-like papulovesicular exanthem	Trunk, limbs	Median latency time from systemic symptoms to exanthem was 3 days (range of -2 to 12 days)	Itching (n = 9)	Median duration was 8 days (range 4 to 15 days)	NR	NR
Present Case 1	Milan, Italy	1	71, F	C	Maculo-papular itchy rash resembling Grover disease	Trunk	Within days of discontinued treatment	Itching	NR	NR	Lopinavir/ritonavir and hydroxychloroquine. Other administered drugs include: rabeprazole, paracetamol, metoclopramide, dihydrocodeine, lactulose and subcutaneous low molecular weight heparin.
Present Case 2	Milan, Italy	1	77, F	C	Diffuse maculopapular exanthem (morbilliform), macular hemorrhagic rash	Trunk, legs	First dermatological examination revealed guttate psoriasis, symptoms presenting four days later, lesions presenting five days later	NR	Progressive healing seen with treatment	NR	Lopinavir/ritonavir and hydroxychloroquine and subcutaneous low molecular weight heparin
Present Case 3	Milan, Italy	1	72, F	C	Papular-vesicular, pruritic eruption	Sub-mammary folds, trunk, hips	4 days after onset of symptoms	NR	10 days after onset	NR	NR

NR: not reported; M: male; F: female; y: years; S: suspected case; C: confirmed case.

There are several limitations that must be considered for this literature review. Firstly, the small sample size used in this analysis restricts the ability to draw strong conclusion applicable to whole populations. Additionally, since scientific understanding of COVID-19 and associated dermatological symptoms is currently evolving at this stage, the information contained in this review is based mainly on the limited early experience with COVID-19. Due to limitations in the availability of COVID-19 literature, the recency of the COVID-19 outbreak, and language-related exclusion criteria, this paper only examines 72 cases of COVID-19 related cutaneous pathologies. Lastly, we must take into account the possibility of dermatologic side effects experienced from medications used by participants.

Given the current collection of evidence, it is suggested that COVID-19 can have dermatological manifestations. As a result, physicians should be aware of these important clinical manifestations that may aid in the timely diagnosis of COVID-19 infection. However, further literature and research is required to validate and elucidate an understanding of COVID-19 related cutaneous manifestations.

Funding

None.

Declaration of Competing Interest

None. The authors have no conflict of interest to declare.

Acknowledgements

None.

Appendix A. Supplementary data

Supplementary material related to this article can be found, in the online version, at doi:<https://doi.org/10.1016/j.jdermsci.2020.04.011>.

References

- [1] Y.R. Guo, Q.D. Cao, Z.S. Hong, Y.Y. Tan, S.D. Chen, H.J. Jin, K.S. Tan, D.Y. Wang, Y. Yan, The origin, transmission and clinical therapies on coronavirus disease 2019 (COVID-19) outbreak—an update on the status, *Mil. Med. Res.* 13 (March (1)) (2020) 11.
- [2] World Health Organization, Coronavirus Disease (COVID-19) Outbreak Situation [Internet] [cited 2020 Apr 22]. Available from: World Health Organization, 2020. <https://covid19.who.int/>.
- [3] Y. Han, H. Yang, The transmission and diagnosis of 2019 novel coronavirus infection disease (COVID-19): a Chinese perspective, *J. Med. Virol.* 6 (March) (2020), doi:<http://dx.doi.org/10.1002/jmv.25749> [Epub ahead of print].
- [4] Coronavirus Disease (COVID-19) - Events as They Happen [Internet]. Rolling Updates on Coronavirus Disease (COVID-19)., World Health Organization, 2020. [cited 2020 Apr 13]. Available from: <https://www.who.int/emergencies/diseases/novel-coronavirus-2019/events-as-they-happen>.
- [5] P. Zhai, Y. Ding, X. Wu, J. Long, Y. Zhong, Y. Li, The epidemiology, diagnosis and treatment of COVID-19, *Int. J. Antimicrob. Agents* 28 (March) (2020) 105955, doi:<http://dx.doi.org/10.1016/j.ijantimicag.2020.105955> [Epub ahead of print].
- [6] R. Gianotti, P. Zerbi, R. Dodiuk-Gad, Histopathological study of skin dermatoses in patients affected by COVID-19 infection in the Northern part of Italy, *J. Cosmet. Dermatol. Sci. Appl.* (2020) In press.
- [7] S. Recalcati, Cutaneous manifestations in COVID-19: a first perspective, *J. Eur. Acad. Dermatol. Venereol.* (March 26) (2020), doi:<http://dx.doi.org/10.1111/jdv.16387> [Epub ahead of print].
- [8] I.F. Manalo, M.K. Smith, J. Cheeley, R. Jacobs, A dermatologic manifestation of COVID-19: transient livedo reticularis, *J. Am. Acad. Dermatol.* (April 10) (2020), doi:<http://dx.doi.org/10.1016/j.jaad.2020.04.018> [Epub ahead of print].
- [9] Y. Zhang, W. Cao, M. Xiao, Clinical and coagulation characteristics of 7 patients with critical COVID-2019 pneumonia and acro-ischemia, *Zhonghua Xue Ye Xue Za Zhi* 41 (March(0)) (2020) E006, doi:<http://dx.doi.org/10.3760/cma.j.issn.0253-2727.2020.0006> [Epub ahead of print].
- [10] B. Joob, V. Wiwanitkit, COVID-19 can present with a rash and be mistaken for dengue, *J. Am. Acad. Dermatol.* 82 (May (5)) (2020) e177, doi:<http://dx.doi.org/10.1016/j.jaad.2020.03.036> [Epub 2020 Mar 22].
- [11] J. Jimenez-Cauhe, D. Ortega-Quijano, M. Prieto-Barrios, Om Moreno-Arrones, D. Fernandez-Nieto, Reply to "COVID-19 can present with a rash and be mistaken for Dengue": petechial rash in a patient with COVID-19 infection, *J. Am. Acad. Dermatol.* (April 10) (2020), doi:<http://dx.doi.org/10.1016/j.jaad.2020.04.016> pii: S0190-9622(20)30556-9. [Epub ahead of print].
- [12] M. Hunt, C. Koziatek, A case of COVID-19 pneumonia in a young male with full body rash as a presenting symptom, *Clin Pract Cases Emerg Med.* (March 28) (2020), doi:<http://dx.doi.org/10.5811/cpcem.2020.3.47349> [Epub ahead of print].
- [13] A. Mahé, E. Birckel, S. Krieger, C. Merklen, L. Bottlaender, A distinctive skin rash associated with Coronavirus Disease 2019? *J. Eur. Acad. Dermatol. Venereol.* (April 15) (2020), doi:<http://dx.doi.org/10.1111/jdv.16471> [Epub ahead of print].
- [14] D. Fernandez-Nieto, D. Ortega-Quijano, G. Segurado-Miravalles, C. Pindado-Ortega, M. Prieto-Barrios, J. Jimenez-Cauhe, Comment on: cutaneous manifestations in COVID-19: a first perspective. Safety concerns of clinical images and skin biopsies, *J. Eur. Acad. Dermatol. Venereol.* (April 15) (2020), doi:<http://dx.doi.org/10.1111/jdv.16470> [Epub ahead of print].
- [15] A. Estébanez, L. Pérez-Santiago, E. Silva, S. Guillen-Climent, A. García-Vázquez, M. Ramón, Cutaneous manifestations in COVID-19: a new contribution, *J. Eur. Acad. Dermatol. Venereol.* (April 15) (2020), doi:<http://dx.doi.org/10.1111/jdv.16474> [Epub ahead of print].
- [16] J. Zhang, X. Dong, Y. Cao, Y. Yuan, Y. Yang, Y. Yan, et al., Clinical characteristics of 140 patients infected with SARS-CoV-2 in Wuhan, China, *Allergy* (February 19) (2020), doi:<http://dx.doi.org/10.1111/all.14238> [Epub ahead of print].
- [17] D. Henry, M. Ackerman, E. Sancelme, A. Finon, E. Esteve, Urticarial eruption in COVID-19 infection, *J. Eur. Acad. Dermatol. Venereol.* (April 15) (2020), doi:<http://dx.doi.org/10.1111/jdv.16472> [Epub ahead of print].
- [18] M. Kamali Aghdam, N. Jafari, K. Eftekhari, Novel coronavirus in a 15-day-old neonate with clinical signs of sepsis, a case report, *Infect. Dis. (Lond)*. 52 (June (6)) (2020) 427–429, doi:<http://dx.doi.org/10.1080/23744235.2020.1747634> [Epub 2020 Apr 1].
- [19] F. Mazzotta, T. Troccoli, Acute Acro-Ischemia in the Child at the time of COVID-19, *Dermatologia Pediatrica, Bari*, (2020) In press.
- [20] A. Alramthan, W. Aldaraji, A case of COVID-19 presenting in clinical picture resembling chilblains disease. First report from the Middle East, *Clin Exp Dermatol.*, (2020) April 17. doi: <https://doi.org/10.1111/ced.14243>. [Epub ahead of print].
- [21] D.J. Najarian, Morbilliform exanthem associated with COVID-19, *JAAD Case Rep.* (2020), doi:<http://dx.doi.org/10.1016/j.jadcr.2020.04.015> April 19.
- [22] A. Kolivras, F. Dehavay, D. Delplace, F. Feoli, I. Meiers, L. Milone, et al., Coronavirus (COVID-19) infection- induced chilblains: a case report with histopathological findings, *JAAD Case Rep.* (April 18) (2020), doi:<http://dx.doi.org/10.1016/j.jadcr.2020.04.011>.
- [23] A.V. Marzano, G. Genovese, G. Fabbrocini, P. Pigatto, G. Monfrecola, B.M. Piraccini, et al., Varicella-like exanthem as a specific COVID-19-associated skin manifestation: multicenter case series of 22 patients, *J. Am. Acad. Dermatol.* (April 16) (2020), doi:<http://dx.doi.org/10.1016/j.jaad.2020.04.044> pii: S0190-9622(20)30657-5. [Epub ahead of print].
- [24] C.C. Lai, T.P. Shih, W.C. Ko, H.J. Tang, P.R. Hsueh, Severe acute respiratory syndrome coronavirus 2 (SARS-CoV-2) and corona virus disease-2019 (COVID-19): the epidemic and the challenges, *Int. J. Antimicrob. Agents* 55 (March (3)) (2020) 105924, doi:<http://dx.doi.org/10.1016/j.ijantimicag.2020.105924> [Epub 2020 Feb 17].
- [25] N. Chen, M. Zhou, X. Dong, J. Qu, F. Gong, Y. Han, et al., Epidemiological and clinical characteristics of 99 cases of 2019 novel coronavirus pneumonia in Wuhan, China: a descriptive study, *Lancet* 395 (February (10223)) (2020) 507–513, doi:[http://dx.doi.org/10.1016/S0140-6736\(20\)30211-7](http://dx.doi.org/10.1016/S0140-6736(20)30211-7) [Epub 2020 Jan 30].
- [26] C. Huang, Y. Wang, X. Li, L. Ren, J. Zhao, Y. Hu, et al., Clinical features of patients infected with 2019 novel coronavirus in Wuhan, China, *Lancet* 395 (February (10223)) (2020) 497–506, doi:[http://dx.doi.org/10.1016/S0140-6736\(20\)30183-5](http://dx.doi.org/10.1016/S0140-6736(20)30183-5) [Epub 2020 Jan 24].
- [27] A.W. Swarbrick, S.P. Kumarasinghe, Toxic shock syndrome: a dermatological emergency, *Australas. J. Dermatol.* 59 (May (2)) (2018) 154–155, doi:<http://dx.doi.org/10.1111/ajd.12730> [Epub 2017 Sep 27].
- [28] J. Tsai, M.A. Nagel, D. Gilden, Skin rash in meningitis and meningoencephalitis, *Neurology* 80 (May (19)) (2013) 1808–1811, doi:<http://dx.doi.org/10.1212/WNL.0b013e3182918cda>.
- [29] A. Randel, Guidelines for the diagnosis and treatment of tick-borne rickettsial diseases, *Am. Fam. Physician* 76 (July (1)) (2007) 137.
- [30] R. Battegay, C. Itin, P. Itin, Dermatological signs and symptoms of measles: a prospective case series and comparison with the literature, *Dermatology* 224 (1) (2012) 1–4, doi:<http://dx.doi.org/10.1159/000335091> [Epub 2012 Jan 10].
- [31] S. Basetti, J. Hodgson, T.M. Rawson, A. Majeed, Scarlet fever: a guide for general practitioners, *London J. Prim. Care* (Abingdon) 9 (August (5)) (2017) 77–79, doi:<http://dx.doi.org/10.1080/17571472.2017.1365677> eCollection 2017 Sep..
- [32] R. Gianotti, COVID 19 and the skin—heuristic review, *DermaSprint.* (2020) April 06. In press.
- [33] C. Magro, J. Mulvey, D. Berlin, G. Nuovo, S. Salvatore, J. Harp, A. Baxter-Stoltzfus, J. Laurence, Complementary associated microvascular injury and thrombosis in the pathogenesis of severe COVID-19 infection: a report of five cases, *Transl. Res.* (2020) In press.



Muskaan Sachdeva is a medical student at Faculty of Medicine, University of Toronto, and is also a graduate of the Bachelor of Health Sciences program at McMaster University. In addition to her medical degree, she is completing her graduate studies in healthcare research. She is an avid supporter of understanding visible skin conditions and cutaneous manifestations of systemic diseases. Her strong interests in dermatology has led her to explore this field through numerous research contributions and community initiatives.



Prof. Raffaele Gianotti:
Graduated in Medicine Milan University 1986
Specialization in Dermatology and Venereology in 1989
Specialization in Surgical Pathologist in 1993
One year as a resident Fellow at NYU in Bernie Ackerman Dermatopathological Lab.
More than 100 publications in Dermatology and Dermatopathology.
Creator of Lampyris 101 dermatopathological software system for computerized diagnosis of Inflammatory skin diseases in collaboration with Dr. Heinz Kutzner, Friedrichshafen Dermatopathology Lab. Germany
Actually Chairman of Dermatopathology Lab. Of the Clinica Dermatologica – University of Milan Italy