

consequently, leading to a good outcome. He also had a respiratory implication of SARS-CoV2 but not as severely described as in the adult ARDS.

The high clinical suspicion of myocarditis in our patient based on clinical course and elevated myocyte cytolysis markers was confirmed by the functional and structural CMR findings, combining main and supportive criteria according to the current guidelines⁸ and the revised Lake-Louise recommendations.⁹ Myocarditis due to viral infection has been widely described and associated to myocardial inflammation leading to necrosis and heart dysfunction. Other coronaviruses (Middle East Respiratory Syndrome Coronavirus) have already been identified as causative agents of myocarditis in adults.⁵ In the case of COVID-19, the physiopathologic process remains unclear, although both direct cardiac injury by SARS-CoV2 (eg, through ACE2 binding in the heart) and indirect damage through a toxic inflammatory reaction with cytokine storm seem plausible. Several adult autopsy reports revealed that there is a significant number of inflammatory cells in the alveoli of patients suffering from ARDS caused by SARS-CoV2.¹⁰ Nevertheless, no histologic changes were seen in heart tissue and no viral inclusions were identified in the lungs, suggesting indirect damage through the cytokine storm. Furthermore, high rates of inflammatory markers such as IL-6, Ferritin or CRP can be found in the blood of critical patients. Our patient with myocarditis responded to immunomodulatory treatment, with a complete reversal of myocardial edema, raising the hypothesis that SARS-CoV2 triggers an exaggerated inflammatory response causing heart damage. Further argument to highlight the physiopathologic process as a para-infectious inflammatory response to SARS-CoV2 in our patient is that viral load was low (high CT), suggesting that he was at the end of the infection but in the middle of the cytokine storm.

A hypothesis to explain the death of children occurring during COVID-19 could be that some predisposed children might be more susceptible to cardiac damages from the cytokine storm triggered by COVID-19 rather than the usual respiratory distress syndrome typically observed in adults. Deep analysis of pediatric life-threatening infections is necessary to better understand children's specific risk factors.

CONCLUSION

During this time of pandemic, where telemedicine is becoming a common practice, it is essential that whenever any sign of potential gravity is present at a child's evaluation, urgent clinical care is provided to identify potential life-threatening COVID-19 such as myocarditis.

Therefore, clinicians should be aware of the cardiac involvement of SARS-CoV2 in children and search for any signs of myocarditis when taking care of unwell children with proven or suspected COVID-19 as prompt diagnosis can be lifesaving.

We also raise concerns that cardiac injury could be due to the disproportionate host immune response to SARS-CoV2 rather than through direct damage by the virus itself.

ACKNOWLEDGMENTS

We thank the patient and his family for granting permission to publish this article.

REFERENCES

1. Inciardi RM, Lupi L, Zacccone G, et al. Cardiac involvement in a patient with coronavirus disease 2019 (COVID-19). *JAMA Cardiol.* 2020.
2. Ministerio de Sanidad. Documento de manejo clínico del paciente pediátrico con infección por SARS-CoV-2. 2020.

3. Recommendations by the high council of infectious diseases about COVID-19 in Luxembourg. 2020. Available at: <https://sante.public.lu/fr/espace-professionnel/recommandations/conseil-maladies-infectieuses/covid-19/covid-19-annexes/covid19-strategie-therapeutique.pdf>. Accessed April 14, 2020.
4. Guan W, Ni Z, Hu Y, et al. China medical treatment expert group for Covid-19. clinical characteristics of coronavirus disease 2019 in China. *N Engl J Med.* 2020;382:1708-1720.
5. Zheng YY, Ma YT, Zhang JY, et al. COVID-19 and the cardiovascular system. *Nat Rev Cardiol.* 2020;17:259-260.
6. Lu X, Zhang L, Du H, et al. SARS-CoV-2 infection in children. *N Engl J Med.* 2020;382:1663-1665.
7. CDC Covid-19 Response Team. Coronavirus disease 2019 in children—United States, February 12–April 2. *CDC Morbidity and Mortality Weekly Report.* 2020.
8. Caforio AL, Pankuweit S, Arbustini E, et al; European Society of Cardiology Working Group on Myocardial and Pericardial Diseases. Current state of knowledge on aetiology, diagnosis, management, and therapy of myocarditis: a position statement of the European Society of Cardiology Working Group on Myocardial and Pericardial Diseases. *Eur Heart J.* 2013;34:2636-2648, 2648a.
9. Ferreira VM, Schulz-Menger J, Holmvang G, et al. Cardiovascular magnetic resonance in nonischemic myocardial inflammation: expert recommendations. *J Am Coll Cardiol.* 2018;72:3158-3176.
10. Xu Z, Shi L, Wang Y, et al. Pathological findings of COVID-19 associated with acute respiratory distress syndrome. *Lancet Respir Med.* 2020;8:420-422.

ACUTE INFLAMMATION AND ELEVATED CARDIAC MARKERS IN A TWO-MONTH-OLD INFANT WITH SEVERE ACUTE RESPIRATORY SYNDROME CORONAVIRUS 2 INFECTION PRESENTING WITH CARDIAC SYMPTOMS

Vania Giacomel, MD,* Valeria Anna Manfredini, MD,* Giulia Meraviglia, MD,* Caterina Francesca Peri, MD,* Anna Sala, MD,* Emma Longoni, MD,* Alessio Gasperetti, MD,† Marta Stracuzzi, MD,* Savina Mannarino, MD,‡ and Gian Vincenzo Zuccotti, MD§

Abstract: Severe acute respiratory syndrome coronavirus 2 infection in children mainly shows a milder course. In complicated cases, it is unknown whether inflammation is predictive of disease severity, as in adults. Moreover, cardiac involvement is anecdotally described. We report the case of a 2-month-old infant with severe acute respiratory syndrome coronavirus 2 infection presenting with fever, tachycardia and elevated interleukin-6, who was diagnosed with myocarditis and treated with immunoglobulins.

Key Words: coronavirus disease 2019, infant, myocarditis, interleukin-6, infection

Accepted for publication April 29, 2020.

From the *Department of Pediatrics, Luigi Sacco Hospital, ASST-Fatebenefratelli-Sacco, University of Milan, Milan, Italy; †Department of Cardiology, University Heart Center, University Hospital Zurich, Zurich, Switzerland; ‡Department of Pediatric Cardiology, V. Buzzi Children's Hospital, Milan, Italy; and §Department of Pediatrics, ASST-FBF-Sacco, Vittore Buzzi Children's Hospital, University of Milan, Milan, Italy.

The authors have no funding or conflicts of interest to disclose.

Address for correspondence: Valeria Anna Manfredini, MD, Department of Pediatrics, Luigi Sacco Hospital, ASST-Fatebenefratelli-Sacco, University of Milan, Via G.B. Grassi 74, 20157 Milan, Italy. E-mail: manfredini.valeria@asst-fbf-sacco.it.

Copyright © 2020 Wolters Kluwer Health, Inc. All rights reserved.

DOI: 10.1097/INF.0000000000002750

Severe acute respiratory syndrome coronavirus 2 (SARS-CoV-2) infection has become a public health emergency worldwide. In adults, the disease varies in its clinical presentation from a flu-like syndrome with fever, cough, myalgia and/or fatigue to respiratory failure as the major leading cause of death. Despite respiratory symptoms are dominant in complex cases, cardiac involvement has been lately described as a clinical complication. In adults with

A

Mesasure	Reference range	Result				
		Day 1	Day 2	Day 3	Day 5	Day 7
White cell count (x10 ⁹ /L)	5-17.5	9.42	10.25	-	7.41	-
Neutrophile count						
Relative (%)	41.1-72.5	74.4	48.1	-	23.3	-
Absolute (x10 ⁹ /L)	1.91-6.23	7.01	4.93	-	1.72	-
Lymphocyte count						
Relative (%)	19.6-46.5	15.2	40	-	67.2	-
Absolute (x10 ⁹ /L)	1.13-3.37	1.43	4.1	-	4.98	-
Platelet count (x10 ⁹ /L)	169-359	446	349	-	372	-
Haemoglobin (g/dL)	9-14	9.4	7.9	-	11.6	-
C-reactive Protein (mg/L)	<10	8.9	35	-	3.9	-
Procalcitonin (µg/mL)	<0.5	1.3	2	-	<0.1	-
Interleukin-6 (ng/L)	<7	236	-	-	25	-
D-dimer (µg/L)	<500	-	1918	-	-	1692
Fibrinogen (g/L)	1.7-4	-	3.28	-	-	5.24
INR	0.84-1.16	-	-	-	1.01	1
Troponin-T (ng/L)	<15	103	150	39	48	42
NT-ProBNP (ng/L)	<450	12507	-	2101	3353	279

B

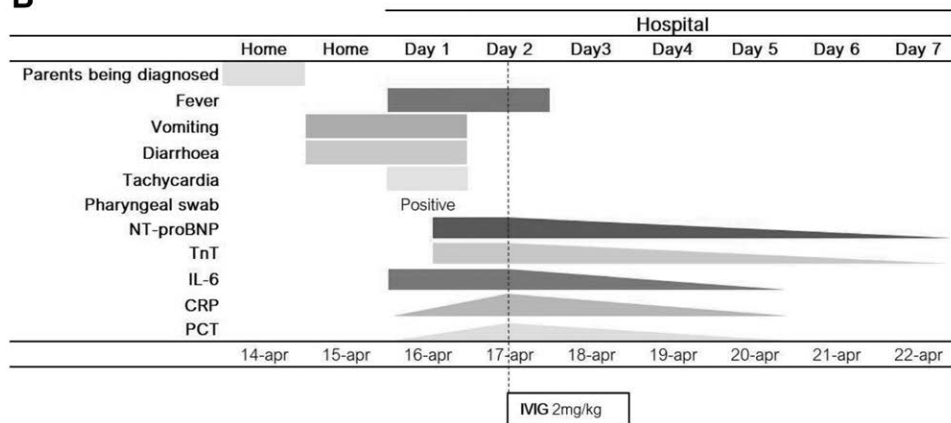


FIGURE 1. Disease course of the infected infant: timetable of laboratory tests (A) and clinical events (B). CRP indicates C-reactive protein; INR, international normalized ratio; NT-pro-BNP, N-terminal pro-brain natriuretic peptide; TnT, troponin T.

severe illness, elevated inflammatory cytokines seem to play a major role and have been proposed as a predictor of disease severity.¹

In infants and children, SARS-CoV-2 infection mainly shows a milder course, with only few cases of acute respiratory disease reported. Moreover, cardiac injury related to SARS-CoV-2 has only been described in a 55-day-old infant, and no correlation with inflammation markers has been proven.² Here, we report the case of a 2-month-old child affected by SARS-CoV-2 presenting with fever, tachycardia and elevated interleukin-6 (IL-6), who was diagnosed with suspected myocarditis.

CASE REPORT

A 2-month-old child was admitted to our hospital because of a 2-day history of fever (38°C), nonbloody diarrhea and 2 episodes of vomiting.

Because a recent close contact with confirmed cases of coronavirus disease 2019 (COVID-19; her father and her older brother) was reported, a nasopharyngeal swab was performed and analyzed using real-time reverse transcriptase polymerase chain reaction assay, resulting positive for SARS-CoV-2.

At the time of admission, the baby was presenting with whiny crying, intermittent tachycardia (heart rate between 170 and 230 bpm) and mottled skin. The temperature was 37.4°C, the respiratory rate was

40 breaths per minute and the oxygen saturation was 96% breathing room air. The blood pressure was 88/50 mm Hg. Physical examination was otherwise normal, with no signs of respiratory or neurologic impairment. Arterial blood gas analysis parameters were within normal limits. Chest radiography was unremarkable. Two 12-lead electrocardiograms, 3 hours apart, confirmed sinus tachycardia, without other clear pathologic alterations. Transthoracic echocardiography revealed no pathologic signs. Blood tests showed normal C-reactive protein, procalcitonin (PCT), blood cell count and a slightly decreased hemoglobin concentration. However, a routine cardiac panel revealed an increase in plasma levels of troponin T (103 ng/L) and N-terminal pro-brain natriuretic peptide (12,507 ng/L), alongside with elevated concentrations of IL-6 (236 ng/L). As a precautionary measure, empiric treatment with intravenous cefotaxime plus ampicillin was started and the infant was transferred to the pediatric intensive care unit with the diagnostic suspect of myocarditis.

At admission to the pediatric intensive care unit department, on day 2 after arrival, blood tests showed increased C-reactive protein, PCT and D-dimer with a further decrease in the hemoglobin concentration. International normalized ratio and platelets count were within normal limits. At a second evaluation, transthoracic echocardiography revealed hypokinesia of the inferior left ventricular wall and the inferior interventricular septum, with a mild decrease in the left ventricular ejection fraction (57–58% in

parasternal short-axis view, 52.7% in biplane Simpson's method). No inotropic support was required at the time. However, packed red blood cells were transfused, and empiric treatment with intravenous immunoglobulins (IVIGs) was started (2 g/kg in 24 hours). Between days 3 and 6, a decrease of cardiac and inflammatory markers was evident. On day 4, transthoracic echocardiography showed ejection fraction recovery with normal left ventricular dimensions, while mild dyskinesia of the inferior left ventricular wall and the inferior interventricular septum persisted. No specific signs of abnormal repolarization emerged from the electrocardiographic traces. On day 5, heart rate was recorded stable and in the normal range (140–150 bpm). The last determination of N-terminal pro-brain natriuretic peptide was 279 ng/L and D-dimer 1692 µg/L. Pre- and posttreatment laboratory values and clinical events are presented in Figure 1.

To further investigate gastrointestinal symptoms, a test for the detection of adenovirus and rotavirus antigens on a stool sample was performed resulting negative. Search for other possible cardiotropic viral agents (including coxsackievirus, Epstein-Barr virus, mumps virus, parvovirus B19, adenovirus, varicella zoster virus, measles morbillivirus) plus *Legionella pneumophila* and *Mycoplasma pneumoniae* IgM resulted negative. Antibiotic treatment was discontinued on day 5, after blood cultures proved negative.

DISCUSSION

Exuberant host immune response has been proposed as a driving mechanism for tissue damage in adults with SARS-CoV-2 infection, regardless of the viral load. Cytokines levels, IL-6 in particular, seem to play a crucial role and may be considered as biomarkers for risk stratification and prognosis. On this background, treatment strategies have been focusing on immune-modulation using monoclonal anti-IL-6 receptor antibody (Tocilizumab) or corticosteroids.¹

In children, milder course of the COVID-19 disease has been explained with the so-called trained immunity, an enhanced state of activation of the immune system, induced by frequent viral infection and vaccines, and resulting in a more effective defense against different pathogens. In infants, however, relatively low levels of the trained immunity have been proposed to explain more severe clinical presentation.³

Besides pulmonary damage, the most recent literature related to COVID-19 has reported an increased risk of cardiac complications including heart failure, myocardial infarction and arrhythmias in SARS-CoV-2-positive adults.⁴ In pediatric patients with paucisymptomatic SARS-CoV-2 infection, no cases of major heart injury have been reported yet, while increased cardiac biomarkers have been described in a 55-day-old female infant with severe pulmonary involvement caused by SARS-CoV-2.²

No single clear mechanism responsible for cardiovascular complications in COVID-19 has been identified yet, but several possible options have been postulated, including direct acute direct myocardial injury (acute viral myocarditis), thrombotic events (type 1 myocardial infarction), microangiopathy and tachycardia (type 2 myocardial infarction). The enhanced systemic inflammation response seems to be tightly related to all these mechanisms.⁵

Of note, in our patient, IL-6 peak reached values 33 times the upper limit of normal, preceding the rise of polymerase chain reaction, PCT, D-dimer and the reduction of hemoglobin concentration. IL-6 elevation was otherwise concurrent with cardiac marker elevation, preceding echocardiographic signs. Remarkably, NT-pro-BNP reached values as high as those reported in children suffering from acute heart failure or fulminant myocarditis.⁶

Among treatment options, we discarded corticosteroids because of the lack of univocal guidelines proving their effectiveness

and because of concern related to their short- and long-term adverse effects in the context of SARS-CoV-2-infected patients.

IVIGs are commonly used to treat inflammatory diseases involving the heart in virtue of their immune-modulating activity, and their potential benefit in myocarditis treatment has been postulated. The choice to treat our patient using IVIG took into consideration their downregulatory effect on antibody and cytokine synthesis and inhibition of the leukocytes binding to the vascular endothelium. Indeed, our patient showed a good response to the treatment with IVIG.⁷

In our case, the suspicion of myocarditis was based on clinical presentation, echocardiographic findings, typical localization and cardiac markers elevation.

Although the most specific diagnostic tools (cardiovascular magnetic resonance and endomyocardial biopsy) could not be employed due to the urgency and the young age of the patient, a clinical diagnosis was fulfilled anyway.⁸

Despite this, our report emphasizes the role of inflammation as a trigger for damage involving organs other than the lungs. Even in the absence of respiratory symptoms, the elevation of IL-6 is a possible early warning sign appearing to be of relevance also in youngest individuals with SARS-CoV-2 infection.

REFERENCES

- Liu B, Li M, Zhou Z, et al. Can we use interleukin-6 (IL-6) blockade for coronavirus disease 2019 (COVID-19)-induced cytokine release syndrome (CRS)? *J Autoimmun*. 2020;102452 Epub ahead of print.
- Cui Y, Tian M, Huang D, et al. A 55-day-old female infant infected with 2019 novel coronavirus disease: presenting with pneumonia, liver injury, and heart damage. *J Infect Dis*. 2020;jiaa113 Epub ahead of print.
- Cristiani L, Mancino E, Matera L, et al. Will children reveal their secret? The coronavirus dilemma. *Eur Respir J*. 2020;55:2000749.
- Bansal M. Cardiovascular disease and COVID-19. *Diabetes Metab Syndr*. 2020;14:247–250.
- Hendren NS, Drazner MH, Bozkurt B, et al. Description and proposed management of the acute COVID-19 cardiovascular syndrome. *Circulation*. 2020 Epub ahead of print.
- Lv J, Han B, Wang C, et al. The clinical features of children with acute fulminant myocarditis and the diagnostic and follow-up value of cardiovascular magnetic resonance. *Front Pediatr*. 2019;7:388.
- Galeotti C, Kaveri SV, Bayry J. IVIG-mediated effector functions in autoimmune and inflammatory diseases. *Int Immunol*. 2017;29:491–498.
- Caforio AL, Pankuweit S, Arbustini E, et al; European Society of Cardiology Working Group on Myocardial and Pericardial Diseases. Current state of knowledge on aetiology, diagnosis, management, and therapy of myocarditis: a position statement of the European society of cardiology working group on myocardial and pericardial diseases. *Eur Heart J*. 2013;34:2636–2648, 2648a.

HAND CELLULITIS AND ABSCESS FROM A KINKAJOU BITE

A Case Report and Review of Kinkajou Bites in Humans

Teena Hadvani, MD*† and Ankhi Dutta, MD, MPH†‡

Abstract: Medical literature on the microbiology of kinkajou bites is scarce. We present a patient presenting with hand cellulitis and abscess after a kinkajou bite that grew *Aggregatibacter actinomycetemcomitans* and *Fusobacterium nucleatum*. We review the literature regarding microbiology and management of kinkajou bites.

Key Words: kinkajou bite, animal bite, cellulitis, microbiology

Accepted for publication October 2, 2019.

From the *Sections of Pediatric Hospital Medicine, †Department of Pediatrics, and ‡Infectious Diseases, Texas Children's Hospital and Baylor College of Medicine, Houston, Texas.