
Videocapillaroscopy in Connective Tissue Diseases

Simone Parisi and Maria Chiara Ditto

Additional information is available at the end of the chapter

<http://dx.doi.org/10.5772/intechopen.69520>

Abstract

Videocapillaroscopy is a noninvasive, quick, and easy examination method to indicate if there is clinical suspicion of microangiopathy. It provides the rheumatologist indispensable information on the microcirculation state. Recently with the development of the new classification criteria of systemic sclerosis (ACR 2013), capillaroscopy has become even more important. It is currently the only instrumental test whose result is pathognomonic for diagnosis of systemic sclerosis. During videocapillaroscopy, the following parameters are evaluated: density, structure, hemosiderin deposition, bloodstream, presence of megacapillaries, presence of subpapillary venous plexus, and edema. It can distinguish several patterns, especially scleroderma pattern, as follows: (1) "Early" pattern: few enlarged/giant capillaries, few capillary hemorrhages, relatively well-preserved capillary distribution, no evident loss of capillaries; (2) "Active" pattern: frequent giant capillaries, frequent capillary hemorrhages, moderate loss of capillaries, mild disorganization of the capillary architecture, absent or mild ramified capillaries; (3) "Late" pattern: irregular enlargement of the capillaries, few or absent giant capillaries and hemorrhages, severe loss of capillaries with extensive avascular areas, disorganization of the normal capillary array, ramified/bushy capillaries. Although capillaroscopic examination is easy to perform, it is essential that the operator has been properly trained on the instrument's function and on correct method of image acquisition to avoid misinterpretation.

Keywords: nailfold capillaroscopy, Raynaud's phenomenon, scleroderma pattern, prognostic score

1. Introduction

Capillaroscopy is a noninvasive, fast, and easy imaging technique to evaluate the assessment of the microcirculation. It is indicated in patients with suspect of microangiopathy [1].

It gives precise information about capillaries' conditions and related diseases to rheumatologist.

Recently, after the development of new systemic sclerosis classifications criteria [2], the role of capillaroscopy became more important. In fact a score of two out of nine is assigned in the case of significant capillaroscopic abnormalities to diagnose this disease (**Table 1**).

In the past, the study of capillaries was performed by instruments that could zoom, take pictures, or film the blood microcirculation, such as the ophthalmoscope and the dermatoscope, the stereo microscope, and tools for macrophotography.

The modern capillaroscopy, equipped with optical probes, is today commonly used in rheumatological and dermatological practice, and it is able to zoom (magnificat) capillaries in order of 200×, obtaining much qualitative measurements that could be reproducible.

The instrument consists of an optical probe fitted with an adjustable magnification and illumination ring for focusing and a personal computer (with high resolution color screen) with software for data processing. Several new models interface with iOS or Android system, and they are more portable (**Figure 1**).

Although capillaroscopic examination is easy to perform, it is essential that the operator has been properly trained about the instrument's functioning and correct method of image acquisition to avoid misinterpretation [3].

2013 ACR / EULAR Criteria For The Classification Of Systemic Sclerosis (Scleroderma)*		
Item	Sub-items(s)	Weight/score †
Skin thickening of the fingers of both hands extending proximal to the metacarpophalangeal joints (<i>sufficient criterion</i>)	-	9
Skin thickening of the fingers (<i>only count the higher score</i>)	Puffy fingers	2
	Sclerodactyly of the fingers (distal to the metacarpophalangeal joints but proximal to the proximal interphalangeal joints)	4
Fingertip lesions (<i>only count the higher score</i>)	Digital tip ulcers	2
	Fingertip pitting scars	3
Telangiectasia	-	2
Abnormal nailfold capillaries	-	2
Pulmonary arterial hypertension and/or interstitial lung disease (<i>maximum score is 2</i>)	Pulmonary arterial hypertension	2
	Interstitial lung disease	2
Raynaud's phenomenon	-	3
SSc-related autoantibodies (anticentromere, anti-topoisomerase I [anti-Scl-70], anti-RNA polymerase III) (<i>maximum score is 3</i>)	Anticentromere 3	3
	Anti-topoisomerase I	
	Anti-RNA polymerase III	

* The criteria are not applicable to patients with skin thickening sparing the fingers or to patients who have a scleroderma-like disorder that better explains their manifestations (e.g., nephrogenic sclerosing fibrosis, generalized morphea, eosinophilic fasciitis, scleroderma diabeticorum, scleromyxedema, erythromyalgia, porphyria, lichen sclerosis, graft-versus-host disease, diabetic cheiroarthropathy).

† The total score is determined by adding the maximum weight (score) in each category.
Patients with a total score of ≥ 9 are classified as having definite scleroderma.

Sensitivity 91% Specificity 92%

Van den Hoogen et al. 2013 Classification Criteria for Systemic Sclerosis. *Arthritis and Rheumatism*. Vol. 65, No. 11, November 2013, pp 2737–2747

Table 1. Systemic sclerosis classification criteria 2013.

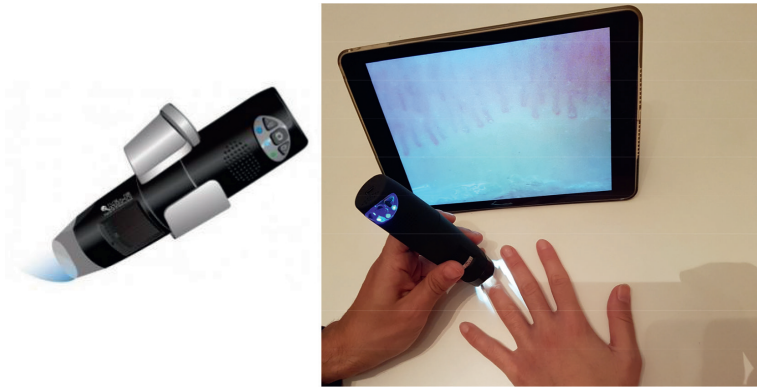

Figure 1. Example of Wi-fi capillaroscope.

2. The capillaroscopic technique

Capillaroscopy should be always performed in conditions of constant temperature. By convention, it is considered that the patient needs an acclimatization of at least 15 min at the temperature of 21–24°C before performing the examination.

When booking the videocapillaroscopy, it is necessary to give to the patient a few suggestions, especially to avoid the manicure in 7–10 days prior to the examination and application of nail polish.

At the time of the examination, the patient should be sat with his hands gently resting on the table on the palm with the fingers slightly apart.

Before starting the exam, it is necessary to apply a drop of oil (usually cedar oil) on the nail fold of each district that should be examined. At this level, the capillaries shall run parallel to the skin plane and, therefore, in normal subjects, are visible an afferent branch, a loop and an efferent branch (capillary hairpin).

Usually, they are investigated four districts in each hand leaving the first finger that usually has a bad view of the vascular widespread and nonspecific alterations. Furthermore, several studies have shown that, even in the presence of Raynaud phenomenon exclusively localized at the foot, capillaroscopy of the hands provides the same information that would be obtained by investigating the lower limbs and, therefore, for convenience, the examination, even in these cases, is usually performed exclusively in the hand level.

Modern software let you select on the monitor the investigation from time to time in the district, so you can compare any changes in respect of each finger. Also, they include measuring systems for dimensional analysis [4].

Although there are some parameters to indicate a normal/healthy capillaroscopic, it is important to consider that there is great variability in the capillary structure both interindividual and intraindividual. This variability depends on many factors such as employment, racial, and environmental.

In particular, in patients underwent to repeated microtrauma for professional reasons, such as typists, jackhammer users, pianists, etc., it is not uncommon to observe widespread phenomena of microhemorrhages and neoangiogenesis. As well as, patients who smoke have often shortened and tortuous capillaries. Moreover, in patients with dark or very dark skin color (e.g., for racial factors), it is often difficult to correctly visualize the capillaries and almost impossible to see the subpapillary venous plexus. Modern capillaroscopies with editable light intensity solve this problem in part. It is also important that the capillaroscopic be set from time to time for each patient calibrating on the “contrast”, “range,” and “saturation” functions to obtain an image that is as clear as possible [5].

3. The capillaroscopic parameters in normal/healthy conditions

A good capillaroscopic examination is achieved by positioning the probe plumb to the district under consideration and to obtain the correct visualize of the dermal papilla roughly between the middle and the upper third of the monitor (photo 2—correct assessment of the image). The area of interest is in fact just the dermal papilla and the capillaries residing there, or should reside within it, although the outside alterations are also important [6–8].

During capillaroscopy, the following parameters are evaluated:

- Density
- Structure
- Microhemorrhages
- Bloodstream
- Edema (soft focus effect)
- Subpapillary venous plexus

Density: In a healthy subject, the number of capillaries per millimeter is equal to 11 ± 2 while the number of capillaries for dermal papilla is equal to 2 ± 1 (picture 3: number of capillaries normal, equal to 12 per mm). The conditions under which this number is reduced may be described simply as “density reduction capillary” up to extreme situations of complete absence capillary describable as “areas avascular” or, in the case of a specific papilla, “vacuous papilla” (**Figure 2:** normal density; **Figure 3:** (a) and (b) area avascular papillary or “papillae vacuous.”)

Structure: The capillaries of the healthy subject, in most cases, have an aspect so-called “hair-pin shape” or “U-shaped” and are well aligned, in an orderly manner, the one beside the other with a “comb arrangement” (**Figure 4:** distribution capillary ordered to comb with

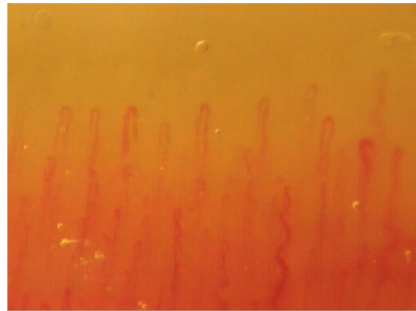


Figure 2. Example of normal pattern.

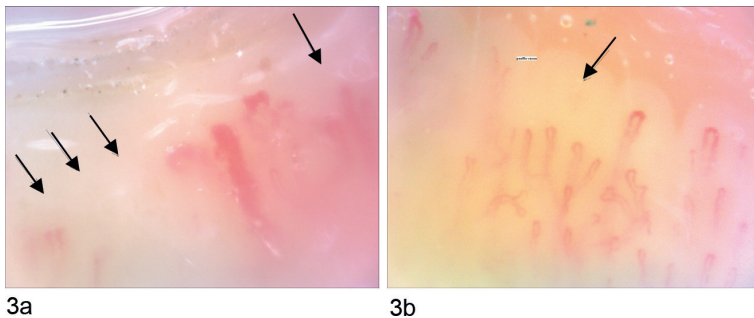


Figure 3. (a) and (b) Black arrows indicate papillae vacuous.

aspect hairpin), all similar in form and with some dimensional variability (length approximately between 200 and 500 μm).

You can observe the modest structural disorganization even in healthy individuals. Instead, the complete subversion of it is attributable to pathological conditions.

They should not be present ramifications that often indicate a poor vascularization with angiogenesis to provide the blood supply of avascular areas.

Tortuosities are often found, for the most in apical zone, and the capillary has a distorted aspect. It manifested as single or multiple cross/overs and/or patterns described as “trefoil,” “antler,” “glomerular loop,” and “treble clef.” These anomalies can be isolated or diffuse (Figure 5: tortuosities).

The apical tortuosities, by themselves, are not a pathologic finding. They are frequently found in heavy smokers, in patients underwent to repeated microtrauma, in patients with psoriasis and in various other conditions.

Otherwise, the tortuosity can be contextualized within a framework frankly altered or a real scleroderma pattern.

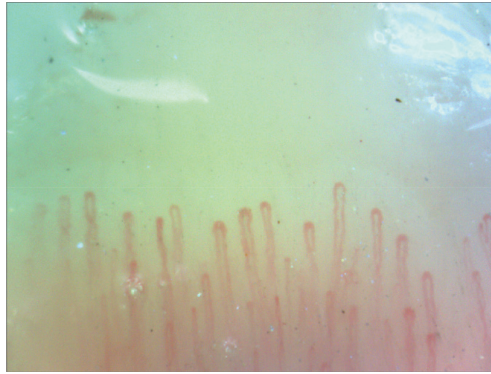


Figure 4. Normal structure: hairpin shape.

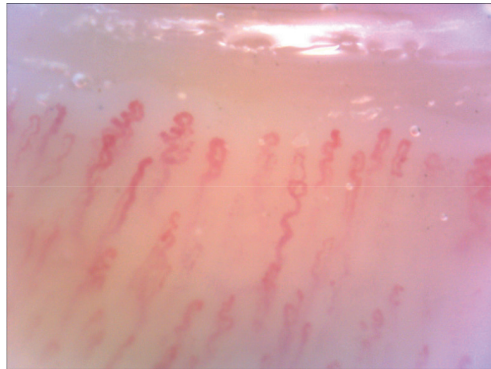


Figure 5. Tortuosity in apical zone.

The capillary branches (afferent and efferent loop) of the healthy subject normally have a diameter between 8 and 20 μm depending on the capillary portion considered. In fact, usually, the loop efferent, due to venous stasis, is slightly larger than that afferent.

They are defined “enlarged” capillaries with a diameter between 30 and 50 μm measured at the level of the two branches and the loop, “mega” capillaries with diameter $>50 \mu\text{m}$ at the level of the two branches and the loop, and “giant” capillaries with diameters $>100 \mu\text{m}$ wide and the two branches of the loop (Figure 6: megacapillaries and giant capillaries).

Morphostructural minor anomalies (e.g., tortuosity) are found in approximately 10–20% of healthy subjects.

Among irregularly enlarged capillaries, loop size can vary considerably in different segments, with normal portions alternating with extremely enlarged areas, sometimes giving a “microaneurysmatic” or “rosary-like” appearance (Figure 7).

Microhemorrhages: Although the microhemorrhages are frequent elements in the pathological or scleroderma pattern, it is not uncommon to observe them in healthy individuals as a

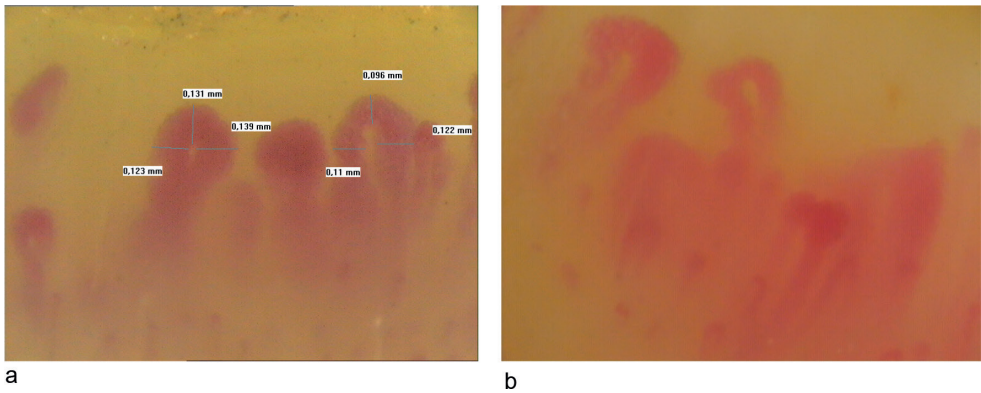


Figure 6. (a) and (b) Megacapillaries and giant capillaries.

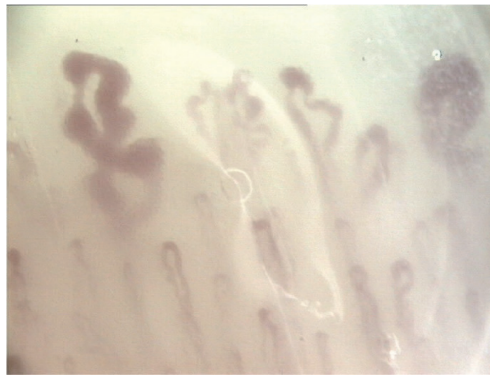


Figure 7. Capillaries with "rosary-like" aspect.

result of trauma. In these cases, bleeding is well-defined, unique, and usually transient, not necessarily directly related to the underlying capillaries. It is also not uncommon to observe very distant from the papilla or much below it.

The extravasation blood of pathological capillaries assumes a characteristic aspect in the supply chain "a strung pearls" (**Figure 8a and b**: microhemorrhages to "strung pearls"), or mold on the capillary (**Figure 8c and d**: "Napoleonic hat").

It can get an idea more or less realistic age of bleeding based on the analysis of the same color that tends to move from dark red to light yellow before disappearing altogether.

In the case of disease patterns may be encountered persistent deposits hemosiderin standing.

Nailfold microbleeds may also be related to capillary thrombosis which can occur in some pathological conditions and is often misinterpreted as hemorrhages. A key distinguishing feature of capillary thrombosis is the configuration of the dark area, which mirrors that of the capillary loops.

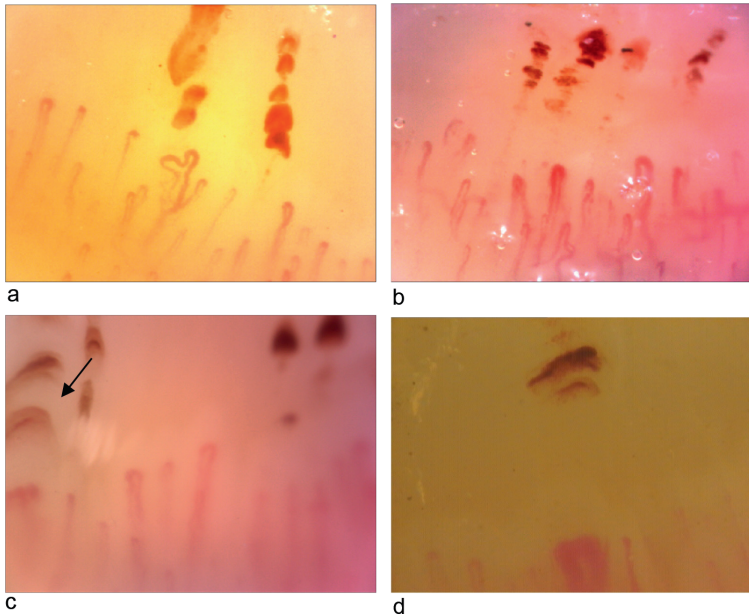


Figure 8. (a) and (b) Microhemorrhages to “strung pearls”; (c) and (d) microhemorrhages to “Napoleonic hat.”

Bloodstream: The capillaroscopy is a dynamic examination and allows to study blood flow, although in an approximate manner when compared to the Doppler technique.

A capillary with continuous blood flow is normal index. It will appear constantly full, and in the case when pressure is exerted by the probe on the same papilla, these will quickly fill the cessation of the stimulus. In the case of slowed blood flow, this will assume a granular appearance in particular in correspondence of the capillary walls and, in the case a pressure is exerted with the capillaroscopic probe the capillary will fill up slowly to cease the stimulus.

In the case where there is capillary thrombosis, typical of giant capillaries or megacapillari, the flow will appear static, and neither the pressure exerted by the probe nor the subsequent stop of the stimulus will show variations in the capillary which will appear always full.

Edema (soft focus effect): The flou effect in photography is a special effect that is achieved by reducing the contrast of the image without really being blurred. In capillaroscopy, it is talking about flou effect when, at the subpapillary, capillaries appear poorly visible in an edematous context of vascular congestion.

Occasionally, it is seen in healthy subjects. Alone it does not constitute a significant fault (**Figure 9:** flou effect).

Subpapillary venous plexus: The plexus is visible in the case of good skin transparency and is best viewed in the extreme ages of life (**Figure 10(a)** and **(b)**).

The venous plexus vessels have a perpendicular progress to the capillaries and are larger.




Figure 9. Black arrow → indicates flou effect.

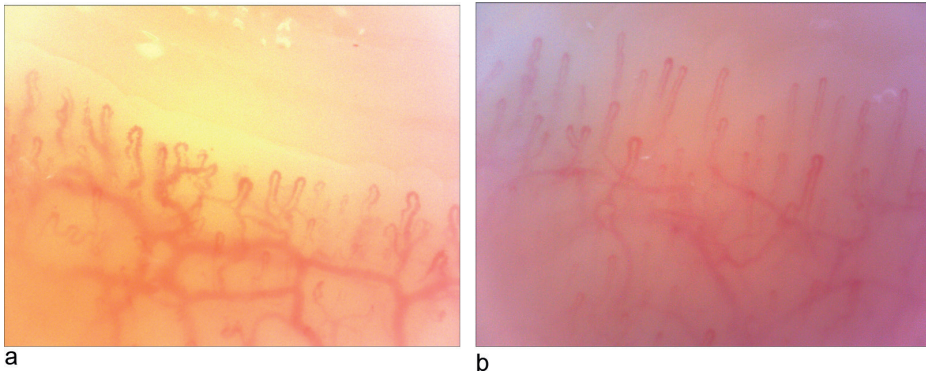


Figure 10. (a) and (b) Good visibility of the subpapillary venous plexus.

In cases of serious and widespread destruction capillaries, such as in the advanced stages of systemic sclerosis, the subpapillary venous plexus may constitute the only identifiable vascular element.

In healthy individuals, it is not always detectable.

4. Capillaroscopy in pathologic subjects

4.1. Introduction

Secondary Raynaud's phenomenon refers to the clinical manifestation in the presence of an underlying systemic disease.

Among the diseases of rheumatologic interest, the more strongly and inseparably linked to Raynaud's phenomenon is the systemic sclerosis, even if this appears also in the presence of other autoimmune diseases such as systemic lupus erythematosus, dermatomyositis, undifferentiated connective, and mixed connective, in a small percentage of cases, in the presence of rheumatoid, psoriatic, or juvenile idiopathic arthritis.

Capillaroscopy does not constitute, in itself, a diagnostic test. Especially not useful to diagnostic Raynaud's phenomenon, whose diagnosis is exclusively linked to the clinic. The examination provides a specific view on the state of the microcirculation and in particular on its integrity and is always related to the clinical and laboratory data. Then we can determine whether the Raynaud's phenomenon is referable to a damage of the microcirculation [8, 9].

However, capillaroscopy plays a key role in the diagnosis of connective tissue diseases and especially of the scleroderma spectrum disorders, which include, in addition to systemic sclerosis, the dermatomyositis, the undifferentiated, and mixed connective tissue disease [10, 11].

In fact, historically, the typical capillaroscopic alterations for scleroderma spectrum disorders have always played a fundamental role in the diagnosis of systemic sclerosis, being included in all the diagnostic criteria formulated over the years for this condition, including the latest ACR criteria of 2013.

In contrast to what happens in the case of primitive Raynaud's phenomenon, in the presence of secondary Raynaud's phenomenon, the capillaroscopy is able to reveal specific anomalies.

Over the years, we have been implemented many efforts in an attempt to identify specific capillaroscopic paintings for a specific pathology. These efforts have hesitated in identifying a capillaroscopic pattern defined as "scleroderma pattern." More than 95% of patients with overt systemic sclerosis have morphological markers of microvascular disorganization, including giant capillaries, microhemorrhages, loss of capillaries, avascular areas, and angiogenesis [12–14].

4.2. Systemic sclerosis

Specific capillaroscopic alterations are found in the majority of cases of systemic sclerosis and often several years before diagnosis. The key element that distinguishes the scleroderma pattern is megacapillare. Another common finding is typical microhemorrhage called "pearls strung" or "Napoleon hat" usually overlying dilated capillaries or megacapillaries. Third distinctive element is represented by avascular areas. In 2000, the group of Genoa, headed by professor Cutolo, has identified three types of scleroderma pattern, referred to as "early," "active," and "late" [15–17].

We analyze below a capillaroscopic examination as a "scleroderma pattern."

Density: As is known in a healthy subject, the number of capillaries per millimeter is equal to 11 ± 2 while the number of capillaries for dermal papilla is equal to 2 ± 1 . In the case of scleroderma, pattern is common to find a reduction in the number of capillaries. In particular, the reduction of the density can range from focused frameworks (e.g., to a single papilla "vacuous papilla") to framework of rarefied widespread, until the total disappearance of capillaries with large subpapillary vascular areas. The most dramatic paintings are typical of late stages

or framework identified by Cutolo et al. as “late,” even if similar findings can be found in patients with recent symptoms onset, especially in progressive cases.

Structure: The most significant finding of scleroderma pattern, as said, is the megacapillare or a capillary which measures a greater diameter than 50 μm in correspondence with the two branches of the ascending and descending loops. In the case of diameters greater than 100 μm , it is called the capillary giant. The presence of only one megacapillare within a normal framework is not sufficient to define scleroderma pattern although suggests the need a follow up. The presence of two or more megacapillaries leads to a scleroderma pattern even in the absence of microhemorrhages or avascular areas.

Generally, the presence of megacapillari in the context of apparently normal capillaries, with few or absent microhemorrhages, characterizes the earliest stages of the disease and it is identified by Cutolo et al. as “early.” Instead, in the presence of numerous or ubiquitous megacapillari in the context of rare normal capillaries or ectatic capillaries, in the presence of numerous microhemorrhages in more districts, we will be faced to a capillary framework called “active.”

In the late stages of systemic sclerosis are sometimes pathognomonic capillary ramifications, with elongated and bizarre capillaries, or overgrowth of the subpapillary venous plexus, last attempt to make up for the total or almost total disappearance of the subpapillary capillaries. This framework configures the “late” scleroderma pattern.

Other detectable morphostructural abnormalities in scleroderma pattern are ectasia (capillaries in the range from 30 to 50 μm), the tortuosities, identifying, based on the forms as “staghorn,” “a clef,” “a glomerulus,” “ball,” etc. and microaneurysms. These alterations are not specific and can also be found in healthy subjects.

Microhemorrhages: They constitute an extremely common finding in the scleroderma pattern and, especially in the one called “active”. The typical hemorrhages of the scleroderma pattern may look as a mold, overlooking a megacapillare, or a giant capillary, or an aspect to “strung pearls” that are stacked in succession in the subpapillary and extrapapillary, never in deep seat. The microhemorrhages indicated breaking of capillary wall and are a sign of microvascular damage. There may be bleeding in the absence of megacapillari. The lonely bleeding are not considered sufficient for the identification of scleroderma pattern although, the presence of diffuse bleeding, even in the absence of further alterations, suggests necessarily the follow up.

The microhemorrhages should not be confused with traumatic hemorrhages that have a very heterogeneous presentation, generally overlying or adjacent to completely normal capillaries. Usually, they have a greater extension and can be found in the subpapillary-, deep- or extrapapillary segment.

Flow: The typical flow scleroderma patterns abnormalities are linked to the structural damage, in particular to megacapillaries. In these cases, the blood flow can appear slow or granular or even static. In the case of slow or static flow, a stimulus as the modest pressure exercised by the capillaroscopy probe is sufficient to make empty capillaries, and the capillaries will become fills when pressure is stopped. However, megacapillaries, giant capillaries, and the microaneurismatic capillaries remain completely filled both in the presence and in the absence of pressure stimulus, indicating a wall thickening causing static flow.

Edema (soft focus effect): Subpapillary edema is a constant finding in the case of capillaries vasodilatation in particular in the presence of megacapillaries and giant capillaries, so it is a typical finding in the scleroderma pattern. Edema could be mild, moderate, or severe and in these cases, subpapillary nous plexus is hardly visible.

Subpapillary venous plexus: It is clearly visible in healthy subjects and the extreme ages of life, can be seen in the case of early scleroderma pattern, is usually barely visible or not visible in the “active” phase, and is the only detectable findings in the late stage, where papillary capillaries are absent. Bizarre capillary ramifications are frequent findings in the late stage, as a last attempt to overcome the vascular deficit.

Scleroderma pattern:

- Early scleroderma pattern (**Figure 11(a–c)**): framework characterized by the presence of dilated capillaries and some megacapillaries. Microhemorrhages are poorly represented or absent. No reduction in capillary density.
- Active scleroderma pattern (**Figure 12(a) and (b)**): framework characterized by the widespread presence of megacapillaries and/or giant capillaries. A large number of microhemorrhages. No reduction in capillary density or occasional finding of “papilla vacua” in the presence of angiogenesis phenomena.
- Late scleroderma pattern (**Figure 13(a) and (b)**): framework characterized by the presence of rare lasts megacapillaries, abundant ramifications. Rare or absent microhemorrhages. Large avascular areas. Exuberance of the subpapillary venous plexus.

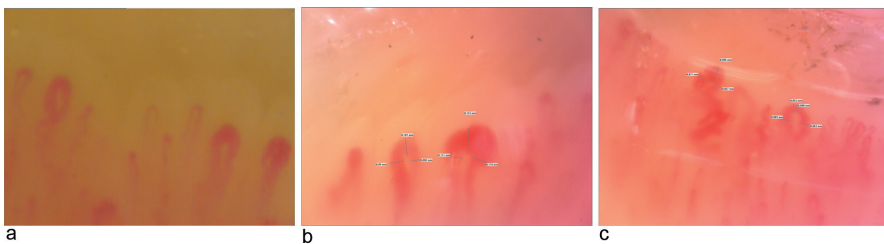


Figure 11. (a–c) Few megacapillaries without microhemorrhages.

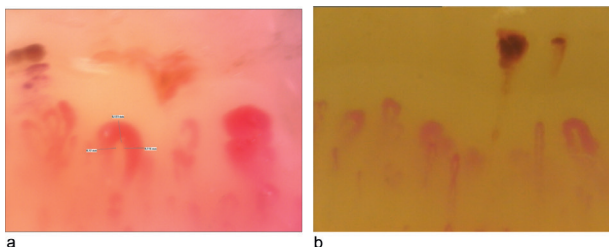


Figure 12. (a) and (b) Diffuse megacapillaries with microhemorrhages.

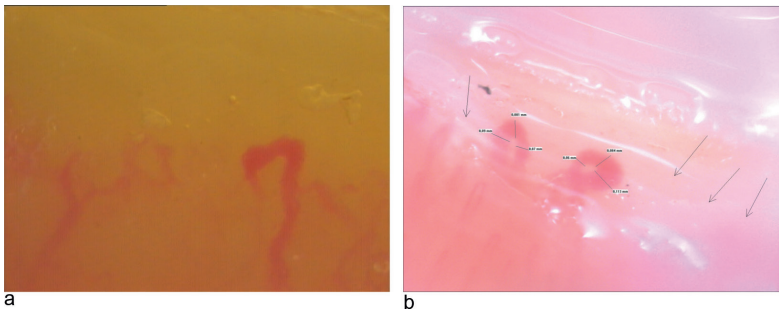


Figure 13. (a) and (b) “Papilla vacua,” diffuse or localized loss of capillaries.

5. Capillaroscopy in other rheumatic diseases

As mentioned, all of rheumatic diseases included in the scleroderma spectrum disorders may present a capillaroscopic framework suggesting for scleroderma pattern. However, in some diseases, there are typical capillary feature presentations. For example, in rheumatoid arthritis, extremely elongated capillaries are the principal findings (**Figure 14**) [18, 19].

In dermatomyositis, the most frequent findings are dilated and giant capillaries with tree-like appearance (**Figure 15(a)** and **(b)**).

Even in the case of psoriatic arthritis, capillaries appear rather short and stubby (**Figure 16**). However, these features are not enough specific to identify a defined framework.

5.1. Scoring method

In present-day clinical practice, capillaroscopic surveys are usually analyzed qualitatively in order to show patterns of disease (as previously stated). However, some authors share the idea that a normalization of the capillaroscopic pattern may be positive.

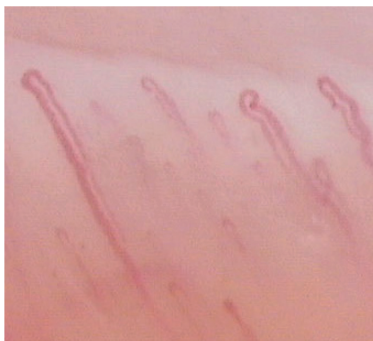

Figure 14. Capillaroscopy in rheumatoid arthritis.

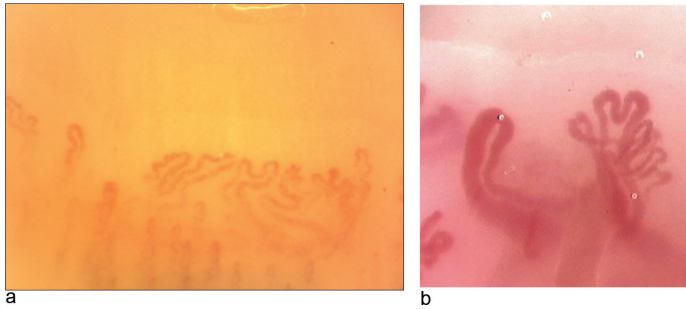


Figure 15. (a) and (b) Tree pattern in dermatomyositis.

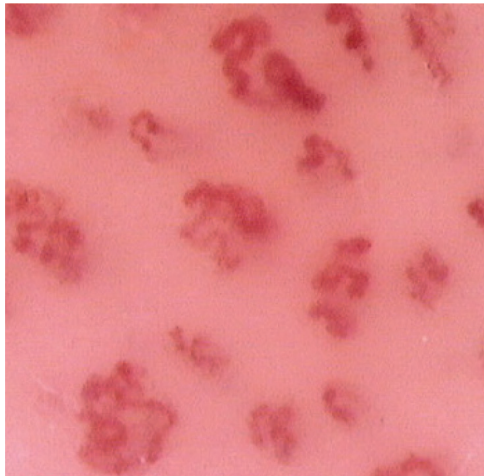


Figure 16. Capillaroscopy pattern in psoriatic arthritis.

Different scoring methods have been proposed to prospectively evaluate both the trend and the gravity of the scleroderma microangiopathy.

5.2. Semiquantitative method

One of these methods is the semiquantitative assessment which contemplates the analysis of the following capillaroscopic parameters:

1. Loss of capillaries: reduction of the number of capillaries to less than 9 per mm
2. Disorganization of the capillary architecture: irregular loops distribution, orientation, and morphology
3. Tree-like capillary network: capillaries with skein-like or shrub-like branched loops.

Each parameter is given a score based on the given impairment:

- 0: no alteration
- 1: capillary impairment up to 33%
- 2: capillary impairment higher than 33% and up to 66%
- 3: capillary impairment higher than 66%

The average score for each parameter comes from the analysis of four conterminous capillaroscopic areas (each area consisting of a 1 mm² surface) in the central part of the II, III, IV, and V finger of each hand.

The final score of each parameter is given by adding up the average scores of each finger; then the result is divided by 8. Lastly, the sum of the three scores constitutes the *microangiopathy evolution score* whose value may vary from 0 to 9.

On the basis of the capillaries loss only, such score is easier to determine and has been proposed as a predictor of digital ulcers. An average score of the capillaries number decrease is obtained by using capillary density as only parameter if a 1 mm² surface on eight fingers is analyzed. Scores that appear to be higher than 1.67 are shown to be a predictive factor of digital ulcers (Se 70%, Sp 69.77%, with a positive likelihood ratio of 2.32 and a negative likelihood ratio of 0.43) since such ulcers occur within 6–12 months after the capillaroscopic evaluation [20] (**Figure 17**).

5.3. Quantitative method

This method needs a strict standardization to be reproducible and comparable through time. As of today, the only quantitative score to be validated for both replicabilities and the predictive value is the *Capillaroscopy Skin Ulcer Risk Index* (CSURI), which is predictive for the incoming appearance of digital ulcers (which are already present within 3 months of the capillaroscopy) and for the nonfulfillment of their recovery (Se 92.3%, Sp 81.4 %, NPV 97.2%, TPV 84.3% with a PPV higher than 81% in the subgroup of patients with a history of ulcers appeared within a year).

The calculation is carried out by analyzing the whole nailfold area (from the II to the V finger of each hand, saving at least an image for each finger). Of all selected images, the one with the highest number of capillaries and the one with the lowest number of megacapillaries are to be considered; then the following formula has to be used: $M \times DN^2$ (with M: numbers of capillaries, D: maximum diameter, N: numbers of megacapillaries). Having at least a visible capillary is a prerequisite (otherwise the formula would be equal to 0; in fact, it is not possible to use it in 5% of patients. In this case, the formula is considered positive in principle). The analyzed area must be 1.57 mm wide. CSURI calculation is based on one image chosen between the saved one (the image with the lowest number of capillaries should be preferred) (**Figures 18 and 19**).

Capillaroscopic parameters are defined in a strict way so that reproducibility and replicability are optimized:




Figure 17. Number of fields studied: gold standard (F32) and successive simplifications (F16-F8-F4). (A) F32: eight fingers (arrows), four fields of 1 mm per finger, giving a total of 32 fields. (B) F16: eight fingers (arrows), two fields of 1 mm per finger, giving a total of 16 fields. (C) F8: eight fingers (arrows), one field of 1 mm per finger, giving a total of eight fields. (D) F4: one finger (arrows), four fields of 1 mm in that finger, giving a total of four fields [20].

- Number of capillaries: all the capillaries in the first row (the ones closest to the papilla) must be counted even if they are all different depths.
- Megacapillary: maximum measurable diameter in the first row (microaneurysms should not be included).
- Tree-like morphology: a tree-like capillary is equivalent to the number of taken papillae or to the number of observable loops.

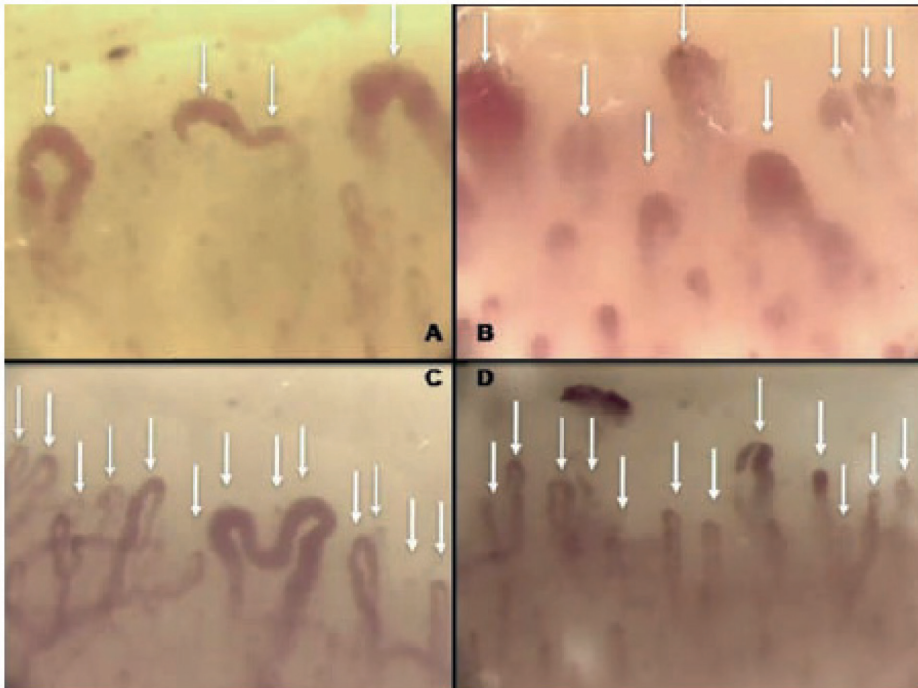


Figure 18. Examples of capillaroscopic finding measurements. (A) 4 capillaries, 3 giant capillaries (1 ramified giant capillaries occupying both dermal papillae). (B) 8 capillaries, 5 giant capillaries (every capillary was counted in the distal row even if it was not on the same level). (C) 13 capillaries, 1 giant capillary (1 ramified giant capillary computed as 2 in the total number count). (D) 12 capillaries, 1 giant capillaries (every capillary was counted in the distal row even if it was not on the same level) [14].

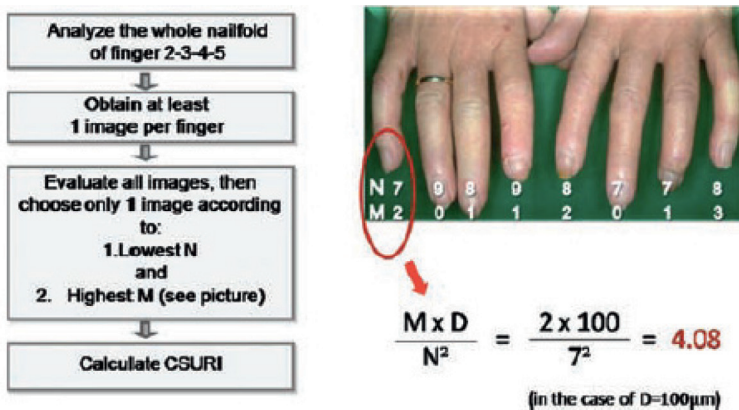


Figure 19. Algorithm for capillaroscopic skin ulcer risk index (CSURI) evaluation. D, Maximum diameter of mega capillary; M, number of megacapillaries (diameter $\geq 50 \mu\text{m}$); N, number of capillaries [14].

The CSURI value per patient is the maximum computable if the whole nailfold area is analyzed so that the highest score of microangiopathy is defined. PROs: number of false negatives <3%. CONS: a higher risk of increasing the false positives.[21].

5.4. Prognostic index

The *Prognostic Index for Nailfold Capillaroscopic Examination* (PRINCE: **Table 2**) allows to stratify the risk of development of a scleroderma spectrum disorder over a period of 5 years in

Parameters	Value	Log HR		Score
A. Megacapillaries	Absent=0 Present=1	0.46	A	N x 0.46
B. Microhemorrhages	Absent=0 Present=1	0.57	B	N x 0.57
C. Number of Capillaries	linear	0.41	C	N x 0.41 + (t1+t2+t3)
	Non linear (t1+t2+t3)			
	No. ≤3.8	t1 0 t2 0 t3 0		
	No. 3.9 to 7.2	t1 -0.41x[(N3.8)/3.45] ³ t2 0 t3 0		
	No. 7.3 to 10.2	t1 -0.41x[(N3.8)/3.45] ³ t2 6.4x[(N-7.25)/3.45] ³ /2.95 t3 0		
	No ≥ 10.3	t1 -0.41x[(N3.8)/3.45] ³ t2 6.4x[(N-7.25)/3.45] ³ /2.95 t3 3.45x[(N-10.2)/3.45] ³		
Total Score	A + B + C			

N.: mean number of capillaries/mm

Table 2. Prognostic parameters of PRINCE index.

patients with Raynaud syndrome by analyzing the three main capillaroscopic anomalies (with the survey of a 1 mm area per finger):

- Presence of megacapillaries
- Presence of microhemorrhages
- Numbers of capillaries per mm

The inclusion of antinuclear antibodies allowed to develop an additional predictive model with the following risk categories: high (50+ %), medium (10–50%) and low risk (<10%) (Figure 20) [22].

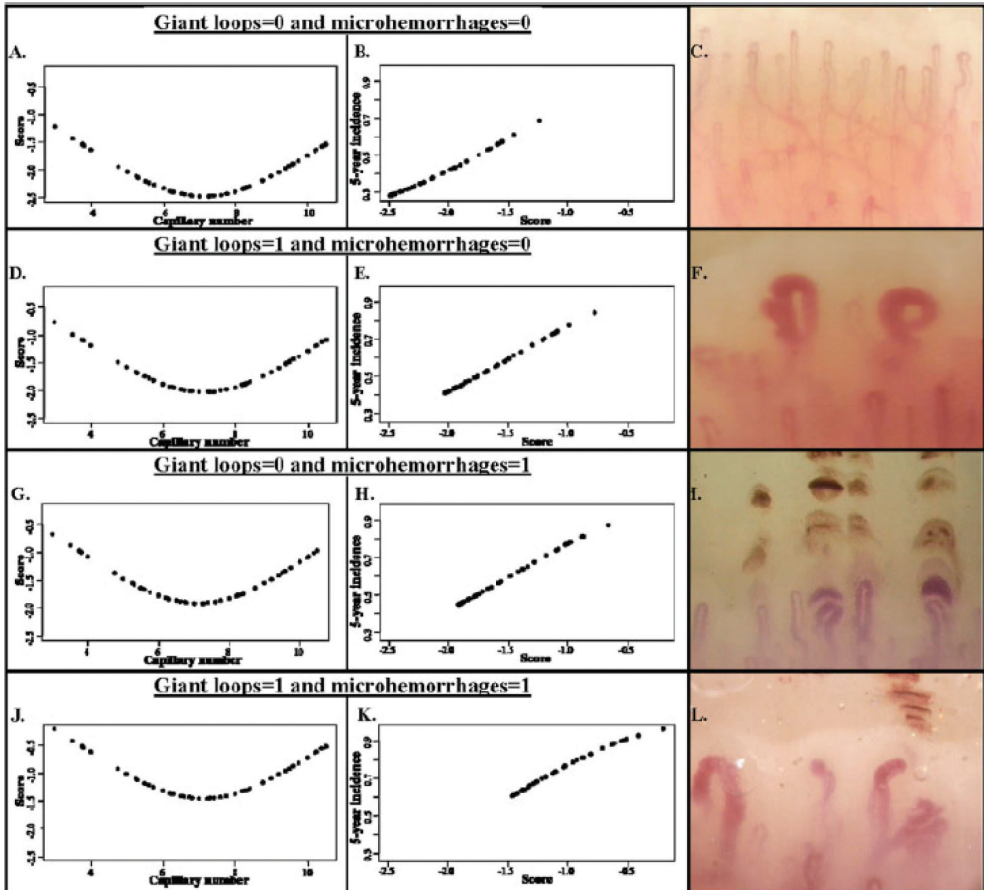


Figure 20. Prognostic Index for Nailfold Capillaroscopic Examination (PRINCE). A, D, G, and J: possible combination of giant loops and microhemorrhages (0 = absent, 1 = present). The score (on the y-axis) is obtained as a function of the number of capillaries (represented on the x-axis). B, E, H, and K: data used with the corresponding scores in A, D, G, and J to obtain the incidence and thus deduce the risk of developing Raynaud's phenomenon secondary to a scleroderma spectrum disorder. C, F, I, and L: examples of capillaroscopic patterns [22].

6. The role of capillaroscopy in the early diagnosis of systemic sclerosis

The role of capillaroscopy has been considered over the years more and more attention, especially in the early diagnosis of systemic sclerosis. Then, to detect valid predictors of early systemic sclerosis, the European Scleroderma Trials and Research group (EUSTAR) identified three red flags, thanks to the VEDOSS program (very early diagnosis of systemic sclerosis): Raynaud’s phenomenon (RP), antinuclear antibodies (ANA) positivity, and puffy fingers are the main elements to suspect systemic sclerosis. In the case of these three flags performing, further tests to confirm the diagnosis, in particular nailfold video-capillaroscopy and evaluation of specific disease antibodies (anticentromere and antitopoisomerase I), are mandatory. The challenge of VEDOSS program is to identify patients who will develop an established systemic sclerosis.

Very recently, the first results of the VEDOSS project were processed and new EULAR/ACR (American College of Rheumatology) classification criteria have been validated and published (2013), in which the capillaroscopic characteristic changes have been included (requiring at least two, or better, all four items to be present) (Figure 21) [23, 24].

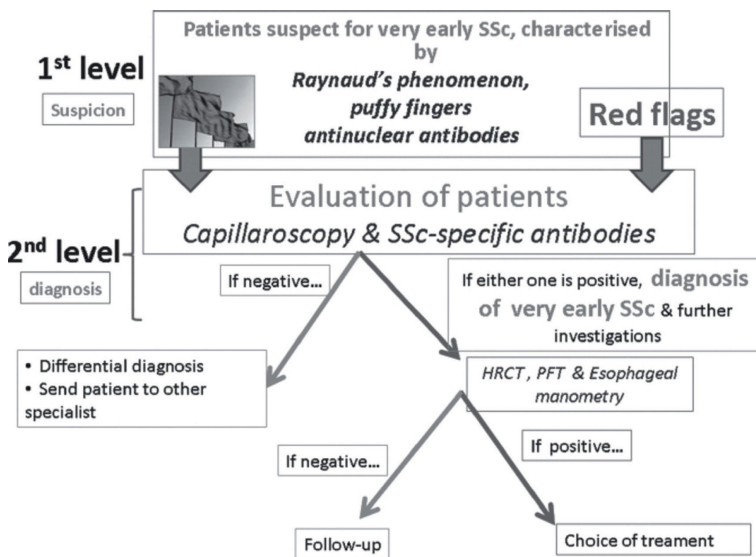


Figure 21. A behavioral flow chart for patients in whom the very early diagnosis of systemic sclerosis (SSc) should be considered is proposed. Red flags should trigger the differential diagnosis of SSc and guide the general practitioner to send the patient to the referral center where capillaroscopy and specific autoantibodies are ordered and the diagnosis of very early SSc is made. HRCT, high resolution CT; PFT, pulmonary function tests [23].

7. Conclusions

Capillaroscopy is an easily tolerable, noninvasive, important angiologic examination method. In the case of Raynaud’s phenomenon, associated or not with signs or symptoms

suggestive for connective tissue disorders or in the presence of autoantibodies (in particular, antinuclear antibodies (ANA) and extractable nuclear antigens (ENA)), capillaroscopy is a crucial examination that adds irreplaceable information to formulate a diagnosis. In the meantime, capillaroscopy has achieved a firm status in the early diagnosis of systemic sclerosis (SSc).

7.1. Capillaroscopic template

The report should include capillaroscopic terms understandable to nonexperts and should be as standardized as possible, using both qualitative and quantitative parameters that reliable and establishing normal limits (Figure 22). In the presence of capillaroscopic, more alterations (megacapillaries, microhemorrhages, neoangiogenesis, density decrease,) a greater degree of detail is required, indicating although these alterations are present on only one or a few fingers.

CAPILLAROSCOPIC TEMPLATE

Patient personal data: _____

Medical History: Duration of Raynaud's Phenomenon, Concomitant Medication, Digital Ulcers, ecc..

Side: right – left

- Structure: homogeneous/normal – inhomogeneous/abnormal

- Microhaemorrhages: present – absent – number __

- Edema (soft focus effect): present – absent

- Sub-papillary venous plexus: visible – not visible

- Decreased Density: absent – localized or diffuse , <30% 30-70% >70%

- Tortusity: present – absent

- Megacapillaries: present – absent – number __

- Neoangiogenesis: present – absent

Conclusion/Pattern: Aspecific Scleroderma Early Scleroderma Active Scleroderma Late

Prognostic Index: MES – PRINCE – CSURI Score __

Comments: _____

Figure 22. Example of Capillaroscopic Template.

Author details

Simone Parisi* and Maria Chiara Ditto

*Address all correspondence to: simone.parisi@hotmail.it

Rheumatology Unit, Azienda Ospedaliera Universitaria Città della Salute e della Scienza di Torino, Turin, Italy

References

- [1] De Angelis R, Ferri C, Sebastiani M, Manfredi A, Grassi W. *La capillaroscopia in reumatologia. Lesioni elementari e metodi di scoring* 2012 Mattioli 1885 Editore. ISBN: 9788862613194
- [2] Van den Hoogen F, et al. Classification criteria for systemic sclerosis: An American College of Rheumatology/European League against Rheumatism collaborative initiative. *Arthritis & Rheumatology*. 2013 Nov;**65**(11):2737-2747
- [3] Anderson ME, et al. Computerized nailfold video capillaroscopy—A new tool for assessment of Raynaud's phenomenon. *Journal of Rheumatology*. 2005 May;**32**(5):841-848
- [4] Cutolo M. *Atlas of Capillaroscopy in Rheumatic Disease*. Elsevier 2010 ISBN: 9788821433917
- [5] Fahrig C, et al. Capillary microscopy of the nailfold in healthy subjects. *International Journal of Microcirculation*. 1995 Nov-Dec;**15**(6):287-292
- [6] Batticciotto A, et al. Feet nailfold capillaroscopy is not useful to detect the typical scleroderma pattern. *Clinical and Experimental Rheumatology*. 2012 Mar-Apr;**30**(2 Suppl 71): S116-S117
- [7] Cutolo M, Sulli A, Pizzorni C, Accardo S. Nailfold videocapillaroscopy assessment of microvascular damage in systemic sclerosis. *J Rheumatol*. 2000 Jan;**27**(1):155-60
- [8] Hoerth C, et al. Qualitative and quantitative assessment of nailfold capillaries by capillaroscopy in healthy volunteers. *Vasa*. 2012 Jan;**41**(1):19-26
- [9] Kabasakal Y, et al. Quantitative nailfold capillaroscopy findings in a population with connective tissue disease and in normal healthy controls. *Annals of the Rheumatic Diseases*. 1996 Aug;**55**(8):507-512
- [10] De Angelis R, et al. A growing need for capillaroscopy in rheumatology. *Arthritis & Rheumatology*. 2009 Mar 15;**61**(3):405-410
- [11] LeRoy EC, Medsger TA Jr. Criteria for the classification of early systemic sclerosis. *Journal of Rheumatology*. 2001 Jul;**28**(7):1573-1576
- [12] Anderson ME, Allen PD, Moore T, Jayson MI, Herrick AL. Computerized nailfold videocapillaroscopy—A new tool for assessment of Raynaud's phenomenon. *Journal of Rheumatology*. 2005;**32**:841-848
- [13] Sulli A, Secchi ME, Pizzorni C, Cutolo M. Scoring the nailfold microvascular changes during the capillaroscopic analysis in systemic sclerosis patients. *Annals of the Rheumatic Diseases* 2008;**67**:885-887
- [14] Sebastiani M, Manfredi A, Vukatana G, Moscatelli S, Riato L, Bocci M, Iudici M, Principato A, Mazzuca S, Del Medico P, De Angelis R, D'Amico R, Vicini R, Colaci M, Ferri C. Predictive role of capillaroscopic skin ulcer risk index in systemic sclerosis: A multicentre validation study. *Annals of the Rheumatic Diseases*. 2012 Jan;**71**(1):67-70

- [15] Bellando-Randone S, Guiducci S, Matucci-Cerinic M. Very early diagnosis of systemic sclerosis. *Polskie Archiwum Medycyny Wewnętrznej*. 2012;**122**(Suppl 1):18-23
- [16] Lambova S1, Hermann W, Muller-Ladner U. Nailfold capillaroscopy—Its role in diagnosis and differential diagnosis of microvascular damage in systemic sclerosis. *Current Rheumatology Reviews*. 2013;**9**(4):254-260
- [17] Valentini G, Marcoccia A, Cuomo G, Iudici M, Vettori S. The concept of early systemic sclerosis following 2013 ACR\EULAR criteria for the classification of systemic sclerosis. *Current Rheumatology Reviews*. 2014;**10**(1):38-44
- [18] Selva O'Callaghan A, Fonollosa-Pla V, Trallero-Araguas E, Martinez-Gomez X, Simeon Aznar CP, Labrador-Hornillo M, Vilardell-Tarres M. Nailfold capillary microscopy in adults with inflammatory myopathy. *Seminars in Arthritis and Rheumatism*. 2010;**39**:398-404
- [19] De Angelis R, Cutolo M, Gutierrez M, Bertolazzi C, Salffi F, Grassi W. Different microvascular involvement in dermatomyositis and systemic sclerosis. A preliminary study by a tight videocapillaroscopic assessment. *Clinical and Experimental Rheumatology*. 2012;**30**(2 Suppl 71):S67-S70
- [20] Smith V, De Keyser F, Pizzorni C, Van Praet JT, Decuman S, Sulli A, Deschepper E, Cutolo M. Nailfold capillaroscopy for day-to-day clinical use: Construction of a simple scoring modality as a clinical prognostic index for digital trophic lesions. *Clinical and Experimental Rheumatology*. 2011 Jan;**70**(1):180-183
- [21] Sebastiani M, Manfredi A, Colaci M, D'amico R, Malagoli V, Giuggioli D, Ferri C. Capillaroscopic skin ulcer risk index: A new prognostic tool for digital skin ulcer development in systemic sclerosis patients. *Arthritis & Rheumatology*. 2009 May 15;**61**(5):688-694
- [22] Ingegnoli F, Boracchi P, Gualtierotti R, Lubatti C, Meani L, Zahalkova L, Zeni, S, Fantini F. Prognostic model based on nailfold capillaroscopy for identifying Raynaud's phenomenon patients at high risk for the development of a scleroderma spectrum disorder: PRINCE (prognostic index for nailfold capillaroscopic examination). *Arthritis & Rheumatology*. 2008 Jul;**58**(7):2174-282
- [23] Avouac J, Franssen J, Walker UA, Riccieri V, Smith V, Muller C, Miniati I, Tarnier IH, Randone SB, Cutolo M, Allanore Y, Distler O, Valentini G, Czirjak L, Müller-Ladner U, Furst DE, Tyndall A, Matucci-Cerinic M; EUSTAR Group. Preliminary criteria for the very early diagnosis of systemic sclerosis: Results of a Delphi Consensus Study from EULAR Scleroderma Trials and Research Group. *Annals of the Rheumatic Diseases*. 2011 Mar;**70**(3):476-481
- [24] Guiducci S, Bellando-Randone S, Matucci-Cerinic M. A new way of thinking about systemic sclerosis: The opportunity for a very early diagnosis. *The Israel Medicine Association Journal*. 2016 Mar-Apr;**18**(3-4):141-143

