

A BRIEF DISSECTION GUIDE TO HUMAN THORAX

Carla Zannelli ^{1*}, Marco Scaglione ^{1*}, Carola Gagliardo ^{1*}, Margherita Mazzola ^{2*}, Dario Saguto ^{1,2}, Riccardo Antonini ¹, Vincenzo Canalella ¹, Arianna Melita ¹, Arianna Sferruzza ¹, Simona Rusignuolo ¹, Giovanni Tomasello ^{2^}, Francesco Carini ^{2^}

1. School of Medicine and Surgery, University of Palermo, Palermo, Italy

2. Department of Biomedicine, Neurosciences and Advanced Diagnostics, University of Palermo, Palermo, Italy

ARTICLE INFO

Article history:

Received 27 March 2020

Revised 22 April 2020

Accepted 25 April 2020

Keywords:

Human Thorax, dissection guide, medical students.

ABSTRACT

The purpose of this technical report is to present the experience that, in summer 2018, a group of students from the University of Palermo did at the University of Malta. The students have had the experience to dissected a thorax under the guide of expert dissectors. This work would be also a small dissection guide for young medical students who want to learn the main bases of dissection.

© EuroMediterranean Biomedical Journal 2020

1. Introduction

In Italian Universities, usually, the study on anatomical sciences has been basically carried out on anatomic models and books. At the University of Malta, instead, the aforesaid study is carried out with anatomical dissections since several years. Thanks to an agreement between the University of Malta and the University of Palermo, a group of medical students was able to go to Malta to carry out a dissection course. The selected students have been selected by University of Palermo in relation to the good quality of their university career and their good knowledge of the English language. The course was held in the sector room of the University of Malta, where dissections were carried out with careful separation of anatomical structures and of tutors from both the universities, as previously described (1-4). The aim of this work is to analyse, *ex vivo*, the thoracic cavity and its topographical anatomy. In the thoracic cavity each region contains different structures, which knowledge allows us to perform an accurate dissection, both for theoretical and clinic and surgical purposes.

2. Material and methods

For dissection we used two corpses, died of natural causes: 80-year-old man and a 75-year-old woman. We used surgical instrument such as blade (size 22), Mayo scissors, shears for ribs, scalpel (handle size 4), and anatomical and surgical forceps. During the dissection, the operators wore surgical uniforms (scrubs), latex gloves, surgical mask and protective glasses. The two bodies were each placed on a dissection table, and dissection of the thoracic cavity started by a large and deep Y-shaped incision at the top of each shoulder and running down the front of the chest, meeting at the lower point of the sternum.

3. Technical report

Practicing a Y-shaped incision, we described:

1. Skin
2. Subcutaneously
3. Superficial muscles (pectoralis major) disconnected

Then, we executed a triangle-shaped incision of the chest wall, cutting ribs, intercostal muscles, endothoracic fascia and parietal pleura respectively, as illustrated in Figure 1.

* Corresponding author: Francesco Carini, francesco.carini@unipa.it

DOI: 10.3269/1970-5492.2020.15.14

All rights reserved. ISSN: 2279-7165 - Available on-line at www.embj.org

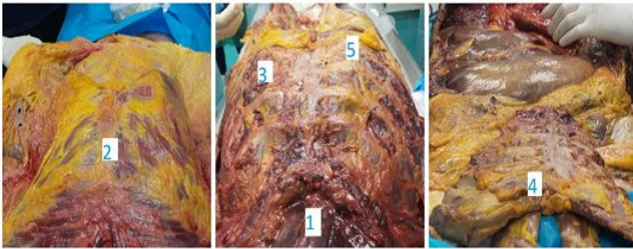


Figure 1. Illustration of the first dissection's steps, from left to right. 1) Sternohyoideus muscle; 2) Body of sternum; 3) Ribs; 4) Chondrosternal complex removed; 5) External intercostal muscles.

Removed the chondrosternal complex, we have accessed the thoracic cavity (Figure 2). The central compartment, delimited in each side by mediastinal pleura, of the cavity is the mediastinum. Anatomically, the mediastinum is divided into two parts by an imaginary line that runs from the sternal angle (the angle formed by the junction of the sternal body and manubrium) to the T4 vertebrae: Superior mediastinum – extends upwards, terminating at the superior thoracic aperture, and inferior mediastinum, extends downwards, terminating at the diaphragm.

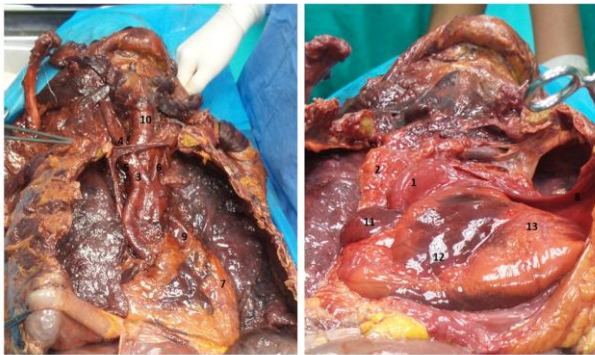

Figure 2. Anterior view of the thoracic cavity. In the right side the pericardium has been opened. 1) Arch of aorta; 2) Superior vena cava; 4) Brachiocephalic vein; 5) Neurovascular bundle of the neck; 6) Origin of the left subclavian vein; 7) Left common carotid artery; 8) Pericardial fat pad; 9) Opened pericardium; 10) Pulmonary trunk; 11) Trachea; 12) Right atrium; 13) Right ventricle; 14) Left ventricle

The last one is further subdivided into the anterior mediastinum, middle mediastinum and posterior mediastinum. After the pericardial incision, the dissection continued lifting firstly the right lung and then the left one, in order to observe the posterior structures of mediastinum, as showed in figure 3.

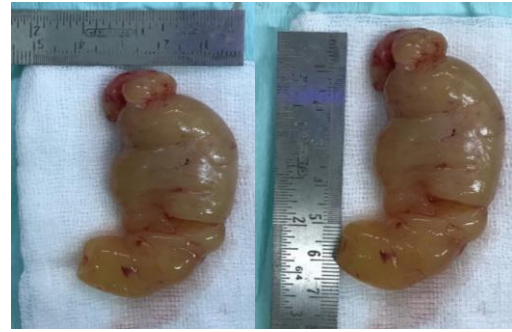

Figure 3. Posterior view of mediastinal structures. In the right side right lung is lifted. 1) Lifted right lung; 2) Lifted left lung; 3) Azygos vein; 4) Inferior vena cava; 5) Azygos' confluent small vessel; 6) Descendent tract of thoracic aorta.

4. Discussion and conclusions

Studying anatomy using a cadaver dissection is the ideal complement to studying books and atlases (5-8). In fact, through dissection it is possible to acquire a greater awareness of anatomical structures but also of the relationships between the various organs. Furthermore, dissection allows to acquire morphological-functional knowledge, useful for understanding the pathologies affecting the anatomical structures of a particular district. The opportunity to integrate theoretical studies with dissection should be a practice accessible to all students in order to strengthen the practical component of medical students' knowledge (9 - 16).

References

- Pollara P, Inzerauto P, Ravi N, Tomasino C, Scorsone A, Liguoro B, Busardò FP, Slama F, Capitummino R, Seidita E, Tomasello G, Carini F, Pomara C. Experiences that "Reach the heart". Taking part in a whole body dissection course at the University of Malta. *EuroMediterranean Biomedical Journal*. 2017, 12 (22): 108-112.
- Etrusco A, Salvaggio L, Arrigo G, Cataldi S, Farina C, Gattuso I, La Bruna M, Pistone M, Tinaglia S, Torregrossa F, Carini F, Tomasello G, Pomara C. Anatomical dissection and analysis of the structures of the upperlimb. *EuroMediterranean Biomedical Journal*. 2017, 12 (04): 13-16.
- Carini F, Salerno M, Mazzola M, Lo Piccolo C, Cavallo G, Musso S, Gentile S, D'Accardo S, La Mantia A, Accardo A, Baldari B, Besi L, Scopetti M, Faleo M, Zammit C, Tomasello G. A brief anatomo-surgical dissection guide to human neck: results of the collaboration between the University of Palermo and the University of Malta. *EuroMediterranean Biomedical Journal*. 2018, 13 (14): 69-72.
- Scaglione M, Zannelli C, Antonini R, Canalella V, Melita A, Rà W, Rusignuolo S, Sferruzza A, Gagliardo C, Guarrera A, Lo Piccolo C, Mazzola M, Saguto D, Carini F, Tomasello G. A dissection's guide to human abdominal cavity. *EuroMediterranean Biomedical Journal*. 2020, 15 (08): 36-39

5. Netter F.H. *Atlante di Anatomia Umana*. 2014, Edra.
6. Gilroy AM, MacPherson BR, Ross LM. *Prometheus. Atlante di Anatomia*. 2019. Edises.
7. Pomara C, Karch SB, Finesch V. *Forensic autopsy – a Handbook and atlas*. 2010. CRC.
8. Rohen JW, Yokochi C, Lutjen-Drecoll E. *Color Atlas of Anatomy – a photographic study of human body*. 2006. Piccin.
9. Costantino C, Moscadini S, Puccio G, Cappello F, Mazzucco W. EuroMediterranean biomedical journal: the renewed manuscript layout and web rendering foreshadow further journal improvement. *EuroMediterranean Biomedical Journal*. 2017, 12 (1):1-5.
10. Costantino C, Moscadini S, Puccio G, Cappello F, Mazzucco W. EuroMediterranean Biomedical Journal: a new policy about self-referencing. *EuroMediterranean Biomedical Journal*. 2020, 15 (1):1-3.
11. Costantino C, Moscadini S, Puccio G, Cappello F, Mazzucco W. EuroMediterranean biomedical journal: The renewed journal for young doctors aims even higher. *EuroMediterranean Biomedical Journal* 2014, 9 (1): 1-6.
12. Costantino C, Maringhini G, Albegiani V, Monte C, Lo Cascio N, Mazzucco W. Perceived need for an International elective experience among Italian medical residents. *EuroMediterranean Biomedical Journal*. 2013, 8 (3):10-15.
13. Marotta C, Raia DD, Ventura G, Casuccio N, Dieli F, D'Angelo C, Restivo V, Costantino C, Vitale F, Casuccio A. Improvement in vaccination knowledge among health students following an integrated extra curricular intervention, an explorative study in the University of Palermo. *J Prev Med Hyg*. 2017 Jun;58(2):E93-E98.
14. Costantino C, Ledda C, Genovese C, Contrino E, Vitale E, Maida CM, Squeri R, Vitale F, Rapisarda V. Immunization Status against Measles of Health-Care Workers Operating at Three Sicilian University Hospitals: An Observational Study. *Vaccines (Basel)*. 2019 Nov 3;7(4):175.
15. Peri D, Ardizzone E, Gaglio S, Gerbino A, Buscemi M, Mandracchia R, Valentino B, Cappello F, Lo Verde R, Marciano V, Peri G. Three-dimensional geometrical models of the liver. *Ital J Anat Embryol*. 2006 Jan-Mar;111(1):23-30.
16. Peri D, Pirrone R, Ardizzone E, Gaglio S, Gerbino A, Cappello F, Farina F, Marcianò V, Palma A, Peri G. Three-dimensional geometrical models of the inguinal region. Towards a new stereology. *Ital J Anat Embryol*. 2003 Oct-Dec;108(4):223-30.