

Two fatal cases of acute liver failure due to HSV-1 infection in COVID-19 patients following immunomodulatory therapies

Stefano Busani¹ M.D., Andrea Bedini² M.D., Emanuela Biagioni¹ M.D., Lucia Serio¹ M.D., Roberto Tonelli³ M.D., Marianna Meschiari² M.D., Erica Franceschini² M.D., Prof. Giovanni Guaraldi² M.D., Prof Andrea Cossarizza⁴ M.D., Prof Enrico Clini³ M.D., Prof Antonino Maiorana⁵ M.D., William Gennari⁶ M.D., Nicola De Maria⁷ M.D., Prof Mario Luppi⁸ M.D., Prof Cristina Mussini² M.D., Prof Massimo Girardis¹ M.D., on behalf of the Modena Covid-19 Working Group (MoCo19)*.

1. Anesthesia and Intensive Care Medicine, Policlinico di Modena, University of Modena and Reggio Emilia, Modena, Italy
2. Infectious Diseases Unit, Policlinico di Modena, University of Modena and Reggio Emilia, Modena, Italy
3. Respiratory Diseases Unit, Policlinico di Modena, University of Modena and Reggio Emilia, Modena, Italy
4. Department of Medical and Surgical Sciences for Children and Adults, University of Modena and Reggio Emilia, Modena, Italy
5. Institute of General Pathology, University of Modena and Reggio Emilia, Modena, Italy
6. Virology and Molecular Microbiology Unit, Policlinico di Modena, University of Modena and Reggio Emilia, Modena, Italy
7. Gastroenterology Unit, Policlinico di Modena, University of Modena and Reggio Emilia, Modena, Italy.
8. Hematology Unit, Policlinico di Modena, University of Modena and Reggio Emilia, Modena, Italy.

Corresponding author:

Stefano Busani, M.D.

e-mail: stefano.busani@unimore.it

Terapia Intensiva Polivalente

Azienda Ospedaliera-Universitaria Policlinico di Modena

Via del Pozzo, 41124 Modena, Italy

Telephone: +39-059-4224896/7

Accepted Manuscript

ABSTRACT:

We reported two fatal cases of acute liver failure secondary to Herpes Simplex Virus 1 infection in COVID-19 patients, following tocilizumab and corticosteroid therapy. Screening for and prompt recognition of Herpes Simplex Virus 1 reactivation in these patients, undergoing immunomodulatory treatment, may have potentially relevant clinical consequences.

Accepted Manuscript

BACKGROUND

In patients with SARS-CoV-2 infection, high levels of pro-inflammatory cytokines and chemokines seem to be related to severe pneumonia and poor outcome [1]. The use of immunomodulating therapies to counteract the “cytokine storm” has been proposed [2] and widely prescribed on a compassionate basis in Italy since the beginning of the SARS-CoV-2 epidemic, despite the lack of an evidence-based benefit or data regarding serious side effects.

During SARS-CoV-2 infection, liver damage may occur [3] as a result of a variety of mechanisms [4]. Although liver impairment is fairly frequent during SARS-CoV-2 infection, acute liver failure has never been reported so far.

We describe the cases of two COVID-19 patients who developed acute liver failure (ALF) secondary to herpes simplex virus 1 (HSV-1) infection, out of 107 consecutive COVID-19 patients admitted to intensive care unit (ICU) from February 25th to April 25th, 2020. Our hospital is a liver transplant centre and local reference centre for the treatment of acute liver failure.

PATIENT 1: a 66-year-old man, with a history of hypertension, hypercholesterolemia and depression presented to our hospital with interstitial bilateral pneumonia. PaO₂/FiO₂ ratio at admission was 188, C-reactive protein (CRP) 4.2 mg/dL and lactate dehydrogenase (LDH) 2156 U/L. A nasopharyngeal swab for SARS-CoV-2 tested positive. The patient was treated according to the Emilia-Romagna Regional guidelines [5] with hydroxychloroquine (400 mg/two times a day for 3 days, then tapered to 200 mg/twice a day for the following 4 days) and azithromycin (500 mg/day for 5 days). On day 2, due to respiratory failure requiring noninvasive

ventilation, tocilizumab was administered subcutaneously, 162 mg in two different sites. On day 4, laboratory exams documented the persistence of high levels of LDH 1997 U/L, ferritin 1028 ng/mL and D-dimer >40,000 ng/mL together with total lymphocytes count (TLC) 580 cells/mm³, so methyl-prednisolone 80 mg was added and then tapered to 40 mg/day for 3 days and 20 mg/day for 1 day. In the following days, the patient progressively restored respiratory function and biochemistry, but TLC remained below normal range; he also developed mental confusion and agitation and was treated with morphine, midazolam and antipsychotics. On day 12, the patient had a new fever episode up to 38.1 °C with severe alterations in liver function tests aspartate aminotransferase (AST) 2672 U/L and alanine aminotransferase (ALT) 2471 U/L, with total bilirubin 0.98 mg/dL. On day 13, further deterioration of laboratory data was present with ALT 9627 U/L, total bilirubin 2.32 mg/dL, LDH 34415 U/L, prothrombin time (PT) INR 3.04, D-Dimer 20,940 ng/mL, platelets 20,000/mm³, creatinine 2.18 mg/dL and TLC 360 cell/mm³. Screening for HAV, HBV, HCV, CMV and EBV was negative and abdominal computed tomography (CT) showed no signs of hepatic veno-occlusive disease. On day 14, the patient was admitted to our ICU with the diagnosis of ALF of unknown origin with PT INR 6.62 and fibrinogen 48 mg/dL. Clinical deterioration included stupor, hypotension and acute renal failure. On day 15, more than 14,375,000 copies/mL of HSV-1 were detected by real-time PCR assay on cell-free plasma collected on day 13 and, thereby, we immediately started therapy with acyclovir 800 mg (10 mg/kg)/3 times a day, then adjusted on creatinine clearance. The patient rapidly developed hyperdynamic shock with bleeding from the nasogastric tube and neurological deterioration up to Glasgow Coma Scale (GCS) 3/15 with anisocoria occurrence. A brain CT scan reported a diffuse hypodensity of the cortex profile associated with a reduction of cortico-subcortical differentiation. Refractory

metabolic acidosis with irreversible shock and terminal liver function led patient to death 17 days after his hospital admission (Figure 1).

PATIENT 2: a 49-year-old man with a body-mass index of 32 and no significant medical history was admitted to the Medicine Department of another hospital due to bilateral interstitial pneumonia and hypotension. A nasopharyngeal swab for SARS-CoV-2 tested positive.

On day 2, the patient started treatment with hydroxychloroquine (same regimen as above) [5]. On day 6, due to a worsening of dyspnea and $\text{PaO}_2/\text{FiO}_2$ ratio of 108 that was poorly responsive to oxygen therapy, the patient was admitted to ICU to undergo invasive mechanical ventilation. On day 13, considering the persistent respiratory failure and the radiological worsening of parenchymal thickening, two doses of tocilizumab 800 mg were intravenously administered 12 hours apart, while TLC was 320 cell/mm^3 . On day 25, the patient developed delirium with panic attacks and extreme agitation treated with dexmedetomidine and antipsychotics. On day 29, during weaning from mechanical ventilation, the patient developed a fever and laboratory data showed in the subsequent days a progressive increase in ALT = 6080 U/L and AST = 6906 U/L, with total bilirubin 0.7 mg/dL. A CT scan did not evidence ongoing veno-occlusive liver disease and screening for hepatotropic viruses was negative. On day 33, the patient was admitted to our ICU with the diagnosis of ALF of unknown origin. Once admitted to our ICU, we obtained the report of more than 14,375,000 HSV-1 copies/mL on cell-free plasma by real-time PCR assay, so acyclovir 800 mg (10 mg/kg of ideal body weight)/3 times a day was started.

The patient worsened neurologically and developed severe coma (GCS 3/15) with electroencephalographic changes compatible with severe metabolic insufficiency. A lumbar puncture was performed and the analysis of the cerebrospinal fluid (CSF) showed 810,765 HSV-1 copies/mL, while resulted negative for either SARS-CoV-2 or other common herpesviruses or fungal pathogens, regardless ongoing on acyclovir for 5 days. Unfortunately, despite intensive support of vital functions, massive liver cytolysis with unresponsive hyperdynamic shock developed. The patient died 6 days after the admission to our ICU and 39 days after hospital admission (Figure 1).

In both patients, the post-mortem liver biopsy analysed in real-time PCR assay detected very high values of HSV-1 copies (6,695,396 copies/100,000 liver cells and 9,887,425 copies/100,000 liver cells, respectively) and no presence of SARS-Cov-2. In addition, in both patients, chemiluminescence-immunoassay indicated negative tests for IgG (3 UA/mL and 1 UA/mL) and IgM (5 UA/mL and 2 UA/mL) titres against HSV-1 (negative ranges: IgG <7.5 AU/mL and IgM <16 AU/mL) in serum samples collected on ICU admission. Both patients had an unknown pre-existing history of clinical disease due to HSV-1 infection.

Histopathological findings in both patients were as follows: the liver exhibited irregular confluent areas of haemorrhagic necrosis. In residual viable zones, hepatocytes with enlarged nuclei and rare multinucleated cells were observed, but Cowdry type A inclusions were not seen. Inflammatory infiltrates in portal tracts and lobules were almost absent, as described in other HSV-1 hepatitis cases. Positive immunoreactivity to HSV-1 antibody was detected in nuclei of hepatocytes (Figure 2), whereas the reactions for HSV2, CMV and adenovirus were negative.

DISCUSSION

Hospitalised patients with severe COVID-19 pneumonia have a dysregulated immune response and may develop a stage of immune suppression after the pro-inflammatory phase [6]. Some authors have highlighted the risk related to an unbalanced use of immunosuppressive therapies in COVID-19 disease, since the failure of antiviral immunity to control SARS-CoV-2 replication could underlie the hyper-inflammatory responses characterising severe cases of COVID-19 and may expose the patient to secondary viral, bacterial and fungal infections [6]. Both of our patients underwent therapy with tocilizumab, a selective interleukin-6 receptor antagonist [7] widely used in treating the Covid-19 associated "cytokine storm" in Italy. The risk of serious infections related to tocilizumab was not considered greater than that of patients receiving placebo [8]. However, suppressed T cell immune response and decreased T cells in COVID-19 patients are related to down-regulated gene expression involved in T cell activation and differentiation [9] and the inhibition of IL-6/IL-6R complex formation may trigger the dysfunction of antigen-specific CD8-positive T cells. For instance, IL-6 knockout mice were reported to be more susceptible to infection by herpes simplex virus [10].

HSV-1 reactivation may frequently occur in critically ill patients admitted to ICU [11], however, fulminant HSV-1 hepatitis is a rare disease [12]. In addition, it seems unlikely that the cumulative dosage of short-term steroids administered in patient 1 (220 mg of methylprednisolone in 5 days) could have contributed significantly to HSV-1 liver failure, but this cannot be entirely ruled out [13].

Beyond ALF, patient 2 probably also developed HSV-1 encephalitis, as suggested by the CSF positivity for HSV-1, but it was not formally proven by brain autopsy examination due to biohazard precautions in our dissection room.

Some considerations arise from our experience. Careful screening and monitoring of HSV-1 should be considered in patients with severe SARS-CoV-2 pneumonia presenting clinical manifestations suspected for an infectious aetiology, particularly when immunomodulatory therapies are used. Antiviral prophylactic or pre-emptive strategies may be advisable in COVID-19 patients with specific risk factors as pre-existing immune suppression, ICU admission and use of specific immunomodulatory agents.

In conclusion, our cases described a novel infectious risk associated with the immune dysregulation occurring in COVID-19 patients and their treatment. Further studies are urgently needed to assess the impact of COVID-19 disease and associated therapies on herpes viral infection or reactivation, and their possible impact on patients' clinical outcome and the most appropriate antiviral management measures.

ACKNOWLEDGMENTS

The authors wish to thank: Dr Geminiano Bandiera, Dr Giovanni Dr Pinelli, Dr Elisabetta Bertellini, Dr Lesley De Pietri and all the personnel of the emergency, critical and intensive care departments of the Baggiovara and Sassuolo Hospitals for the considerable management of patient number 2; Ms Ilaria Bondi and Ms Barbara Quaroni for the excellent technical expertise in performing autopsies and Dr Tiziana Salviato for the great contribution in the interpretation of the autopsy; finally, a special thank goes to all the doctors, biologists and technicians of the laboratories of Policlinico and Baggiovara hospitals, particularly Dr Alessandra Melegari, Dr Marisa Meacci, Dr Paola Pietrosevoli, Dr Tommaso Trenti, Dr Elena De Santis and Barbara Meccugni for the strenuous effort made in the analysis of all the tests required.

*Modena Covid-19 Working Group (MoCo19):

Intensive Care Unit: Massimo Girardis, Alberto Andreotti, Emanuela Biagioni, Filippo Bondi, Stefano Busani, Giovanni Chierogo, Marzia Scotti, Lucia Serio, Annamaria Ghirardini, Marco Sita, Stefano De Julis, Lara Donno, Lorenzo Dall'Ara, Fabrizio Di Salvo, Carlotta Farinelli, Laura Rinaldi, Ilaria Cavazzuti, Andrea Ghidoni, Antonio Buono, Elena Ferrari, Daniela Iseppi, Anna Maria Ardito, Irene Coloretti, Sophie Venturelli, Elena Munari, Martina Tosi, Erika Roat, Ilenia Gatto, Marco Sarti.

Immuno-Lab: Andrea Cossarizza, Caterina Bellinazzi, Rebecca Borella, Sara De Biasi, Anna De Gaetano, Lucia Fianza, Lara Gibellini, Anna Iannone, Domenico Lo Tartaro, Marco Mattioli, Milena Nasi, Annamaria Paolini, Marcello Pinti.

Infectious Disease Unit: Cristina Mussini, Giovanni Guaraldi, Marianna Meschieri, Alessandro Cozzi-Lepri, Jovana Milic, Marianna Menozzi, Erica Franceschini,

Gianluca Cuomo, Gabriella Orlando, Vanni Borghi, Antonella Santoro, Margherita Di Gaetano, Cinzia Puzzolante, Federica Carli, Andrea Bedini, Luca Corradi,

Respiratory Diseases Unit: Enrico Clini, Roberto Tonelli, Riccardo Fantini, Ivana Castaniere, Luca Tabbì, Giulia Bruzzi, Chiara Nani, Fabiana Trentacosti, Pierluigi Donatelli, Maria Rosaria Pellegrino, Linda Manicardi, Antonio Moretti, Morgana Vermi, Caterina Cerbone.

Virology and Molecular Microbiology Unit: Monica Pecorari, William Gennari, Antonella Grottola, Giulia Fregni Serpini.

Funding

No institutional or private funds were requested for this research.

Potential Conflicts of Interest

ML reports advisory board fees from MSD, Gilead, Jazz, Novartis, Sanofi, and Daiichi-Sankyo, outside the submitted work. All other authors have no potential conflicts.

REFERENCES

1. Li H, Liu L, Zhang D, Xu J, Dai H, Tang N, Su X, Cao B. SARS-CoV-2 and viral sepsis: observations and hypotheses. *Lancet*. 2020 May 9;395(10235):1517-1520.
2. Mehta P, McAuley DF, Brown M, Sanchez E, Tattersall RS, Manson JJ; HLH Across Speciality Collaboration, UK. COVID-19: consider cytokine storm syndromes and immunosuppression. *Lancet*. 2020 Mar 28;395(10229):1033-1034.
3. Guan WJ, Ni ZY, Hu Y, Liang WH, Ou CQ, He JX, Liu L, Shan H, Lei CL, Hui DSC, Du B, Li LJ, Zeng G, Yuen KY, Chen RC, Tang CL, Wang T, Chen PY, Xiang J, Li SY, Wang JL, Liang ZJ, Peng YX, Wei L, Liu Y, Hu YH, Peng P, Wang JM, Liu JY, Chen Z, Li G, Zheng ZJ, Qiu SQ, Luo J, Ye CJ, Zhu SY, Zhong NS; China Medical Treatment Expert Group for Covid-19. Clinical Characteristics of Coronavirus Disease 2019 in China. *N Engl J Med*. 2020 Apr 30;382(18):1708-1720.
4. Sun J, Aghemo A, Forner A, Valenti L. COVID-19 and liver disease. *Liver Int*. 2020 Jun;40(6):1278-1281.
5. https://www.eahp.eu/sites/default/files/covid-19_linea_guida_trattamento.jpg
6. Ritchie AJ, Singanayagam A. Immunosuppression for hyperinflammation in COVID-19: a double-edged sword? *Lancet*. 2020 Apr 4;395(10230):1111.
7. Biggioggero M, Crotti C, Becciolini A, Favalli EG. Tocilizumab in the treatment of rheumatoid arthritis: an evidence-based review and patient selection. *Drug Des Devel Ther*. 2018 Dec 19;13:57-70.
8. Singh JA, Wells GA, Christensen R, Tanjong Ghogomu E, Maxwell L, Macdonald JK, Filippini G, Skoetz N, Francis D, Lopes LC, Guyatt GH, Schmitt J, La Mantia L, Weberschock T, Roos JF, Siebert H, Hershan S, Lunn MP, Tugwell P,

- Buchbinder R. Adverse effects of biologics: a network meta-analysis and Cochrane overview. *Cochrane Database Syst Rev*. 2011 Feb 16;(2):CD008794.
9. Ouyang Y, Yin J, Wang W, Shi H, Shi Y, Xu B, Qiao L, Feng Y, Pang L, Wei F, Guo X, Jin R, Chen D. Down-regulated gene expression spectrum and immune responses changed during the disease progression in COVID-19 patients. *Clin Infect Dis*. 2020 Apr 20;ciaa462.
 10. Murphy EA, Davis JM, Brown AS, Carmichael MD, Ghaffar A, Mayer EP. Effect of IL-6 deficiency on susceptibility to HSV-1 respiratory infection and intrinsic macrophage antiviral resistance. *J Interferon Cytokine Res*. 2008;28: 589-595.
 11. Cantan B, Luyt CE, Martin-Loeches I. Influenza Infections and Emergent Viral Infections in Intensive Care Unit. *Semin Respir Crit Care Med*. 2019 Aug;40(4):488-497.
 12. Moldovan B, Mentha G, Majno P, Berney T, Morard I, Giostra E, Wildhaber BE, Van Delden C, Morel P, Toso C. Demographics and outcomes of severe herpes simplex virus hepatitis: a registry-based study. *J Hepatol*. 2011 Dec;55(6):1222-6.
 13. Stuck A, Minder CE, Frey FJ. Risk of infectious complications in patients taking glucocorticoids. *Clin Infect Dis*. 1989;11:954-963.

FIGURE LEGENDS

Figure 1. The clinical course of the two COVID-19 patients who developed acute liver failure following Herpes Simplex Virus 1 infection.

Figure 2. The nuclear reaction for Herpes Simplex Virus 1 in viable hepatocytes. Negative reaction in necrotic areas. Immunohistochemistry using HSV antibody (clone 10A3 - Cell Marque Corporation). 100x (original magnification).

Accepted Manuscript

Figure 1

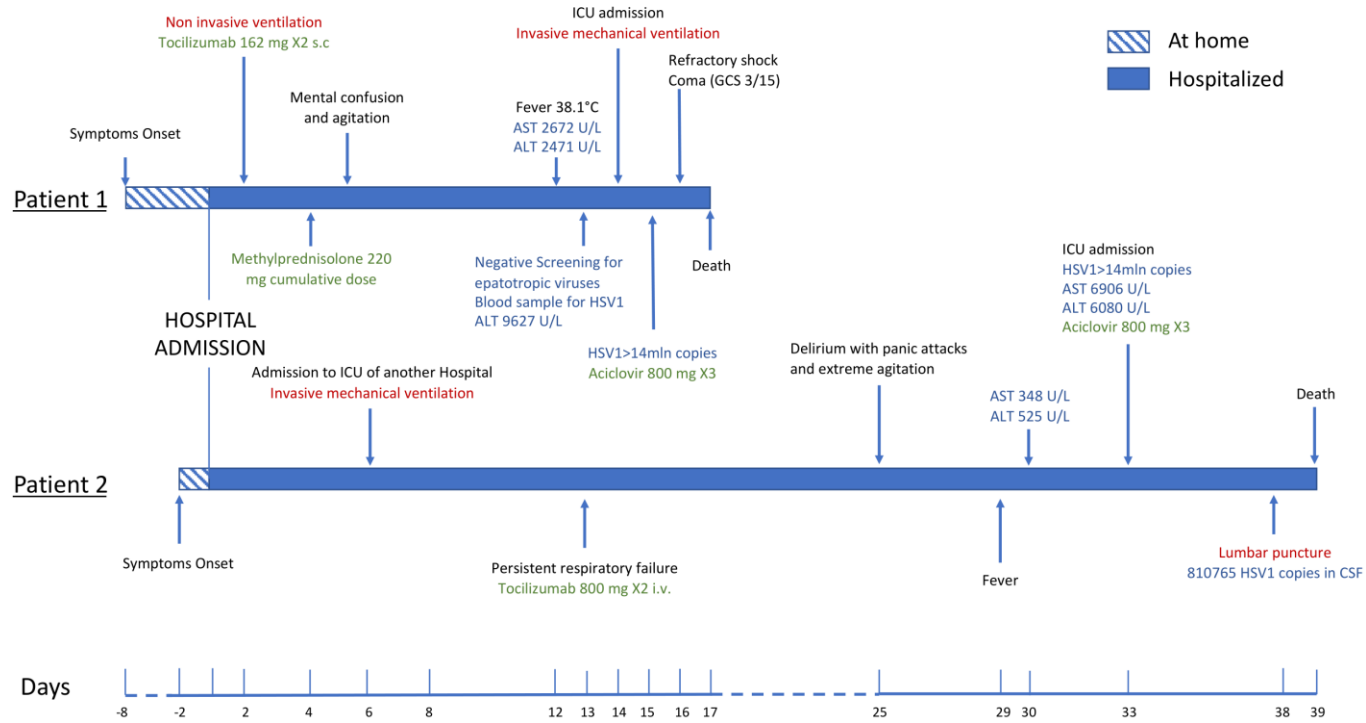


Figure 2

