

## Laparoscopic drainage of an ovarian haematoma in a Martina Franca jenny (*Equus asinus*)

AUGUSTO CARLUCCIO<sup>1</sup>, IPPOLITO DE AMICIS<sup>1</sup>, LUCIO PETRIZZI<sup>2</sup>, ROBERTA BUCCI<sup>1\*</sup>, SALVATORE PARRILLO<sup>1</sup>, VINCENZO VARASANO<sup>2</sup>, DOMENICO ROBBE<sup>1</sup>

<sup>1</sup>Department of Large Animal Reproduction, Faculty of Veterinary Medicine, University of Teramo, Loc. Piano D'Accio, Teramo (Te), Italy

<sup>2</sup>Department of Equine Surgery, Faculty of Veterinary Medicine, University of Teramo, Loc. Piano D'Accio, Teramo (Te), Italy

\*Corresponding author: [rbuccivet@gmail.com](mailto:rbuccivet@gmail.com)

**Citation:** Carluccio A, De Amicis I, Petrizzi P, Bucci R, Parrillo S, Varasano V, Robbe D (2020): Laparoscopic drainage of an ovarian haematoma in a Martina Franca jenny (*Equus asinus*). Vet Med-Czech 65, 00–00.

**Abstract:** An 11-year-old Martina Franca jenny (*Equus Asinus*), involved in a breed recovery programme organised by the Puglia Region, was referred to the University's Veterinary Teaching Hospital for a mass formation detected on the surface of the right ovary. The subject had regular oestrous cycles, but gestation loss was reported in the anamnesis. The ovarian mass was monitored by transrectal palpation and ultrasonography. In the differential diagnosis, an ovarian haematoma, a haemorrhagic anovulatory follicle and a granulosa cell tumour were hypothesised; a surgical resolution with laparoscopic access was chosen. During surgery, about 750 ml of haemorrhagic fluid was drained, confirming the suspect of the ovarian haematoma. After resolution, the jenny was inseminated, eventually giving birth to a live and viable foal. Usually, an ovarian haematoma spontaneously regresses, but, in this report, the lesion remained stable for more than two months, leading to the decision of the surgical resolution. Furthermore, to the authors' knowledge, this lesion has never been reported in donkeys.

**Keywords:** enlarged ovary; mini-invasive surgery; ovarian surgery; endangered species

Ovarian haematoma is the most common cause of unilateral ovarian enlargement (McCue and McKinnon 2011) and is due to excessive bleeding after ovulation (Montavon 1994). In rare cases, it can reach up to 40–70 cm in diameter (Stradaoli et al. 1999). This abnormality usually does not require treatment as, in normal circumstances, it regresses in several weeks and the affected ovary returns to a normal size and function (McCue 1998). Rarely, a haematoma may destroy the ovarian germinal tissue (McCue 1998) and, in literature, one case of haemoperitoneum consequent to bilateral ruptured haematomas has been described (Pusterla et al. 2005).

Martina Franca donkeys (*Equus Asinus*) are an Italian native breed which originated in Puglia (South Italy); nowadays, it is considered an endangered species by the FAO (Food and Agricultural Organization of the United Nations), thus, in recent years, the Puglia Agricultural Department has implemented a project to help recover this autochthonous breed.

To the authors' knowledge, there are few cases of ovarian haematoma described in literature and none of them report a surgical resolution. In addition, ovarian haematoma has not been reported, so far, in an asinus species.

Supported by Regione Puglia, Italy (Protocol A030, No. 54817, 01/07/16).

## Case presentation

An 11-year-old Martina Franca jenny was referred to the Large Animals Reproduction Service of the University of Teramo. The subject had been approved for reproduction purposes and belongs to a breed recovery programme; hence, the recovery of the jenny's fertility was essential for the preservation of the Martina Franca donkey breed.

The reason for the admission was a spontaneous gestation loss on the 228<sup>th</sup> day of gestation during the current breeding season. The reproductive anamnesis reported regular oestrous cycles and an at-term-birth of a live and viable foal that took place two years previously.

The clinical examination result was within normal limits with a good physical condition of the jenny. The complete gynaecological examination (Zent and Steiner 2011) did not detect any alteration of the external genitalia.

The transrectal palpation (Bowman 2011) revealed that the uterine body and horns were normal in size, tone and consistency with no alteration. The left ovary was found to be of normal size (about 3 cm in diameter), however, the palpation of the right ovary revealed a severely enlarged ovary (cross sectional diameter over 10 cm) with a smooth surface.

An ultrasonographic examination (GE Logiq Book XP; Scil Vet, Treviglio (BG), Italy) of the reproductive tract was performed to complete the routine gynaecological investigation of the jenny (Carnevale and Olsen 2011).

A 7.5 MHz linear probe was used to perform the transrectal ultrasonography: the uterine body and the horns and the left ovary were normal for the breeding season. The right ovary was only partially visible, showing an anechoic structure with a central hyperechoic texture.

To complete the evaluation on the right ovary, a transabdominal ultrasonography was performed. A 3.5 MHz convex probe was placed on the right paralumbar fossa: cranially to the ovarian surface, a neof ormation was found. It appeared as an anechoic rounded structure, of approximately 14 cm in diameter, with a central hyperechoic area (Figure 1). The left ovary showed small follicles (less than 2 cm), one follicle of about 2.5 cm and a corpus luteum at the transabdominal examination.

Blood samples were collected to perform a haematologic and biochemical analysis. The results are

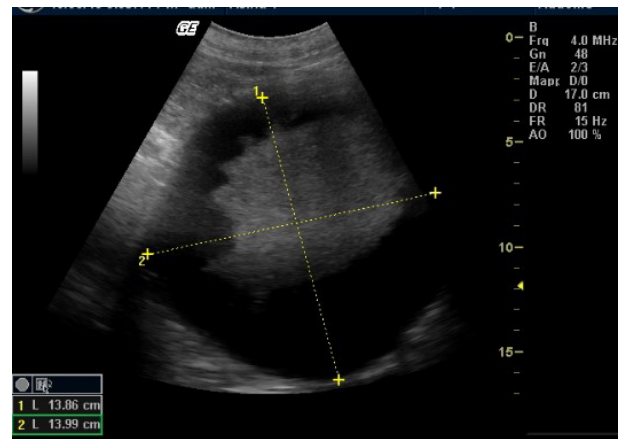


Figure 1. Neof ormation on the surface of the right ovary confirmed by the transabdominal ultrasound

shown in Table 1 and are within the normal limits for the species (Gloria et al. 2018).

To confirm the regularity of the oestrous cycle, the patient was clinically monitored for two months.

Blood samples were collected every 3 days for 21 days for the progesterone measurements (Contri et al. 2014). The hormone detection was performed by a radioimmunoassay and the results are shown in Figure 2. This finding confirmed the jenny's regular cyclicity. In addition, the physical and ultrasonographic characteristics of the ovarian formation did not change during the observation period.

## Treatment and follow up

The lesion that persisted for more than two months led to the decision of a surgical resolution with fluid drainage. The procedure took the risks of rupture of the haematoma (Pusterla et al. 2005) and destruction of the germinal tissue (McCue 1998) under consideration.

A standing laparoscopic procedure was chosen as its advantages are well known and include minor surgical trauma and direct visualisation of the abdominal viscera (Petrizzi et al. 2020).

The jenny was prepared for surgery with a 24-hour fast; water was not restricted. The patient was premedicated with acepromazine (50 µg/kg intravenously, i.v.) and sedated with detomidine (10 µg/kg i.v.) and butorphanol (40 µg/kg i.v.). During surgery, a continuous rate infusion of detomidine (0.16 µg/kg) was administered.

Table 1. Blood count and biochemical examination performed at the time of admission

Blood count			Biochemical blood analysis		
Value (units)	results	ranges	Value (units)	results	ranges
RBC × 10 <sup>6</sup> (ml)	6.67	5.5–12.5	AST (IU/l)	127	60–280
Hb (g/l)	134.2	110–190	TRI (mg/l)	1 330	560–1 400
Hct (%)	32.71	31.5–50.5	TP	6.8	5.9–7.3
MCV (fl)	48.8	37.9–58.0	AMY (IU/l)	2	1.0–8.0
MCH (Pg)	20.11	10.0–18.0	γ-GT (IU/l)	18.2	3.6–20.60
MCHC (Pg)	41.03	31.0–37.0	ALT (IU/l)	3	90–270
RDW (%)	17.38	16.5–24.8	ALB (g/l)	36	29–37
PLT × 10 <sup>3</sup> (ml)	360	100–600	BUN (mg/l)	200	150–400
MPV	11	5.3–7.1	CK (IU/l)	56	90–270
PDW	58.37		CHOL (mg/l)	780	450–850
PCT	0.4		GLU (mg/l)	900	800–1 200
			TBIL (mg/l)	1	9.0–26
			P (mg/ l)	30	17.5–49
			CREA (mg/l)	11	9.0–15
			ALP (IU/l)	89	85–190
			Ca (mg/l)	108	113–135
			UA (mg/l)	2	1.0–4.0

ALB = albumin; ALP = alkaline phosphatase; ALT = alanine aminotransferase; AMY = amylase; AST = aspartate aminotransferase; BUN = urea nitrogen; Ca = calcium; CHOL = cholesterol; CK = creatinine kinase; CREA = creatinine; γ-GT = γ-glutamyltranspeptidase; GLU = glucose; Hb = haemoglobin; Hct = haematocrit; MCH = mean corpuscular haemoglobin; MCHC = mean corpuscular haemoglobin concentration; MCV = mean corpuscular volume; MPV = mean platelet volume; P = phosphorus; PCT = plateletcrit; PDW = platelet distribution width; PLT = platelets; RBC = red blood cells; RDW = red blood cell distribution width; TBIL = total bilirubin; TP = total protein; TRI = triglycerides; UA = uric acid

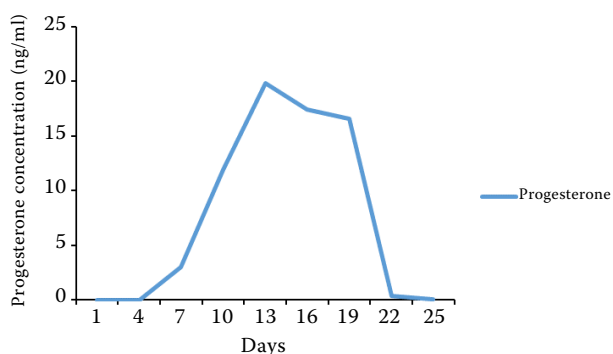


Figure 2. Progesterone trend during the observation period. This finding confirmed a regular oestrus cycle

Just before surgery, a Foley urinary catheter was introduced, and a rectal examination was performed to evacuate the rectum. Then, both of the paralumbar fossae were prepared for aseptic surgery, as described by Petrizzi et al. (2020). A preoperative broad-spectrum antibiotic therapy was administered (20 mg/kg of ampicillin and 8 mg/kg of gentami-

cin i.v.), flunixin meglumine was given at 1.1 mg/kg i.v., and then b.i.d. (*bis in die*) for three days.

A bilateral preparation was chosen in case a bilateral approach would be needed. Starting on the left flank, an infiltration of 20 ml of 2% lidocaine solution for each of the intended portals; then a central portal halfway between the horizontal line between the last rib and the ventral tuber coxae was created by a skin sharp incision for about 1 cm, and deep penetration with a blunt trocar (10 mm diameter) inserted a 30 cm long cannula. After creating a pneumoperitoneum to a maximum pressure of 15 mm Hg, two other portals, one dorsal and one ventral were created with the same method, three fingers apart from each other, on the same vertical line. The dorsal portal was used as the optical portal, the distal as an instrumental portal for grasping the ovary, and the central portal to insert the needle (a 5 mm diameter laparoscopic injection cannula with a 1.2 mm diameter needle) for the haematoma aspiration.

The reproductive tract anatomy showed no alterations except for the right ovarian mass: the right ovary showed an enlargement from which 750 ml of haemorrhagic fluid was drained through a laparoscopic needle connected to an aspirating system (Figure 3A and 3B). At the end of the procedure, the abdomen was deflated and the portals were sutured with skin staples; just the skin was sutured. After surgery, regular ultrasound checks were performed, showing a significant hematoma volume reduction. No other medical treatment was given.

Microscopically evaluated, the lesion mainly consisted of erythrocytes debris, with deposition of haemosiderin in the cytoplasm of the macrophages. A surrounding fibrotic reaction was also observed. The cytopathological report confirmed the diagnosis of an ovarian hematoma.

The following year, during the breeding season, the jenny was monitored and showed regular oestrous cycles. Both ovaries were easily detectable at the transrectal examination and ultrasound. Their characteristics were normal in size and in follicular dynamics, in fact, follicular waves were present on both the transrectal examination and ultrasound.

The oestrous behaviour was revealed using a teaser stallion; when the jenny showed external oestrus signs, close ultrasonographic monitoring was started. Artificial insemination was performed when the dominant follicle exceeded 35 mm in diameter and fresh semen from a stallion of proven fertility was used.

An ultrasonographic pregnancy diagnosis was performed 14 days after ovulation and confirmed on the 25<sup>th</sup> day, detecting a foetal heartbeat.

The jenny was housed at the Veterinary University Teaching Farm throughout the pregnancy and delivered a live and viable foal after 361 days of gestation.

### Differential diagnosis

Granulosa cell tumours, haemorrhagic anovulatory follicles, ovarian haematomas, teratomas and abscesses are the most common causes of ovarian enlargement (Ramirez et al. 1999; Lefebvre et al. 2005; Schlafer 2011). Ultrasonographic features, oestrous cycle characteristics and behavioural observation are used to evaluate ovarian abnormalities and allow for the identification of the most probable pathology (McCue et al. 1998).

A granulosa cell tumour frequently produces testosterone and inhibin, causing aggressive or stallion-like behaviour and an anoestrus or an irregular oestrous cycle (Card 2011). In addition, a granulosa cell tumour often shows a multicystic or honeycomb structure at the ultrasound examination (Card 2011; McCue and McKinnon 2011).

During the two months of clinical observation, the jenny never showed any behavioural changes; the progesterone measurement confirmed the regularity of the oestrous cycle. These findings allowed one to rule out a granulosa cell tumour,

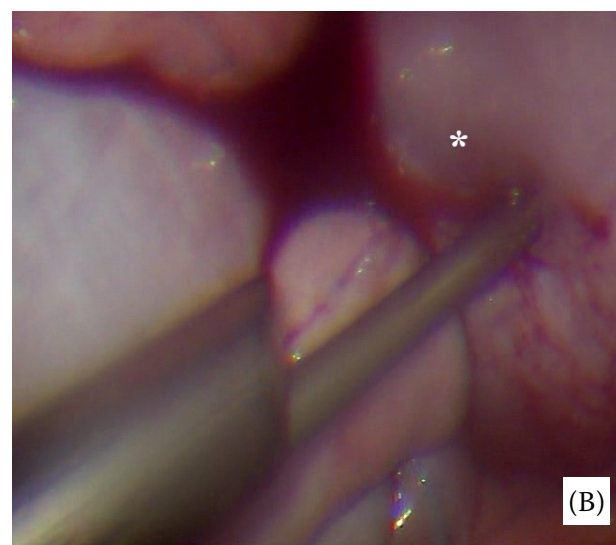
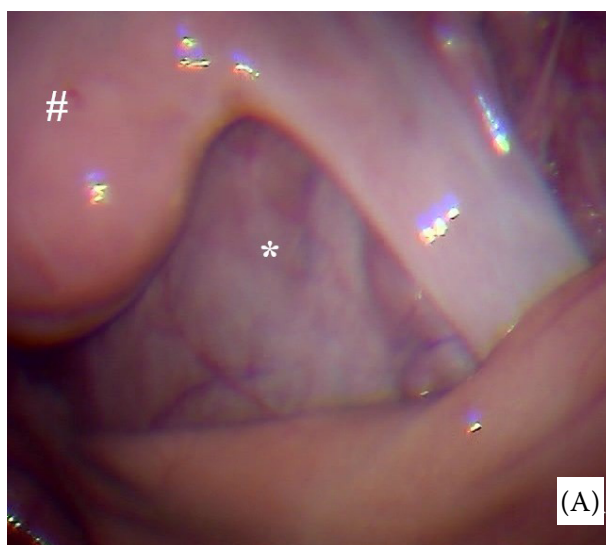


Figure 3. (A) direct laparoscopic visualisation of the ovarian haematoma; (B) laparoscopic drainage #uterus; \*ovarian haematoma

without dosing the testosterone, inhibin or anti-Müllerian hormone (Ball et al. 2008).

Haemorrhagic anovulatory follicles derive from an altered ovulation mechanism and, in affected mares, because of the absence of a corpus luteum, the progesterone levels do not exceed the value of 1 ng/ml (Ghinter et al. 2007). The ultrasonographic features are similar to an ovarian haematoma and treatments with prostaglandins have been reported (Schlafer 2011). Like the previous example, the progesterone serum concentration (Figure 3) allowed the authors to rule out the hypothesis of a haemorrhagic anovulatory follicle and to avoid the use of unnecessary treatments. Finally, an ovarian haematoma has the ultrasonographic characteristics of an enlarged corpus haemorrhagicum (McCue and McKinnon 2011) which normally regresses after several weeks, even without any treatment (McCue 1998). Furthermore, the mare's cyclicity usually is not affected (McCue 1998).

The ultrasonographic findings, the jenny's regular cyclicity and the behaviour all confirmed the hypothesis of an ovarian haematoma.

## DISCUSSION AND CONCLUSIONS

Even if an ovarian haematoma is a frequent cause of ovarian enlargement (McCue 1998; McCue and McKinnon 2011), few cases are reported in the literature and none of these report a surgical resolution. In 2003, Curtin reported a case of an 11-year-old mare with an ovarian haematoma. The mare was treated with progesterone to suppress the oestrus cycle and the spontaneous regression of the lesion was awaited. Indeed, this neof ormation is reported to spontaneously regress in several weeks (McCue 1998; McCue and McKinnon 2011) while not affecting the cyclicity. Nevertheless, these lesions may rupture spontaneously, causing bleeding as reported in one case in a review of cases of acute haemoperitoneum in horses (Pusterla et al. 2005). This is an extremely rare occurrence, which, however, suggests not to underestimate the lesion, but to closely monitor its clinical course.

The persistence and large size of the ovarian haematoma led the authors to choose a surgical resolution. Specifically, a laparoscopic approach, similar to the one used for a laparoscopic ovariectomy, demonstrated to be effective in treating the ovarian haematoma. To the author's knowledge, it is

the first time that the laparoscopic aspiration of an ovarian haematoma has been described in literature. This procedure was demonstrated to be safe for the jenny and not to affect the fertility, as proved by the birth of a live and viable foal.

## Acknowledgement

We thank to Bonavita Alessandro, Di Paolo Lelio and Peli Renato for their valuable technical and laboratory support.

## Conflict of interest

The authors declare no conflict of interest.

## REFERENCES

- Ball BA, Conley AJ, MacLaughlin DT, Grundy SA, Sabour K, Liu IK. Expression of anti-Müllerian hormone (AMH) in equine granulosa-cell tumors and in normal equine ovaries. *Theriogenology*. 2008 Oct 1;70(6):968-77.
- Bowman Jr TR. Direct rectal palpation. In: McKinnon AO, Squires EL, Vaala EW, Varner DD, editors. *Equine reproduction*. 2<sup>nd</sup> ed. Hoboken: John Wiley & Sons; 2011.
- Card CE. Ovarian neoplasia. In: McKinnon AO, Squires EL, Vaala EW, Varner DD, editors. *Equine reproduction*. 2<sup>nd</sup> ed. Hoboken: John Wiley & Sons; 2011.
- Carnevale EM, Olsen LM. Normal anatomy. In: McKinnon AO, Squires EL, Vaala EW, Varner DD, editors. *Equine reproduction*. 2<sup>nd</sup> ed. Hoboken: John Wiley & Sons; 2011.
- Contri A, Robbe D, Gloria A, De Amicis I, Veronesi MC, Carluccio A. Effect of the season on some aspects of the estrous cycle in Martina Franca donkey. *Theriogenology*. 2014 Mar 15;81(5):657-61.
- Curtin DJ. Ovarian hematoma in an 11-year-old Thoroughbred-Hanoverian mare. *Can Vet J*. 2003 Jul;44(7):589.
- Ginther OJ, Gastal EL, Gastal MO, Beg MA. Incidence, endocrinology, vascularity, and morphology of haemorrhagic anovulatory follicles in mares. *J Equine Vet Sci*. 2007 Mar 1;27(3):130-9.
- Gloria A, Veronesi MC, Carluccio R, Parrillo S, De Amicis I, Contri A. Biochemical blood analysis along pregnancy in Martina Franca jennies. *Theriogenology*. 2018 Jul 15; 115:84-9.
- Lefebvre R, Theoret C, Dore M, Girard C, Laverty S, Vaillancourt D. Ovarian teratoma and endometritis in a mare. *Can Vet J*. 2005 Nov;46(11):1029-33.

<https://doi.org/10.17221/29/2020-VETMED>

- McCue PM, McKinnon AO. Ovarian abnormalities. In: McKinnon AO, Squires EL, Vaala EW, Varner DD, editors. Equine reproduction. 2<sup>nd</sup> ed. Hoboken: John Wiley & Sons; 2011.
- McCue PM. Review of ovarian abnormalities in the mare. In: Proceedings of the Annual Convention of the AAEP. 1998 Dec;44(1):125-33.
- Montavon S. Ultrasonographie de la pathologie ovarienne chez la jument: Revue pour le praticien [Ultrasonography of ovarian pathology in mares: Review for the practitioner]. Schweizer Archiv fur Tierheilkunde. 1994 Sep;136 (9):285-91. French.
- Petruzzi L, Guerri G, Stratico P, Cuomo A, Vullo C, De Amicis I, Robbe D, Varasano V. Laparoscopic ovariectomy in standing mule mares. J Equine Vet Sci. 2020 Jan;84:102857.
- Pusterla N, Fecteau ME, Madigan JE, Wilson WD, Magdesian KG. Acute hemoperitoneum in horses: A review of 19 cases (1992–2003). J Vet Intern Med. 2005;19(3):344-7.
- Ramirez S, Sedrish SA, Paccamonti DL, French DD. Ultrasound as an aid for diagnosis of ovarian abscesses in two mares. Vet Radiol Ultrasound. 1999 Mar-Apr;40(2):165-8.
- Schlafer DH. Non-neoplastic abnormalities. In: McKinnon AO, Squires EL, Vaala EW, Varner DD, editors. Equine reproduction. 2<sup>nd</sup> ed. Hoboken: John Wiley & Sons; 2011.
- Stradaoli G, Zelli R, Mazzarelli FA, Sylla L, Monaci M. L'approccio diagnostico all'aumento di volume dell'ovaio della cavalla [The diagnostic approach to increasing the ovary volume of the mare]. Prax Vet. 1999;10(1):3-8. Italian.
- Zent WW, Steiner J. Vaginal examination. In: McKinnon AO, Squires EL, Vaala EW, Varner DD, editors. Equine reproduction. 2<sup>nd</sup> ed. Hoboken: John Wiley & Sons; 2011.

Received: February 4, 2020

Accepted: June 18, 2020