

CLINICAL QUIZ

Vein of Galen Malformation

REYNU R¹, KUMAR R¹, KOSAI NR¹, FARIZAL F¹, SHUHAILI MA¹,
RAZMAN J¹, SHAHIZON AMM²

¹Department of Surgery and ²Department of Radiology, Universiti Kebangsaan Malaysia Medical Centre, Jalan Yaacob Latif, Bandar Tun Razak, 56000 Cheras, Kuala Lumpur, Malaysia.

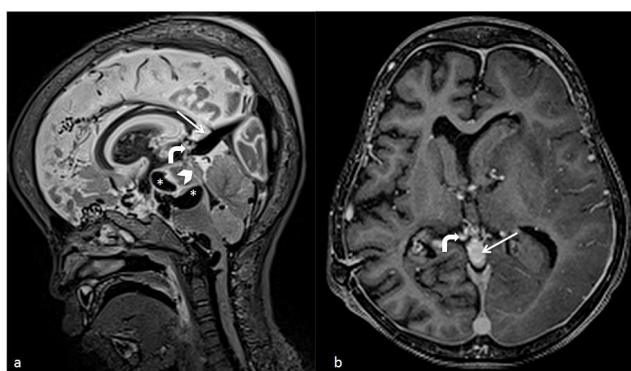


Figure 1: MRI of the brain in sagittal T2WI and contrast-enhanced T1 MPRAGE demonstrate multiple serpiginous flow voids (star and bent arrow) representing dilated venous channels.

Abnormal vessels (bent arrow) are seen draining into a dilated vein (thin arrow), which in turn drains into the superior sagittal sinus. Narrowing of aqueduct of sylvius is marked with an arrowhead.

QUESTION

A 4-year-old child was brought to the Emergency Department with generalized tonic-clonic seizures. Right hemiparesis and unequal pupils were noted during examination. Computed Tomography of brain revealed acute subdural hemorrhage for which an emergency craniotomy and evacuation of clot was performed. Intraoperative finding of abnormal vessels prompted a need to revisit his past surgical history. Three years ago, he was diagnosed with hydrocephalus secondary to cerebral aqueduct stenosis, which eventually led to the insertion of a ventriculo-peritoneal shunt. Since then, he has suffered from global developmental delay and infrequent episodes of epilepsy. One month prior to this recent presentation, he

Address for correspondence and reprint requests: Dr. Reynu Rajan, Department of Surgery, Faculty of Medicine, Universiti Kebangsaan Malaysia Medical Centre, Jalan Yaacob Latif, Bandar Tun Razak, 56000 Cheras, Kuala Lumpur, Malaysia. Tel: +603-91456202 Fax: +603-91456684 Email: dr.reynu@gmail.com

was treated for varicella zoster infection and discharged well, five days later. The initial Magnetic Resonance Imaging of brain taken three years earlier is also shown in Figure 1.

What should be the more appropriate cause of hydrocephalus in this patient?

Is there a correlation between varicella zoster infection and the current presentation of acute subdural hemorrhage?

ANSWER AND DISCUSSION:

Vein of Galen named after the Roman Physician Galen of Pergamon is formed by the union of basal veins of Rosenthal and the internal cerebral veins (de Tribolet 2009). Vein of Galen malformation (VGAM) accounts for 30% of the cerebral vascular malformation in the pediatric population, and is caused by teratogenic insult occurring between the 6th to 11th week of intrauterine life. The failure of median prosencephalic vein to obliterate leads to aneurysmal dilatation of vein of Galen and arterio-venous shunting of blood (Gailloud et al. 2005). The diagnosis is often delayed due to non-specific clinical presentation and low index of suspicion. Cardiac failure is the most common clinical presentation followed by hydrocephalus and intracranial hemorrhage (Suh et al. 2001). Third trimester ultrasonographic evidence of dilated median prosencephalic vein or cardiomegaly is suggestive of VGAM. Digital subtraction angiography remains the gold standard radiological investigation. It is used to confirm diagnosis and differentiate aneurysmal dilatation from arterio-venous malformation. Transarterial occlusion of feeder vessels have dramatically improved prognosis while reducing surgery related mortality. Seizures and parenchymal damage is a sign of poor functional outcome. Once left untreated, the mortality rate is almost 100% (Gupta et al. 2004). To the best of our knowledge, there is no documented correlation between VGAM and varicella zoster infection. However, varicella zoster-induced vasculitis presenting as intracranial haemorrhage and stroke have been reported in adults. The exact pathophysiology remains unclear but few suggest direct viral invasion into the endothelium as a plausible cause for inflammation, stenosis and occlusion (Jain et al. 2003).

REFERENCES

- de Tribolet, N. 2009. MJ Alexander, RF Spetzler, Pediatric Neurovascular Disease. Surgical, Endovascular, and Medical Management. *Acta Neurochir* 151(2): 177.
- Gailloud, P., O'Riordan, D.P., Burger, I., Levrier, O., Jallo, G., Tamargo, R.J., Murphy, K.J., Lehmann, C.U. 2005. Diagnosis and management of vein of Galen aneurysmal malformations. *J Perinatol* 25(8):542-51
- Gupta, A.K., Varma D.R. 2004. Vein of Galen Malformations: Review. *Neurology India* (52)1: 43-53
- Jain, R., Deveikis, J., Hickenbottom, S., Mukherji, S.K. 2003. Varicella-zoster vasculitis presenting with intracranial hemorrhage. *AJNR Am J Neuroradiol* 24(5):971-4.
- Suh, D.C., Alvarez, H., Bhattacharya, J.J., Rodesch, G., Lasjaunias, P.L. 2001. Intracranial haemorrhage within the first two years of life. *Acta Neurochir (Wien)*. 143(10):997-1004.