

ORIGINAL ARTICLE

Morphology of Nutrient Foramina in Human Metatarsals and Their Clinical Importance

ANAMIKA K¹, ABHISHEK PS², ANUJ J³, MURLIMANJU BV¹, DIVYA P¹, LATHA VP¹, VASUDHA VS¹, CHITRA PR⁴, ASHWIN RR¹, TERESA J¹, PRASHANTH KU⁴

¹Department of Anatomy, Kasturba Medical College, 575004 Mangalore, Manipal University, Manipal, Udupi District, Karnataka, India.

²Department of Anatomy, Tribhuvan University, Gandaki Medical College, Lekhnath, 33700 Kaski, Pokhara, Nepal.

³Department of Anatomy, U.P. Rural Institute of Medical Sciences and Research, 206301 Saifai, Etawah, Uttar Pradesh, India.

⁴Department of Anatomy, A.J. Institute of Medical Sciences, Kuntikana, 575006 Mangalore, Karnataka, India.

ABSTRAK

Mercu tanda anatomi foramen nutrien penting dalam prosedur pembinaan semula kaki yang melibatkan penggunaan tulang metatarsal. Objektif kajian ialah untuk mengkaji morfologi foramina nutrien di tulang metatarsal dan mendapatkan indeks foramina. Kajian ini melibatkan 271 metatarsal manusia yang bukan berpasangan. Umur dan jantina metatarsal tidak diketahui. Foramina nutrien setiap tulang diperiksa untuk menentukan topografi dan nombor. Pengindeksan foramina dilakukan menggunakan formula Hughes. Morphometri kajian ini telah dijalankan dengan penggunaan 'Vernier caliper' digital. Hasil pemerhatian mendapati 79.3% daripada metatarsal mempunyai foramen nutrien tunggal, 9.2% mempunyai dua foramen, 1.1% mempunyai tiga foramen dan 10.4% metatarsal tidak ada foramen. Min indeks foramina daripada metatarsal pertama, metatarsal kedua, metatarsal ketiga, metatarsal keempat dan metatarsal kelima ialah 65.3, 43.6, 44.4, 45.3 dan 47.5 masing-masing mengikut turutan. Dapat diperhatikan bahawa kebanyakan metatarsal mempunyai foramen nutrien tunggal. Lokasi foramen nutrien berubah dari metatarsal 1 hingga 5. Foramina metatarsal 1 dan metatarsal 5 diperhatikan di sebelah sisi mereka dan pada metatarsal yang lain; ia lazim diperhatikan di permukaan medial. Pengagihan morfologi tentang foramina nutrien adalah amat diperlukan dalam sesetengah pembedahan seperti penggunaan tulang metatarsal dalam pembinaan semula kaki. Data morfologi juga amat penting dalam pembedahan plastik seperti kes operasi mikrovaskular tisu tulang.

Address for correspondence and reprint requests: Murlimanju BV, Department of Anatomy, Kasturba Medical College, Manipal University, Mangalore – 575004, India. Tel: 91824 2211746 Fax: 91824 2421283 Email: flutemist@gmail.com

Kata kunci: indeks foramina, metatarsal, morfologi, foramen nutrien, topografi

ABSTRACT

The anatomical landmark of the nutrient foramen is essential in foot reconstruction procedures which involve the utilization of the metatarsal bones. The objectives were to study the morphology of the nutrient foramina in metatarsals and to figure out their foramina index. The present study included 271 unpaired, human metatarsals. The age and sex of the metatarsals were unknown. Nutrient foramina of each bone were grossly examined with respect to their topography and number. The indexing of the foramina was performed with the formula of Hughes. The morphometry of the present study was performed with the application of digital Vernier caliper. It was observed that 79.3% of metatarsals had single nutrient foramen, 9.2% had double foramina, 1.1% exhibited three foramina and in 10.4% of metatarsals, there was no foramen. The mean index of the foramina of 1st metatarsal, 2nd metatarsal, 3rd metatarsal, 4th metatarsal and 5th metatarsal were 65.3, 43.6, 44.4, 45.3 and 47.5, respectively. It was observed that most of the metatarsals had single nutrient foramen. The locations of the nutrient foramen varied from 1st to 5th metatarsals. In the 1st metatarsal and 2nd metatarsals, the foramina were observed at their lateral side and in the rest; they were commonly observed at the medial surface. The morphological distribution of nutrient foramina is important for surgeries involving utilization of metatarsal bones in the foot reconstruction. The morphological data is also beneficial for plastic surgery in case of bone graft microvascular operations.

Keywords: foraminal index, metatarsal, morphology, nutrient foramen, topography

INTRODUCTION

The metatarsals consist of five bones numbered from medial to lateral side resemble the metacarpals of the hand, possess a head distally, a shaft and a base proximally (Standring 2005). The first metatarsal bone is large, strong and plays an important role in supporting the weight of the body. The fifth metatarsal has a prominent tubercle on its base which can be easily palpated along the lateral border of the foot. The tubercle gives attachment to the peroneus brevis tendon (Snell

2007). The metatarsals are classified as miniature or 'short' long bones; they are peculiar in having a single epiphysis at one end only (Patake & Mysorekar 1977). Typically, epiphyses appear for the base of the first metatarsal and for the heads in the remaining metatarsals (Patake & Mysorekar 1977).

The metatarsals are basically supplied by the nutrient artery. Nutrient artery being the source of nutritional supply plays an important role in fracture healing and union (Shrimankar et al. 2010). The anatomical knowledge regarding nutrient artery and nutrient

foramen is vital to avoid complications like gangrene and necrosis. The operating surgeon should preserve the arterial supply in free vascularized bone grafts, which is essential for the survival of osteocytes and osteoblasts (Green 1988). The knowledge about nutrient foramina is important in surgical procedures like utilization of metatarsal bones in the foot reconstruction. Singh (1960), while studying the variations in the articular facets of metatarsal bones, made some observations on their nutrient foramina. The nutrient foramina of long bones were studied by few authors (Collipal et al. 2007; Kizilkanat et al. 2007; Murlimanju et al. 2011; Prashanth et al. 2011), however the studies about the nutrient foramina in metatarsals are extremely rare. In the present study, the objectives were to observe the morphological features and location of nutrient foramen of human metatarsal bones and to figure out the index of the foramen.

MATERIALS AND METHODS

The present investigation included 271 human metatarsal bones, among which 54 were first metatarsals, 53 were second, 54 were third, 57 fourth and 53 fifth metatarsal bones. The metatarsals were unpaired, the gender and age of them were not known. The metatarsals were collected from the osteology section of department of anatomy at our institution. The present study had the approval of our institutional review board. The metatarsals, which were pathological, were not included in the present investigation. The topography, number and the direction

of the nutrient foramen were observed in each metacarpal bone. Only, the diaphysial nutrient foramina were studied. The nutrient foramina over the diaphysis have been described to provide the passage for the main nutrient artery and the foramina at the epiphysis were known as the vascular foramina. The vascular foramina usually transmit smaller arteries and veins. The epiphyseal foramina were not considered in the present study. The macroscopic observation in the present study was performed and recorded by the same single person. This was done to prevent the inter observer variation. The observations were done with the use of magnifying lens. A clearly seen groove which is leading into a hole and which has a raised edge at its commencement is considered as a nutrient foramen in each bone (Figure 1). The patency of the foramen is confirmed after passing a 24 gauge needle in each bone. Foramen was considered for the present study only if the 24 gauge needle enters the medullary cavity, of the metatarsal bone. The topography and number of the foramina with respect to the border and surface of the metatarsal bone was examined. The number of nutrient foramen is important, because the multiple foramina transmit the accessory nutrient arteries. Their knowledge is important to the operating surgeon to prevent the complication. The number of epiphyseal foramina was not considered in the present study, because they are not the main source of blood supply to the bone. The size of the foramen may be proportional to the diameter of the lumen of the bone. However, this was not considered in

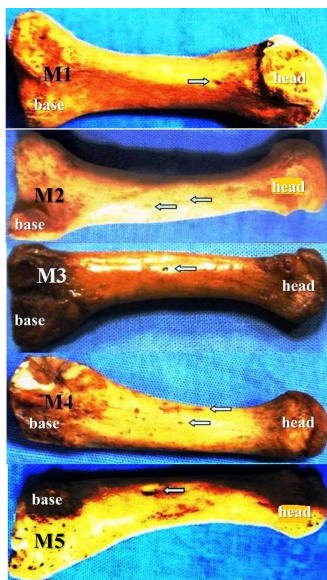


Figure 1: Photograph of the metatarsal bones showing the nutrient foramina (M1: first metatarsal with single foramen; M2: second metatarsal, arrow marks showing the double foramina; M3: third metatarsal, arrow mark showing the single foramen; M4: fourth metatarsal, arrow marks showing the double foramina; M5: fifth metatarsal bone, arrows mark showing the single nutrient foramen).

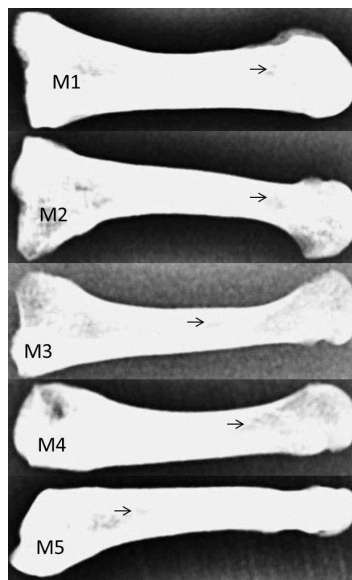


Figure 2: The radiographic film showing metatarsals and their nutrient foramina (arrow mark).

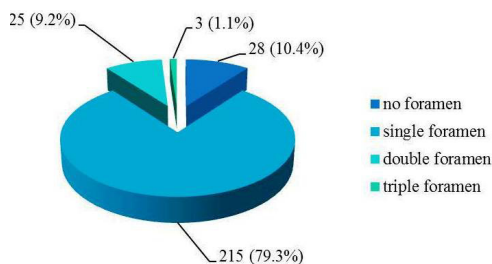


Figure 3: Morphological distribution of the nutrient foramina of metatarsal bones (n=271).

the present study. The minute arterioles which connect the Volkmann’s and Haversian canals from the periosteum were also not considered, as it was difficult to interpret them in the dried bones. They offer a minimal quantity of blood supply to the bone.

The foramen index (F.I.) of each metatarsal was determined by using the formula given by Hughes (1952). As per this formula, the distance of the nutrient foramen from the proximal end of the metatarsal bone (D) was divided by the total length of the metatarsal bone (L) and the value obtained was multiplied by one hundred:

$$F.I. = D / L \times 100$$

The total length of metatarsal bone was determined from its base to head after using a digital vernier caliper. The F.I. was determined for all metatarsal bones, which figured out the location of nutrient foramen. The morphometric data was tabulated, each metatarsal was split into five equal parts and the location of foramen was analyzed topographically. Some of the metatarsals of the present study were

Table 1: The morphological and topographic distribution of the nutrient foramina in the first metatarsal bone (n=54)

No. of Foramina	Right Side	Left Side	Total	%	M	L	PR
0	1	1	2	4%	-	-	-
1	16	22	38	70%	-	29	9
2	6	6	12	22%	-	10	2
3	1	1	2	4%	-	2	-
Total	24	30	54	100%	-	41	11

(M – medial surface, L – lateral surface, PR – plantar ridge)

Table 2: The morphological and topographic distribution of the nutrient foramina in the second metatarsal bone (n=53)

No. of Foramina	Right Side	Left Side	Total	%	M	L	PR
0	3	4	7	13%	-	-	-
1	20	24	44	83%	12	30	2
2	2	-	2	4%	-	2	-
Total	25	28	53	100%	12	32	2

(M – medial surface, L – lateral surface, PR – plantar ridge)

Table 3: The morphological and topographic distribution of the nutrient foramina in the third metatarsal bone (n=54)

No. of Foramina	Right Side	Left Side	Total	%	M	L	PR
0	2	5	7	13%	-	-	-
1	24	21	45	83%	28	13	4
2	2	-	2	4%	1	1	-
Total	28	26	54	100%	29	14	4

(M – medial surface, L – lateral surface, PR – plantar ridge)

radiographed (Figure 2) to observe the foramen radiologically. The films were taken using the diagnostic X-ray imaging system. The X-ray tubes were operated at approximately 60 kiloVolt peak (kVp) and 10 milliAmpere second (mAs) at a 100 cm source to image receptor distance (SID).

RESULTS

The present study observed that, among 271 metatarsal bones, 79.3% had single foramen, 9.2% had two

foramina, 1.1% of had three foramina and in 10.4% of metatarsals, the foramen was not observed. The morphological distribution of the nutrient foramina of the present study was shown in Figure 3.

In the present study, 70.4% of first metatarsals had a solitary nutrient foramen. The dual foramina were found in 22.2% of cases and the triple foramina were observed in 3.7% of cases. The foramen was absent in 3.7% of first metatarsal bones. The foramina were on the lateral surface in 41 metatarsals and over the plantar

Table 4: The morphological and topographic distribution of the nutrient foramina in the fourth metatarsal bone (n=57)

No. of Foramina	Right Side	Left Side	Total	%	M	L	PR
0	3	1	4	7%	-	-	-
1	19	25	44	78%	24	19	1
2	5	3	8	14%	7	1	-
3	1	-	1	1%	-	1	-
Total	28	29	57	100%	31	21	1

(M – medial surface, L – lateral surface, PR – plantar ridge)

Table 5: The morphological and topographic distribution of the nutrient foramina in the fifth metatarsal bone (n=53)

No. of Foramina	Right Side	Left Side	Total	%	M	L	PR
0	6	2	8	15%	-	-	-
1	18	26	44	84%	8	-	16
2	-	1	1	1%	-	-	1
Total	24	29	53	100%	8	-	17

(M – medial surface, L – lateral surface, PR – plantar ridge)

Table 6: The topographic distribution of the nutrient foramina of the metatarsus (n=271) based on the foraminal index (F.I.)

Topography	M1	M2	M3	M4	M5
1/5th part	Nil	Nil	Nil	Nil	Nil
2/5th part	5.3%	42.6%	20%	11.1%	2.2%
3/5th part	70.2%	57.4%	80%	88.9%	93.5%
4/5th part	24.5%	Nil	Nil	Nil	4.3%
5/5th part	Nil	Nil	Nil	Nil	Nil
Mean F.I.	65.3	43.6	44.4	45.3	47.5

(M1, M2, M3, M4 and M5 – first, second, third, fourth and fifth metatarsals)

ridge in 11 cases. The foramina were not observed on the medial surface of any of the first metatarsal bone. The detailed analysis of the foramina of the first metatarsal bone is represented in Table 1.

Analysis of the second metatarsal showed that, 83% had solitary foramen, 3.8% had dual foramina and in 13.2% of the bones, foramen was not observed. The foramen was present at the medial surface in 12 cases, at

the lateral surface in 32 and over the plantar ridge in 2 second metatarsals. The frequency of distribution of second metatarsal nutrient foramen was shown in Table 2. In the third metatarsal, 83.3% had solitary foramen, 3.7% had dual foramina and in remaining 13%, the foramen was absent. It was observed at the medial surface in 29 cases, at lateral surface in 14 metatarsals and at the plantar ridge in four cases. The distribution was represented in Table 3.

The fourth metatarsal had single foramen in 77.2% of cases, double in 14% cases, triple in 1.8% cases and in 7% cases, the foramen was absent. The foramen was present at the medial surface in 31 bones, at the lateral surface in 21 fourth metatarsal bones and over the plantar ridge in 1 case. The detailed analysis of fourth metatarsal bone was shown in Table 4. In contrast, the fifth metatarsal had single foramen in 83% of cases, double foramen in 1.9% cases and in 15.1% cases, the foramen was found to be absent. It was present on the medial surface in 8 cases and was above the plantar ridge in 17 cases. The foramina were not observed on the lateral surface in the fifth metatarsal. Table 5 showed the morphological distribution of foramina of the fifth metatarsal bone.

The mean foramina index was 65.3 for the first metatarsal, 43.6 for second, 44.4 for the third, 45.3 for fourth and 47.5 for the fifth metatarsal bone. Most of the foramina (70.2%) in the first metatarsal were present at the 3/5th part, 57.4% of second metatarsal foramen were at the 3/5th part, 80% of third metatarsal nutrient foramina were located at 3/5th part, 88.9% of the fourth metatarsal foramen were at 3/5th part and 93.5% of the fifth metatarsal foramen were at 3/5th part from the base of each metatarsal bone. Table 6 analyzed the topography of the foramina along the length of the metatarsals, i.e. in the 1/5th, 2/5th, 3/5th, 4/5th and 5/5th parts as seen from the foraminal index. It was observed that the nutrient foramina of 2nd to 5th metatarsals were directed towards the base, whereas the first metatarsals had

foramina which were directed towards head.

DISCUSSION

The nutrient artery being the main source of nutrition to the long bone is important especially during the childhood and puberty (Patake & Mysorekar 1977). Nutrient foramen is the external opening of nutrient canal which has a particular position for each bone. The topographical information of nutrient foramen could be required in few surgeries (Malukar & Joshi 2011). It is stated that the vessels, which occupy the nutrient foramen, are derived from those which took part in the invasion of ossifying cartilage, so that the nutrient foramen was at the site of original center of ossification (Payton 1934). There is slanting of the nutrient canal during the growth. The direction of slanting from the periosteal surface towards the bone marrow cavity points towards the no growing end. This is because of the higher longitudinal development at the growing end. All the typical long bones have two epiphysial ends, the upper epiphysis and the lower epiphysis. This is in contrast to the short long bones which have only one epiphysis. The directions of nutrient foramina of all long bones are always away from the growing end (Malukar & Joshi 2011). It is evident that most metatarsals have one nutrient foramen located in the middle third of bone (Patake & Mysorekar 1977). Singh (1960) observed double nutrient foramina occurring more commonly in the metatarsals. Also, he found that double foramina were most common in the first and fifth metatarsals. Patake

and Mysorekar (1977) also reported that the double foramina were seen most frequently in the first metatarsal. The present study agrees with these reports as the double foramina were observed in 22% of the first metatarsals. In cases where double nutrient foramina are located on the same surface, it is likely that the nutrient arteries arise from the same artery. When the foramina are located on different surfaces, the source of arteries is likely to be different (Patake & Mysorekar 1977).

The direction of the nutrient foramen is determined by the growing end of the long bone. The growing end develops at least twice as fast as the non-growing end (Mysorekar 1967). The growth rates at two ends and bone remodeling are the factors which might affect the position of nutrient foramen (Henderson 1978). It is not uncommon to see the absence of nutrient foramen in the long bone (Lutken 1950; Mysorekar 1967; Henderson 1978). After the cessation of growth, the short long bones are predominantly supplied by the periosteal vessels and the nutrient artery becomes relatively unimportant (Patake & Mysorekar 1977). In cases, where the nutrient foramen is absent, it is therefore likely that the periosteal artery provides the nutrition to the bone. In the present study, 10.4% of metatarsals didn't exhibit the nutrient foramen. It is believed that, they are likely to be supplied by the periosteal artery. It is believed that the nutrient artery provides the major blood supply but periosteal circulation will be adequate enough for the required blood supplement. In that situation the periosteal circulation is adequate for bone healing. However,

the importance of nutrient artery for the reconstruction should not be underestimated. It was described that the potential impact of vascularized bone graft from the metatarsal bones, the 2nd metatarsophalangeal joint (MTPJ), which was based on the first metatarsal artery regardless of its dorsal or plantar origin, was usually used for the clinical joint transfer. This means conventional 2nd MTPJ harvest could not preserve the nutrient artery through the foramina because most of the foramen was located at the lateral side of the 2nd metatarsals and the mean foramina index was 43.6 for the second metatarsal. From the clinical experience, there were no reports about the bone necrosis after the joint transfer. This suggests that the blood supply to the joint may be majorly from the periosteal vessels.

Patake and Mysorekar (1977) reported that, according to Wood Jones (1946), the nutrient foramina of first and second metatarsals and usually of the third and fourth, are located on their lateral surfaces, whereas that of the fifth metatarsal is on the medial surface. Patake and Mysorekar (1977) and Singh (1960) observed that, in the fourth metatarsal, foramina were more commonly observed on the medial surface. The present investigation observed that, in the first metatarsal the foramen was always present on the lateral surface. Most of the foramina were on the lateral surface in the second metatarsal bone. Whereas the third, fourth and fifth metatarsals exhibited the foramina mostly on their medial surface. This topography of the nutrient foramen of the metatarsal bone

is exactly opposite to the metacarpals of the upper limb. According to a study by Premchandran et al. (2013), the foramina were more common at the medial surface in the first and second metacarpals of the upper limb. In other metacarpals, the foramina were mostly seen on the lateral surface. This change in the topography of the foramen is due to the rotation of limb buds during the development just like the other differences between the upper and lower extremities.

It has been reported that the topography of the nutrient artery in the fifth metatarsal bone is important while planning a corrective osteotomy for a bunionette deformity. This would allow the most proximal osteotomy possible without interrupting the nutrient arterial supply (McKeon et al. 2013). McKeon et al. (2013) described the nutrient artery and the topography of the nutrient foramen of the fifth metatarsal bone. They observed that the dorsalis pedis artery, posterior tibial artery and the peroneal artery were providing the branch which supplied the fifth metatarsal bone. The nutrient artery was arising from the fourth plantar metatarsal artery in all of their specimens. The average distance of the nutrient foramen from the base of the fifth metatarsal bone was 26.8 mm. It was opined that the osteotomies performed within the proximal 40 mm of the bone would carry the risk of interrupting the nutrient artery, which may lead to the nonunion (McKeon et al. 2013).

Brookes (1963) found that, in the short long bones, in later part of fetal period, more growth occurred at the end that

would develop into epiphysis. Lacroix (1951) suggested that asymmetrical muscle development could modify the traction forces acting over the periosteum. The forces are capable of modifying or even reversing the direction of entry of nutrient artery into the diaphysis. Many theories have been put forward to account for the direction of nutrient canals and also on anomalously directed ones. Among them, 'periosteal slip' theory of Schwalbe (1876) and the vascular theory of Hughes (1952) were widely accepted among the scientific community. The present investigation observed that the direction of the foramen was away from the growing end, thereby favoring the growing end theory.

It was described that the anatomical knowledge about nutrient foramen is useful to the operating surgeon to avoid complications like excessive hemorrhage. In the clinical set up, bony defect following the traumatic injuries like fractures, tumor resections and pseudoarthrosis, all have been reconstructed by the bone graft procedures and the preferred modality is free vascularized bone graft (Pho 1988). It has been described that, a vascular pedicle flap from the dorsal metatarsal artery is often used in the thumb reconstruction with toe transfer. During this procedure, the pedicle at the space at first web has to be identified (Henry & Wei 2010). According to Spanio et al. (2005), 21.2 % of the patients had an asymmetric vascular pattern in the first web space. They reported that, this data cautions the surgeons about the possibility of vascular pedicle asymmetry between two feet in bilateral

toe harvest procedure. They opined that the safe and straightforward toe harvest, regardless of the vascular pedicle course variations is required by the surgeon. The amputation of the foot causes disability in day-to-day life. The complete or partial removal of metatarsal bone affects the arches of the foot and balance while walking (Hashimoto et al. 2014). In order to preserve the metatarsal bone, the free flap transfers are necessary. The condition of the artery of the limb is important for the anastomosis of the artery and vein (Hashimoto et al. 2014). The plastic surgeons can improve congenital and acquired defects, such as trauma by reshaping the tissue, based on the principles of wound healing and blood supply. The flap surgeries are the best; flaps are thicker blocks of tissue that have a blood supply (Zitelli et al. 2012). We believe that the anatomical detail of the nutrient artery is important to the plastic surgeons while taking the grafts. The observations of the present study may be enlightening to the plastic surgeon during the bone graft procedures. However, the present study has few limitations; there is deficiency of data of the individuals who owned these metatarsal bones. The gender based comparison was not possible in the present investigation. We could not able to segregate the metatarsals into right and left sides. So the side wise comparison was not performed. The statistical comparison was not possible since the study was from the random samples. This was a mere cross-sectional study. Correlation of data obtained in the present investigation to the physical condition of foot was not clarified.

CONCLUSION

We believe that the present investigation has added extra information about the morphology and location of the nutrient foramen of the metatarsal bones and their foraminal index. The present study observed that metatarsal bones had one nutrient foramen which was situated in the 3/5th part of length of the bone. Few metatarsals had no foramina and some of them had double and even triple foramina. In the first metatarsal, the foramina were always present on the lateral surface. Most of the foramina were situated on the lateral surface in the second metatarsal bone. Whereas the third, fourth and fifth metatarsals exhibited the foramina mostly on their medial surface. All the metatarsal bones followed the growing end theory of the nutrient artery. The present study observed that the site of entry of the nutrient artery to the metatarsal bones had significant variations. This may suggest that the periosteal circulation is also an essential factor and this has to be considered during the reconstruction procedures.

ACKNOWLEDGEMENTS

The authors sincerely thank staff and members of the Department of Anatomy laboratory for the help given during this present study.

REFERENCES

- Brookes, M. 1963. Cortical vascularization and growth in foetal tubular bones. *J Anat* 97(Pt 4): 597-609.
- Collipal, E., Vargas, R., Parra, X., Silva, H., Del Sol, M. 2007. Diaphyseal nutrient foramina in the

- femur, tibia and fibula bones. *Int J Morphol* 25(2): 305-8.
- Green, D.P. 1988. Operative hand surgery. 2nd edition. New York: Churchill Livingstone; 1248.
- Hashimoto, I., Abe, Y., Morimoto, A., Kashiwagi, K., Goishi, K., Nakanishi, H. 2014. Limb salvage and vascular augmentation by microsurgical free flap transfer for treatment of neuropathic diabetic foot ulcers. *J Med Invest* 61(3-4): 325-32.
- Henderson, R.G. 1978. The position of the nutrient foramen in the growing tibia and femur of the rat. *J Anat* 125(Pt 3): 593-9.
- Henry, S.L., Wei, F.C. 2010. Thumb reconstruction with toe transfer. *J Hand Microsurg* 2(2): 72-8.
- Hughes, H. 1952. The factors determining the direction of the canal for the nutrient artery in the long bones of mammals and birds. *Acta Anat (Basel)* 15(3): 261-80.
- Kizilkanat, E., Boyan, N., Ozsahin, E.T., Soames, R., Oguz, O. 2007. Location, number and clinical significance of nutrient foramina in human long bones. *Ann Anat* 189(1): 87-95.
- Lacroix, P. 1951. Organization of Bones. London: J. and A. Churchill; 235.
- Lutken, P. 1950. Investigation into the position of the nutrient foramina and the direction of the vessel canals in the shafts of the humerus and femur in man. *Acta Anatomica* 9: 57-68.
- Malukar, O., Joshi, H. 2011. Diaphysial nutrient foramina in long bones and miniature long bones. *NJIRM* 2(2): 23-6.
- McKeon, K.E., Johnson, J.E., McCormick, J.J., Klein, S.E. 2013. The intraosseous and extraosseous vascular supply of the fifth metatarsal: implications for fifth metatarsal osteotomy. *Foot Ankle Int* 34(1): 117-23.
- Murlimanju, B.V., Prashanth, K.U., Prabhu, L.V., Saralaya, V.V., Pai, M.M., Rai, R. 2011. Morphological and topographical anatomy of nutrient foramina in human upper limb long bones and their surgical importance. *Rom J Morphol Embryol* 52(3): 859-62.
- Mysorekar, V.R. 1967. Diaphysial nutrient foramina in human long bones. *J Anat* 101(Pt 4): 813-22.
- Patake, S.M., Mysorekar, V.R. 1977. Diaphysial nutrient foramina in human metacarpals and metatarsals. *J Anat* 124(Pt 2): 299-304.
- Payton, C.G. 1934. The position of the nutrient foramen and direction of the nutrient canal in the long bones of the madder-fed pig. *J Anat* 68(Pt 4): 500-10.
- Pho, R.W.H. 1988. Microsurgical technique in orthopaedics. 1st edition. Scotland: Butterworth & Co. Ltd; 128.
- Prashanth, K.U., Murlimanju, B.V., Prabhu, L.V., Kumar, C.G., Pai, M.M., Dhananjaya, K.V.N. 2011. Morphological and topographical anatomy of nutrient foramina in the lower limb long bones and its clinical importance. *Australas Med J* 4(10): 530-7.
- Premchandran, D., Murlimanju, B.V., Prabhu, L.V., Saralaya, V.V., Kumari, A., Rao, K.A., Prashanth, K.U., Rai, A. 2013. Topography and morphological anatomy of nutrient foramina in human metacarpal bones and their clinical implications. *Clin Ter* 164(4): 295-300.
- Schwalbe, G. 1876. Zeitschrift für Anatomie und Entwicklungsgeschichte. 1: 307-52.
- Shrimankar, D.P.S., Trivedi, D.J., Kariya, V.B. 2010. A study of nutrient foramina of the metacarpal bones. *NJIRM* 1(2): 16-21.
- Singh, I. 1960. Variations in the metatarsal bones. *J Anat* 94: 345-50.
- Snell, R.S. 2007. *Clinical Anatomy by Systems*. Baltimore: Lippincott Williams and Wilkins; 358.
- Spanio, S., Wei, F.C., Coskunfirat, O.K., Lin, C.H., Lin, Y.T. 2005. Symmetry of vascular pedicle anatomy in the first web space of the foot related to toe harvest: clinical observations in 85 simultaneous bilateral second-toe transfer patients. *Plast Reconstr Surg* 115(5): 1325-7.
- Standing, S. 2005. Gray's Anatomy. The anatomical basis of clinical practice. 39th edition. Edinburgh: Elsevier, Churchill Livingstone; 1520-2.
- Wood Jones, F. 1946. Buchanan's Manual of Anatomy. London: Bailliere, Tindall and Cox; 310, 367.
- Zitelli, B.J., McIntire, S.C., Nowalk, A.J. 2012. *Zitelli and Davis' Atlas of Pediatric Physical Diagnosis*. 6th edition. Philadelphia, PA: Elsevier Saunders; 908.