

## Case Report

# Spontaneous Rupture of Spleen: A Case Report

Singhal BM, Shakya P, Sagar S, Kaval S

Department of Surgery, Lala Lajpat Rai Memorial Medical College, Meerut, Uttar Pradesh, 250004, India.

### Abstract

Spontaneous or idiopathic splenic rupture is a rare cause of acute abdominal pain and hemoperitoneum and its incidence is 1% of all cases of splenic rupture. The etiology of spontaneous splenic rupture can be idiopathic or it may occur as a complication of an infectious, neoplastic or hematologic disease. Splenic rupture presents with pain in the left upper quadrant with shock and features of peritoneal irritation, like Kehr's sign (left shoulder pain due to diaphragmatic irritation) and Balance sign (palpable tender mass in left upper abdomen). The diagnosis of spontaneous splenic rupture presents a diagnostic challenge due to the absence of a history of trauma. Focused Abdominal Sonography for Trauma FAST may be suggestive but due to its limitations, Computerized Tomography Scan CT scan of abdomen is the best imaging modality both for detection and grading of splenic injury. Management can be non-operative or surgical depending on grade and hemodynamic status of the patient. We report a rare case of spontaneous rupture of the spleen, which was idiopathic and fulfills the criteria of Orloff and Peskin, due to absence of any history of trauma, absence of perisplenic adhesions or scarring, and it without any evidence of disease affecting the spleen with macro and microscopically normal spleen. This case also adheres to fifth criteria described by Crate and Payne, as there was no immunological evidence suggestive of any viral infections affecting the spleen.

**Keywords:** Spleen, rupture, spontaneous, idiopathic, atraumatic, splenectomy, splenorrhaphy, unknown aetiology

### Correspondence:

Dr. Singhal BM, Department of Surgery, Lala Lajpat Rai Memorial Medical College, Meerut, Uttar Pradesh., 250004, India. Tel: 91 7897456466 Fax: NA Email: [singhalbm@gmail.com](mailto:singhalbm@gmail.com)

Date of submission: 11 Jan, 2014

Date of acceptance: 12 July, 2014

### Introduction

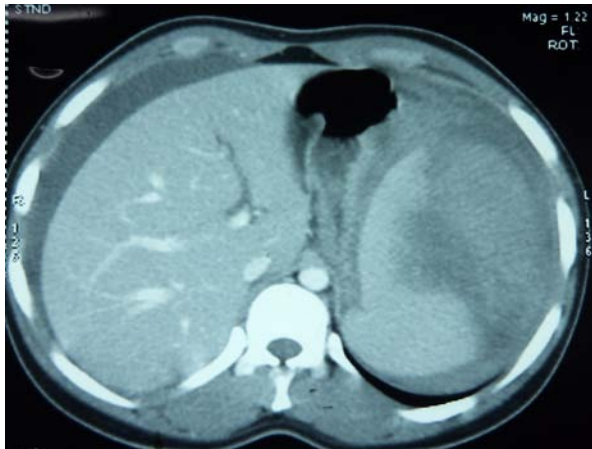
Splenic rupture was first reported by Rokitansky in 1861, it is usually due to trauma and it is a grave abdominal emergency (1). But Atkinson in 1874, first described idiopathic or spontaneous rupture of spleen as a distinct clinical entity and its incidence is 1% of all cases of splenic rupture (2,3). Spontaneous splenic rupture may occur as a complication of an infectious, neoplastic or hematologic disease or can be idiopathic (1). The present case report illustrates that spontaneous ruptures of the spleen should be considered as one of the cause of the acute abdomen.

### Case Report

A 17-year-old female, presented at the surgical emergency of our institution with sudden onset severe

abdominal pain for last 24 hours which was aggravated by breathing. It was not associated with vomiting, hematemesis or melena. There was no history of fever chills and rigors, sore throat, cough or any previous infection. There was no history suggestive of trauma to the abdomen or chest. There was no history of blood transfusion, spontaneous bleeding, tuberculosis, any chronic illness or any surgery in the past.

On admission, her pulse rate was 144/min with a low Blood Pressure of 90/50 mmHg. On general examination, she was tachypnoeic with respiratory rate of 30/min and she was severely pale. On abdominal examination, it was distended with guarding and rigidity present in all quadrants and bowel sound was absent.

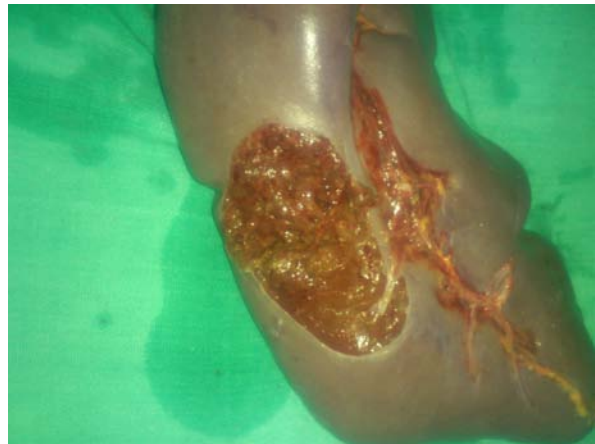


**Figure 1:** CT scan showing splenic rupture and haematoma with haemoperitoneum.

On imaging, FAST revealed, moderate fluid in peritoneal cavity with gross internal echoes. There was moderately enlarged spleen with irregular margins at the upper pole suggestive of hematoma. Contrast Enhanced Computerised Tomography (CECT) of the abdomen showed moderate splenomegaly having irregular margins of upper lateral part suggestive of subcapsular hematoma with significant free fluid present in perisplenic area and peritoneal cavity. (Fig. 1) Hematological investigations were suggestive of recent blood loss with Haemoglobin = 4gm/dl, (normal range 11-15 gm/dl) Total Leukocyte Count = 15,200/cmm (normal range 4,000 – 11,000 /cmm) and raised reticulocyte count. Other laboratory parameters were within normal limits.

Ultrasound guided aspiration of peritoneal cavity revealed frank blood. The patient's vital signs were unstable despite adequate fluid resuscitation and emergency laparotomy was performed. Intra-operatively there was, 2000 ml of blood along with clots. There was a large (12cm x 10 cm) hematoma on the posterolateral surface of the upper pole of the spleen along with an approximately 6 cm long and 3.5cm deep laceration near the hilum (Fig. 2). An attempt on splenorrhaphy failed to stop the bleeding, so splenectomy was done. Post operatively, patient was kept under broad spectrum antibiotic coverage with 4th generation cephalosporins. The postoperative period was uneventful and patient was discharged on the 9th postoperative day. Patient was given polyvalent pneumococcal vaccine, meningococcal polysaccharide vaccine as well as vaccines for H. Influenzae at the time of discharge.

Histopathological analysis of the resected spleen did not reveal any pathology. The postoperative general blood picture showed microcytic hypochromic RBCs



**Figure 2:** Splenectomy Specimen showing laceration near hilum.

admixed with few normocytic hypochromic RBCs. The WBC counts were within normal limit, platelet count was adequate and no hemoparasite was detected. Further investigations for tuberculosis by real time PCR and MONOSPOT test for infectious mononucleosis were non-reactive.

## Discussion

Splenic rupture can occur in a diseased spleen or a normal spleen, due to trauma or rarely spontaneous. The spontaneous rupture term is used for normal spleen that has ruptured without any overt trauma; this has also been described as idiopathic rupture (4,5). At the same time, it is suggested that spontaneous rupture of a diseased spleen should be termed as pathological rupture or occult rupture (4,6).

Various conditions described to be associated with spontaneous rupture of the spleen are enumerated in Table 1. Many authors have questioned the validity of this condition and have suggested that so called spontaneous rupture occur only in a diseased spleen or it may be a case of delayed traumatic rupture (4). Orloff and Peskin (7) in 1958 described four steps criteria for the diagnosis of spontaneous rupture consisting of: (i) no trauma history or unusual effort that may injure spleen, (ii) no perisplenic adhesions or scarring that may support previous trauma, (iii) no evidence of disease affecting the spleen and (iv) presence of a normal spleen both micro and macroscopically. These criteria are still regarded as gold standard for diagnosis of spontaneous rupture. Crate and Payne (5) in 1999, added a fifth criteria as a lack of viral infections affecting the spleen, without any elevation in viral antibody titers in both the acute phase and incubation periods.

**Table 1:** Etiology of atraumatic splenic rupture<sup>4</sup>

Cause	Conditions
<b>Infections</b>	Staphylococci, Streptococci, Clostridium, Actinomycosis, Pseudomonas, Salmonella, Enterobacter, Campylobacter, Haemophilus, Tularemia, Brucellosis, Legionellosis, Tuberculosis, Infectious Mononucleosis, Mumps, Hepatitis A, Dengue, Cytomegalovirus, Rubella, Varicella-Zoster, Influenza, HIV, Malaria, Kala-azar, Syphilis, Hydatid disease, Typhus, Leptospirosis, Q fever, Candidiasis
<b>Hematological conditions</b>	Haemophilia, Congenital a fibrinogenaemia, Congenital factor XIII deficiency, Protein S deficiency, Idiopathic thrombocytopaenic purpura, Haemolytic anemia, Polycythemia vera, Myelofibrosis
<b>Metabolic disorders</b>	Amyloidosis, Wilson's disease, Gaucher's disease, Niemann-pick disease, Systemic lupus erythematosus, Rheumatoid arthritis, Polyarteritis nodosa, Wegener's vasculitis, Ehlers-danlos syndrome, Pheochromocytoma, Sarcoidosis
<b>Neoplastic conditions</b>	Leukemia, Lymphoma, Multiple myeloma, Splenic malignancy (primary Haemangiosarcoma, secondary metastatic carcinoma, Teratoma, Melanoma, Choriocarcinoma), Hepatocellular carcinoma
<b>Misc</b>	Extra-corporeal shock wave lithotripsy, Splenic cyst, Splenic peliosis, Splenic vein thrombosis, Portal hypertension, Vomiting, Uraemia, Acute Pancreatitis, Chronic pancreatitis, Infective endocarditis, Pregnancy, Cirrhosis of liver, Crohn's disease, Drug like heparin, warfarin, streptokinase, Granulocyte colony stimulating factor, Ticlopidine, Dicumarol.

**Table 2:** Splenic Injury Scale and recommended management<sup>11</sup>

Grade	Description	Management
<b>I</b>	Haematoma – Subcapsular tear < 10% surface area Laceration – Capsular tear < 1 cm parenchymal depth	Non operative Management*
<b>II</b>	Haematoma – Subcapsular tear 10 – 50% surface area, intraparenchymal < 5 cm in diameter Laceration – Capsular tear 1-3 cm parenchymal depth that does not involve a trabecular vessel	Non operative Management*
<b>III</b>	Haematoma – Subcapsular tear > 50% surface area or expanding, ruptured subcapsular or parenchymal, intraparenchymal > 5 cm or expanding Laceration – > 3 cm parenchymal depth or involving a trabecular vessel	Non operative Management* / Splenorrhaphy / Splenectomy
<b>IV</b>	Laceration – involving segmental or hilar vessel producing major devascularization (> 25% of spleen)	Resectional Debridement / splenectomy
<b>V</b>	Completely shattered spleen, hilar vascular injury devascularizes spleen	Splenectomy

\*Contraindication to Non Operative Management include: Age 55 years or older, GCS 13 or <, Hemodynamic instability (Bp < 90mm Hg, PR > 120/min, no immediate response to 1-2 L of crystalloid resuscitation), Grade IV or V injuries, associated injuries to other organ requiring prompt surgical management.<sup>11</sup>

The most accepted theory to explain the spontaneous rupture of the spleen is the existence of a small area of localized disease which is destroyed by rupture with no traces left on the spleen. Other suggested theories are: (4,8)

- The degenerative changes of the splenic artery or rapid dissection into the splenic parenchyma due to silent chronic passive congestion, can trigger the rupture.
- A minor trauma, such as a sudden increase in intra-abdominal pressure with exercise, coughing or vomiting can rupture the capsule of the spleen or
- Presence of congenital weak spots in splenic artery may be the cause.

Splenic rupture generally presents with pain in the left upper quadrant with shock and features of peritoneal irritation. Specifically, Kehr's sign (left shoulder pain due to diaphragmatic irritation) and Balance sign (palpable tender mass in left upper abdomen) are suggestive of splenic injury (9). In absence of a history of trauma, diagnosis of splenic rupture may present a diagnostic challenge. Routine plain abdominal radiography may suggest enlarged splenic shadow along with indentation or medial displacement of gastric air bubble (radiological balance sign) and elevated left hemidiaphragm with impaired motion (10). Abdominal sonography is usually the first investigation for abdominal trauma and pain. Focused Abdominal Sonography for Trauma (FAST) is the best investigation for detecting free fluid in the peritoneal cavity in a hemodynamically unstable patient. Limitations of FAST are that it cannot detect fluid volumes <200-500ml as well as the type or source of fluid and sensitivity is affected in the presence of bowel gas. However, at times it may reveal an irregular enlarged spleen or splenic hematoma (10).

Currently, Computerized Tomography Scan (CT Scan) is the best imaging modality for detection and grading of splenic injury, the only limitation being that it cannot be performed in unstable patients. (Table-2) CT sensitivity and specificity is 95% in detecting splenic injury and it has replaced the angiography (8,11). However, angiography can be used for embolization of bleeding vessels in hemodynamically unstable patients with a blush in CT Scan (10).

In the past splenectomy was the treatment of choice for splenic rupture, but because of the role of the spleen in immunity and post splenectomy infection (OPSI), there has been a trend in conservative management for splenic injury in hemodynamically

stable patients (Table 2). After a splenectomy chance of OPSI is 3.2%, which is a lethal complication with mortality rate of 40-50 %, hence during laparotomy, attempts at repair of the spleen or tamponade by the use of an absorbable mesh (splenorrhaphy) should be considered to preserve the splenic tissues (7,11,12). Post splenectomy, vaccination must be given to ensure protection from encapsulated bacteria, including *Streptococcus pneumoniae*, *Neisseria meningitidis* and *Haemophilus influenzae* (11,12).

Our case fulfills the criteria of Orloff and Peskin as well as Crate and Payne as a rare case of spontaneous rupture, as there was no history of trauma, infection or hematological disease. Macroscopic and microscopic examinations of the spleen as well as serological tests also did not reveal any pathology.

## References

1. Acar YA, Dedeoglu E, Cevik E, et al. Spontaneous Rupture of Spleen as a Rare Cause of Abdominal Pain: Case Report. *Eur J Surg Sci* 2010; 1: 27-9.
2. Atkinson E. Death from idiopathic rupture of spleen. *BMJ* 1874; 2: 403-4.
3. Badenoch DF, Maurice HD, Gilmore OJ. Spontaneous rupture of a normal spleen. *J R Coll Surg Edinb* 1985; 30(5): 326-27.
4. Debnath D, Valerio D. Atraumatic rupture of the spleen in adults. *J R Coll Surg Edinb* 2002; 47(1): 437-45.
5. Crate ID, Payne MJ. Is the diagnosis of spontaneous rupture of a normal spleen valid? *J R Army Med Corps* 1991; 137(1): 50-1.
6. McMahon MJ, Lintott JD, Mair WS, Lee PW, Duthie JS. Occult rupture of the spleen. *Br J Surg* 1977; 64(9): 641-2.
7. Orloff MJ, Peskin GW. Spontaneous rupture of the normal spleen; a surgical enigma. *Int Abstr Surg* 1958; 106(1): 1-11.
8. Jeffrey RB, Laing FC, Federle MP, Goodman PC. Computed tomography of splenic trauma. *Radiology* 1981; 141(3): 729-32.
9. Wehbe E, Raffi S, Osborne D. Spontaneous splenic rupture precipitated by cough: a case report and a review of literature. *Scand J Gastroenterol* 2008; 43(5): 634-7.

10. Leizmen M, de Steur WO, Brekelmans W, da Costa A. Non-traumatic rupture of the spleen: an atypical presentation of the acute abdomen. *Abdominal Surgery* 2011/2012.
11. Beauchamp RD, Holzman MD, Fabian TC, Weinberg JA: The Spleen. In Sabiston Textbook of Surgery 18th ed. Edited by: Townsend CM. Philadelphia:Elsevier; 2008, pp 1624-52.
12. Bisharat N, Omari H, Lavi I, Raz R. Risk of infection and death among post-splenectomy patients. *J Infect* 2001; 43(3): 182-6.