

## Case Report

# Mucinous Cystadenoma of the Appendix: A Diagnostic Dilemma

Chaudhary P

Lady Hardinge Medical College and associated Dr Ram Manohar Lohia Hospital, New Delhi-110001, India.

### Abstract

Mucinous cystadenoma of appendix is a rare clinical entity. We here report a case of an elderly male who presented in surgery outpatient department for routine check-up. Ultrasonography followed by CT scan of the abdomen did not give any conclusive diagnosis, following which exploratory laparotomy was done which was suggestive of appendiceal mucocele. The aim of reporting this case was to review the various clinical presentations and an optimum management of such incidental tumors.

**Keywords:** Asymptomatic, lump, abdomen, mucinous cystadenoma, frozen section, hemielectomy, tissue.

### Correspondence:

Poras Chaudhary, Lady Hardinge Medical College and associated Dr Ram Manohar Lohia Hospital, New Delhi-110001, India. Tel: 9891447358 Fax: 23408338 Email: drporaschaudhary@yahoo.com

Date of submission: 4 Oct, 2013

Date of acceptance: 25 Mar, 2014

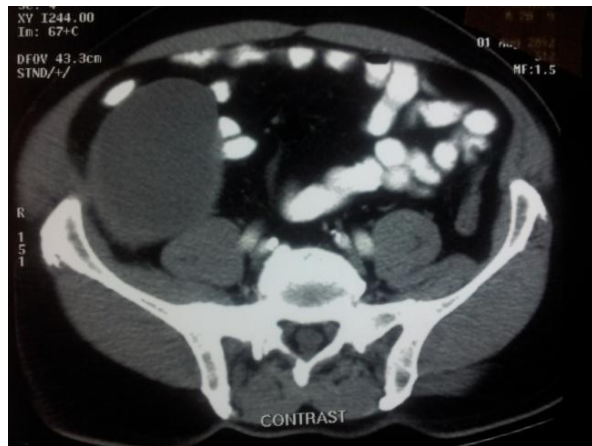
### Introduction

Mucinous cystadenoma of the appendix is a rare type of appendiceal mucocele (1), and most of these tumors are asymptomatic and are found incidentally. Mucocele of the appendix is a multilocular cystic tumor resulting from obstructive dilatation and accumulation of mucus in the appendiceal lumen, which can be caused by benign neoplastic lesions such as mucinous adenomas or mucinous cystadenomas, mucinous tumors of uncertain malignant potential, or malignant neoplastic lesions like mucinous cystadenocarcinomas. The major complication of these tumors is pseudomyxomateritonei. Hence, during surgery, surgeon must take care in handling the appendiceal mass.

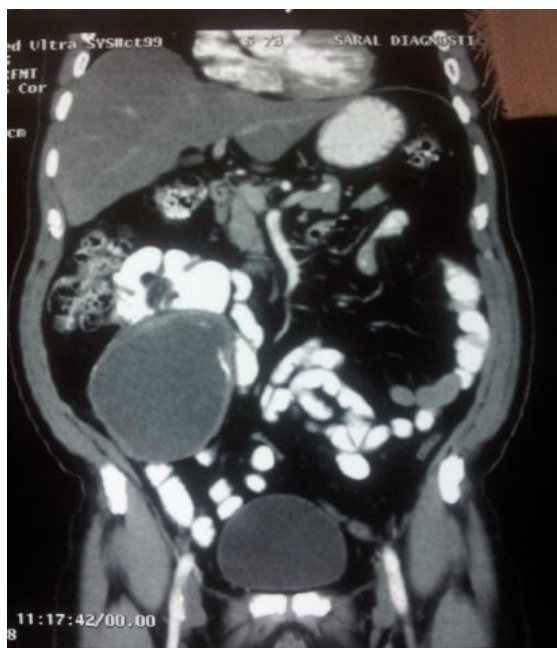### Case Report

A 65-year-old asymptomatic male presented to the outpatient department for routine examination. There was no history of any significant illness or any other associated medical disease. His general physical examination was normal and abdominal examination revealed an intraperitoneal firm, non-tender lump of size 8x10 cm in right iliac region and also occupied

parts of umbilical and right lumbar region, with well defined margins, smooth surface and mobile in all directions. Haemogram, liver and kidney function tests were normal. Ultrasonography showed a well defined cystic mass in right lower abdomen with central necrosis suggestive of either a mesenteric cyst or a hydatid cyst. CECT of the abdomen (Fig. 1a, 1b) showed a homogenous cystic mass with well defined margins which were thickened at some places, presence of calcification and central necrosis and no organomegaly or presence of free fluid in the peritoneal cavity, suggestive of lymphangioma, hydatid cyst, or mesenteric cyst, but did not consider mucinous tumor the appendix in differential diagnosis. Hydatid serology was negative, CEA was normal and colonoscopy did not reveal anything significant except for the presence of extrinsic compression on caecum. After pre-operative workup, patient was taken up for surgery. On exploration, there was a large, firm appendicular mass, free from surrounding structures, no peritoneal deposits, and there was no ascitic fluid (Fig. 2), but involved the base of the appendix and mesoappendix. Appendicular mass was excised carefully without spillage and sent for frozen section, which was suggestive of mucinous cystadenoma. In



(a)



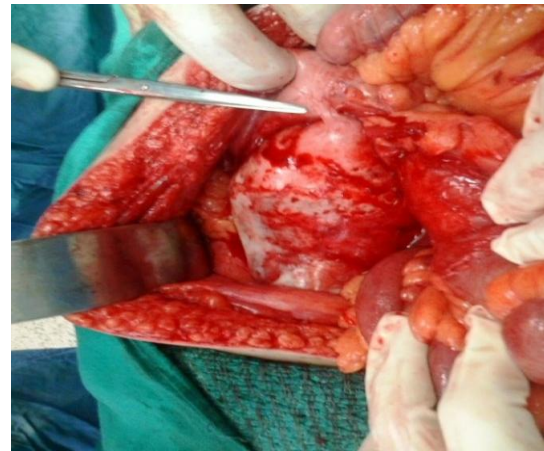
(b)

**Figure 1** (a) and (b): CECT shows a homogenous cystic mass with well defined margins and thickened margins at some places, presence of calcification and central necrosis and no organomegaly or presence of free fluid in the peritoneal cavity, suggestive of lymphangioma, hydatid cyst, mesenteric cyst.

view of the tumor size more than 2 cm (10 cm in this case) and involvement of mesoappendix and the base of the appendix, right hemicolectomy was done in this case. The patient was discharged on post-operative day 6 in satisfactory condition.

### Discussion

Cystic lesions of the appendix are rare, the incidence of mucocele of the appendix is reported to be 0.2 to



**Figure 2:** Appendiceal mass attached to the pushed up caecum with no peritoneal deposits.

0.3% (2). Non-neoplastic and neoplastic lesions include mucosal hyperplasia (25%), mucinous cystadenoma (63%), and mucinous cystadenocarcinoma (12%) (3). Approximately 25 to 50% are asymptomatic, and are found incidentally at clinical examination, as seen in our patient, where a non-tender lump was found. It may be found during imaging or surgery and sometimes even mimics some other pathology. Patients may present with clinical manifestations caused by acute appendicitis, non-specific abdominal pain and if large enough, with a lump, which could be asymptomatic or may be associated with non-specific symptoms like nausea, vomiting, or distension after meals.

In the present case, after baseline investigations and ultrasonography, CT scan was done. It did not indicate appendiceal tumor but as the tumor was lying in relation to the bowel, colonoscopy was also done which did not show other abnormalities except for the presence of bulge in the caecum. As appendiceal tumors are known to co-exist with colonic neoplasm, colonoscopy should always be done if the mucocele is kept as one of the pre-operative differential diagnosis. In this case, CT scan was suggestive of lymphangioma or hydatid cyst or mesenteric cyst, there is one case report in which mucinous appendiceal tumor not only presented but was also diagnosed as cystic hydatid disease of liver (4) and in another case, it mimicked cystic renal mass (5).

Intra-operatively, a frozen section of the appendicular tumor should always be done for two reasons. Despite extensive pre-operative work up, it is extremely difficult to diagnose cystic lesions of the appendix. Further, it is important to distinguish between mucinous cystadenoma and cystadenocarcinoma as the

latter always needs an extensive procedure for optimum management.

The best surgical treatment in a case of mucinous appendiceal tumor is still a subject of debate and controversy. Though, standard treatment guidelines have been proposed, there is no definite consensus on the choice of procedure. Treatment is usually an appendectomy with mesoappendix excision, the presence of local invasion and caecal involvement are two indications for right hemicolectomy (6). In view of current treatment guidelines, other indications which necessitate appendectomy are tumor size greater than 2 cm and involvement of mesoappendix and the base of the appendix.

Regardless of the histology, principles which must be kept in mind while operating on a patient with appendiceal mucoceles are tissue handling with extreme care to reduce the risk of dissemination of mucin producing epithelium leading to pseudomyxoma peritonei (7). Intra-operative exploration of the entire gastrointestinal tract and ovaries in females should always be done and all gross peritoneal implants should be removed and sent for biopsy with grading of the degree of epithelial atypia for prognostic purposes.

In conclusion, appendiceal mucinous cystadenoma is a benign disease which is difficult to diagnose pre-operatively despite extensive work up and complications from rupture leading to pseudomyxomaperitonei, and invasion into adjacent organs warrant operative intervention with adherence to oncologic principles.

## References

1. Stephensen JB, Brief DK. Mucinous appendiceal tumors: clinical review. *J Med Soc N J* 1985; 82(5): 381-4.
2. Aho AJ, Heinonen R, Lauren P. Benign and malignant mucocele of the appendix. *Histological types and prognosis. Acta Chir Scand* 1973; 139(4): 392-400.
3. Higa E, Rosai J, Pizzimbono Ca, Wise L. Mucosal hyperplasia, mucinous cystadenoma and mucinous cystadenocarcinoma of the appendix. A re-evaluation of appendiceal "mucocele". *Cancer* 1973; 32(6): 1525-41.
4. Krieg A, Esch JS, Poll LW, Braunstein S, Knoefel WT. Mucinous cystadenoma of the appendix misdiagnosed as cystic hydatid disease of the liver: a case report. *J Med Case Rep* 2008; 2: 218.
5. Parsons JK, Freeswick PD, Jarret TW. Appendiceal cystadenoma mimicking a cystic renal mass. *Urology* 2004; 63(5): 981-2.
6. Zagrodonik DF, Rose DM. Mucinous cystadenoma of the appendix: diagnosis, surgical management, and follow-up. *Curr Surg* 2003; 60(3): 341-3.
7. Prayson RA, Hart WR, Petras RE. Pseudomyxoma peritonei. A clinicopathologic study of 19 cases with emphasis on site of origin and nature of associated ovarian tumor. *Am J Surg Pathol* 1994; 18(6): 591-603.