

Case Report

An Unusual Termination of Facial Vein and Anterior Division of Retromandibular Vein into External Jugular Vein: A Case Report

Jyothsna P, Naveen K (✉), Mohandas Rao KG, Ashwini LS, Somayaji SN, Satheesha Nayak B

Department of Anatomy, Melaka Manipal Medical College (Manipal Campus), Manipal University, Manipal, Karnataka State, 576104 India.

Abstract

Facial vein, being the largest vein of the face forms the common facial vein after joining with the anterior division of retromandibular vein below the angle of the mandible. Usually, it drains into the internal jugular vein. During routine dissection of head and neck region of a male cadaver, aged approximately 50 years, an unusual pattern in the termination of veins on the left side of the neck was observed. The formation, course and termination of external jugular vein were normal. The anterior division of retromandibular vein joined with external jugular vein about 5 cm above the clavicle and the facial vein opened into the external jugular vein about 2.5 cm above the clavicle. In addition, there was a thin venous communication between anterior division of retromandibular vein and external jugular vein. The superficial veins of the neck are often used for cannulation; either for intravenous infusion or for central venous pressure monitoring. Furthermore, these venous segments are used as a patch for carotid endarterectomies. Hence, a thorough knowledge of the normal anatomy and their variations may be useful for performing these procedures.

Keywords: Facial vein, external jugular vein, retromandibular vein, venous channel, variation

Correspondence:

Naveen Kumar, Department of Anatomy, Melaka Manipal Medical College (Manipal Campus), Manipal University, Madhav Nagar, Manipal University, Udupi District, Karnataka State, 576104 India. Tel: 91-9880548636 Fax: 91-820-2571905 Email: naveentonse@gmail.com

Date of submission: 11 Aug, 2013

Date of acceptance: 27 Jan, 2014

Introduction

Facial vein (formerly known as anterior facial vein) is the major venous channel of the face, and it is formed by the union of supratrochlear and supraorbital veins. It lies posterior to facial artery and runs downwards with less tortuous course than its accompanying artery. It runs obliquely by the side of the nose along the anterior border of the masseter and then passes over it. It traverses the submandibular region and forms the common facial vein below the angle of the mandible after uniting with anterior division of retromandibular vein. It finally drains into internal jugular vein. The portion of the facial vein before it receives the superior labial vein is often termed as angular vein (1).

Variations in the facial vein termination are not uncommon when compared to other superficial veins

of the head and neck region. However, presence of variant venous pattern of the head and neck region often leads to radiologic misinterpretations or misidentifications during the diagnostic and therapeutic radiographic techniques as in angiography, catheterization and the haemodialysis in renal failure patients (2). These veins also gain clinical importance in surgeries involving microvascular anastomosis (3).

Facial vein can be used for carotid endarterectomy as it has no valves and its walls are not flaccid as most of the other superficial veins. Therefore, the knowledge of these venous variations is important to clinicians as they are used for various clinical procedures and also to the radiologists performing various angiographic procedures.

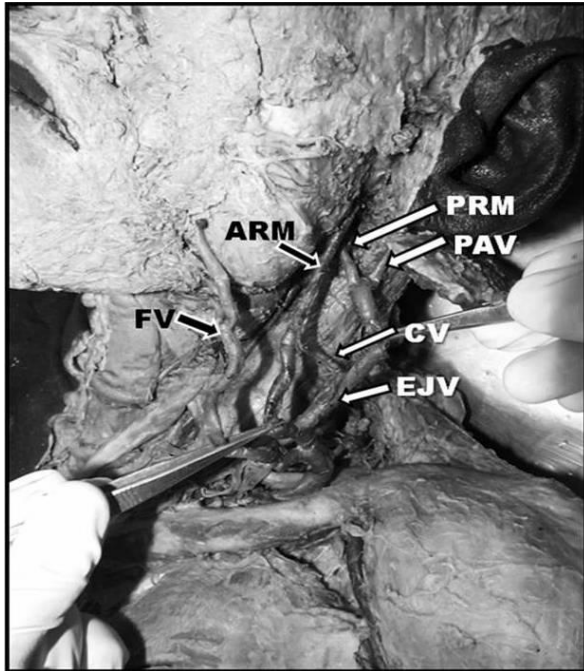


Figure 1: Neck dissection showing variant drainage pattern of facial vein (FV) and anterior division of retromandibular vein (ARM) into external jugular vein (EJV). PRM: posterior division of retromandibular vein, PAV: posterior auricular vein. A communicating vein (CV) can also be noted between ARM and EJV.

Case Report

During routine dissection for medical undergraduate students, we observed an unusual pattern in the termination of veins on the left side of the neck of a 50-year-old, male cadaver. The formation, course and termination of external jugular vein were normal. The anterior division of retromandibular vein joined with external jugular vein, about 5 cm above the clavicle and the facial vein was opening into the external jugular vein about 2.5 cm above the clavicle. In addition, there was a thin venous communication between the anterior division of retromandibular vein and the external jugular vein (Fig. 1).

Discussion

There are ample reports on variant pattern of facial vein terminating into the neighbouring venous channels deviated from its normal pattern of drainage into internal jugular vein as common facial vein. Various cases highlighting its variations in the pattern of termination into the external jugular vein (EJV) (4, 5) into left subclavian vein (6) and into superficial temporal vein (7, 8) were already reported. However, in the available literature, we have not come across with the present type of variation where there is

persistence of communicating channel between EJV and anterior division of retromandibular vein. Reported variations witness the higher prevalence of the venous variations persisting in the right side of the neck, which is contrary to that observed in the present case.

Variations in the venous drainage of head and neck region coincide with the background of its complex development and the phylogenetic observation. Embryologically, these veins form only after the development of skull. Highly complex venous plexus appears after the regression of main cephalic vein. Interconnection between these venous plexuses results in the formation of facial and pharyngeal veins. However, the authoritative venous pattern appears only after the negotiation between 'evolve' and 'atrophy' among the some of these channels. The external jugular vein develops as a resultant venous channel from the tributary of cephalic vein of the neck. At this stage it also communicates with the anterior facial vein. The retromandibular vein develops in the temporal region and forms the common facial vein following its union with linguofacial vein, which eventually drains into precardinal vein; the future internal jugular vein (1).

A study conducted on Indian population on the pattern of venous drainage of the face reported that, the facial vein draining into EJV accounts for about 5% of incidences (4). A study done on variations in the patterns of termination of the facial vein reported the prevalence of this varied pattern of drainage in 9% of cases. The termination of the facial vein is further categorized into two types based on the shapes of drainage channel. Type I with varied degree of obliquity in Y shaped, U shaped, tuning fork shaped or N shaped pattern, where as type II with inverted A shaped or stepladder shaped pattern depending on the persistence of one or more connecting channels between facial vein and EJV (9). The communication persisting in the present case, corresponds to type I category with the U shaped pattern.

Phylogenetically, a pair of vertically oriented subcutaneous veins persists side by side bilaterally. The lateral channel of which represents the EJV whereas, medial as facial vein which in its upper part courses obliquely and its lower segment runs parallel to EJV lying over the sternocleidomastoid muscle. This lower segment of the vein may have one or two transverse communications with each other. This pattern of venous arrangement is normally observed in rhesus monkeys (9).

Bertha & Suganthy reported a case of undivided retromandibular vein. In this case, the trunk of the retromandibular vein joined with the facial vein to form common facial vein resulting in the absence of external jugular vein (10).

During surgical treatment of mandibular condylar fracture and the parotidectomy operations, the retromandibular veins serve as a guide to trace the facial nerve and its branches (11).

External jugular vein, being superficial vein of the neck forms choice of vein for trans-jugular liver biopsy and porto-systemic shunts (12). Hence, it is important to be familiar with possible venous variations in the region of head and neck, particularly the absence of the external jugular vein before attempting surgical procedures.

Conclusion

Unusual venous drainage pattern of facial region as reported in the present case, could be considered by the surgeons in order to prevent excessive bleeding during intraoperative procedures in this region.

References

1. Standring S. Gray's anatomy-The Anatomical Basis of Clinical Practice. 39th ed. Edinburgh: Elsevier Churchill Livingstone, 2005, pp 511-12;609-18
2. Choudhary S, Sharma AK, Singh H. The undivided retromandibular vein continuing as the external jugular vein with the facial vein draining into it: An anatomical variation. JK Science 2010; 12(4): 203-4.
3. Nagase T, Kobayashi S, Sekiya S, Ohmori K. Anatomic evaluation of the facial artery and vein using color Doppler ultrasonography. Ann Plast Surg 1997; 39(1): 64-7.
4. Choudhry R, Tuli A, Choudhry S. Facial vein terminating in the external jugular vein. An embryologic interpretation. Surg Radiol Anat 1997; 19(2): 73-7.
5. Prakash R, Prabhu LV, Kumar J, Nayak V, Singh G. Variations of jugular veins: phylogenic correlation and clinical implications. South Med J 2006; 99(10): 1146-7.
6. Prakash BB, Bhagath KP. A rare termination of left common facial vein into left subclavian vein: a case report. Int J Morphol 2007; 25(3): 555-6.
7. Yadav S, Ghosh SK, Anand SC. Variations of the superficial veins of the head and neck. J Anat Soc India 2000; 49(1): 61-2.
8. Peuker ET, Fisher G, Filler TJ. Facial vein terminating in the superficial temporal vein: case report. J Anat 2001; 198(Pt 4): 509-10.
9. Gupta V, Tuli A, Chaudhry R, Agarwal S, Mangal A. Facial vein draining into external jugular vein in humans: its variations, phylogenetic retention and clinical relevance. Surg Radiol Anat 2003; 25(1): 36-41.
10. Bertha A, Suganthy R. Anatomical Variations in Termination of Common Facial Vein. J Clin Diag Res 2011; 5(1): 24-7.
11. Vollala VR, Bolla SR, Pamidi N. Important vascular anomalies of face and neck – a cadaveric study with clinical implications. Firat Tip Dergisi 2008; 13(2):123-6.
12. Siegel EL, Caresio J, Eckard DA. Use of the external jugular vein approach for transvenous liver biopsy. J Vasc Interv Radiol 1992; 3(2): 371-4.