

Case Report

A Rare Case of Bilateral High Origin of the Testicular Artery with Variations in the Course and Branches

Prasanna LC, Babu A, D'Souza AS, Bhat KMR

Department of Anatomy, Kasturba Medical College, Manipal-576104, India.

Abstract

In general, testicular artery (TA) usually arises from the antero-lateral part of the abdominal aorta below the origin of the renal arteries at second lumbar vertebrae level. Very rarely variations in the origin of the testicular arteries are observed. We here report a rare case of bilateral unusual origin and course of the testicular artery. On the right side, testicular artery arose from the aorta about 0.5cm above the origin of the renal artery and gave off inferior suprarenal artery. In contrast, left testicular artery springs from the pre-hilar branch of the left renal artery, 2cm before reaching the hilum of kidney. On both sides, testicular arteries descended in front of the hilar structures of the kidney. Since, the origin and course of the testicular artery is important to consider during surgical and diagnostic interventions, knowledge of such variation may be helpful in avoiding diagnostic and surgical errors and adverse consequences especially during laparoscopic approaches.

Keywords: Testicular, artery, variations, development, suprarenal

Correspondence:

Kumar MR Bhat, Department of Anatomy, Kasturba Medical College, Manipal-576104, India. Tel: +91-9900162936 Fax: +91-820 2571927 Email: kummigames@yahoo.com

Date of submission: 2 Aug, 2013

Date of acceptance: 27 Feb, 2014

Introduction

The testicular artery (TA) is the blood vessel mainly responsible for supplying oxygenated blood to each of the testicles in males. It is sometimes called the male gonadal artery or, in older texts, the internal spermatic artery. Each testicular artery is a branch of the abdominal aorta at second lumbar vertebrae level. They are long, thin vessels running obliquely behind the peritoneum (1).

Various authors quoted 4.7% of human population showed the anomalies of TA with respect to their source of origin, course and the number of vessels (2). It may originate from abdominal aorta at a higher level than normal or from the main or accessory renal artery (3). Sometimes, it may originate from the renal artery, middle suprarenal artery, one of the lumbar arteries, common or internal iliac artery, or the superior epigastric artery (1,4,5,6). The origin of the inferior phrenic and suprarenal arteries from a testicular artery has been reported (7,8). However, the present case

describes the bilateral variations in the origin of the TA was very rare and such combination of variations were not reported earlier.

Case Report

During routine dissection for undergraduate medical students, an abnormal origin and course of the testicular artery was detected in a 65-year-old male cadaver. On the right side (Fig. 1), a common trunk arose from the anterior aspect of the abdominal aorta 0.5 cm above the level of the right renal artery (RRA) and just distal to the origin of the middle suprarenal artery. After a short course parallel to the main right renal artery, this common trunk gave few small inferior suprarenal arteries near the upper pole of the kidney. Then the major portion of the common trunk continued down as right testicular artery (RTA) descending in front of branches of the renal vessels closer to the hilum of the right kidney. Further, after running for a short course RTA was accompanied with

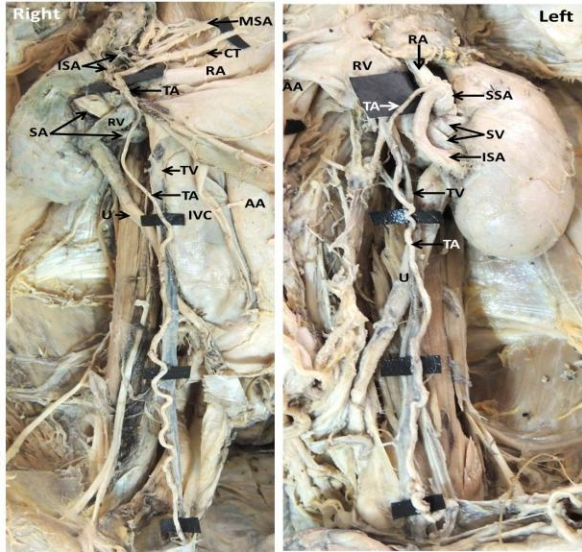


Figure 1: Dissected specimen (right side) showing common origin of testicular artery (TA) above renal artery (RA) and inferior suprarenal artery (ISR). Left side specimen showing testicular artery (TA) springs from lower pre-hilar branch (ISA) of renal artery.

right testicular vein and had normal course and relations thereafter.

However, the left main renal artery (Fig. 2) was divided into two large pre-hilar branches before entering the hilum of the left kidney. The upper branch ran above the left renal vein and entered the hilum near the upper pole and the lower branch was arched in front of the left renal vein and then entered the hilum near the lower pole of the left kidney. From the lower pre-hilar branch of the renal artery, the left testicular artery (LRA) arose close to the ramification of the main left renal artery. Then, the LRA descended in front of the left renal hilar structures and then accompanied with left renal vein to follow the normal course to reach the left testis.

In addition, both the testicular arteries were tortuous in their course on the posterior abdominal wall. No other variations were noted in the testis and testicular veins on both sides.

Discussion

Variations related to testicular arteries and veins were studied due to their importance in frequency of renal and gonadal surgeries in the recent years.

There are few reports on high origin of TA. TA was shown to arise from the abdominal aorta 1 cm proximal to the main renal artery and subdivided into an inferior phrenic artery and a superior suprarenal

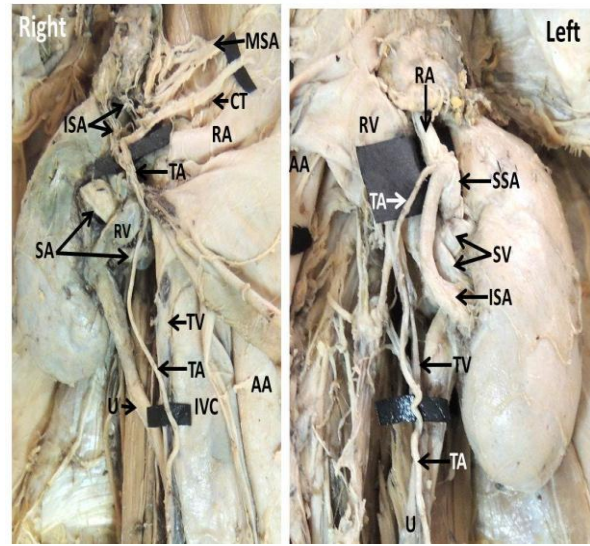


Figure 2: (High magnification view) Dissected specimen (right side) showing common origin of testicular artery (TA) above renal artery (RA) and inferior suprarenal artery (ISR). Left side specimen showing testicular artery (TA) springs from lower pre-hilar branch (ISA) of renal artery.

artery (7) or from the abdominal aorta at the level of the right renal artery and gave an inferior phrenic artery and a superior suprarenal artery (9), also, from the anterior surface of the abdominal aorta at the level of the left renal artery (10). The present case was similar to earlier reports where the right testicular artery arose from the anterior surface of the abdominal aorta just 0.5cm proximal to the origin of the right main renal artery and gave inferior suprarenal artery.

Earlier, it has also been shown that the TA was arising from the renal artery and then supplying the suprarenal gland (8). Bordoei and his colleagues mentioned the origin of inferior suprarenal artery may come from the gonadal artery or, also very rarely, from the celiac trunk (11).

Notkovitch described three types of variations of the gonadal arteries with respect to their origin from the abdominal aorta and course: gonadal artery without any contact with the renal vein; artery with higher level of origin than the renal vein, passing anterior to the renal vein and finally lower level of origin of the gonadal artery making an arch over the renal vein (12, 13). The present finding is similar to the type I pattern but with a branch to the suprarenal gland.

TA was also classified into four category based on their origin (14). Type A - a single TA originating from the aorta; Type B - a single TA originating from the renal artery; Type C - two TAs originating from

the aorta that supplied the same gonad; Type D - two TAs supplying the same gonad, one arising from the aorta and the other from the renal artery. In the present case, the right TA falls under Type A and left TA under Type B variety.

Çiçekcibasi et al. classified the TA depending on its source of origin: Type I –origin from the suprarenal artery as type I; from the renal artery as type II; high origin from the abdominal aorta, close to the renal artery as type III; and type IV, if double TA originating from the aorta or from other vessels (15). Our finding fits in to Type III and Type II for right and left testicular arteries respectively.

Much of the variations of testicular arteries can be attributed to their embryological origin. Three sets of lateral mesonephric arteries namely cranial, middle, and caudal on each side of the dorsal aorta nourishes the abdominal organs. In general, a caudal artery usually persists and differentiates into the definitive gonadal artery. Despite the fact that any of the cranial, middle and caudal mesonephric arteries can evolve to become the TA, Felix reported that the TA usually derived from the caudal group and rarely from the cranial group. However, the high-origin of the TA in our case may be due to persistence of a cranial lateral mesonephric artery (16).

TA arising from the renal artery may indicate that the gonadal artery was derived from the middle group of lateral mesonephric arteries. If TA was arising from the suprarenal artery or from higher level of the aorta, it indicates that the TA was derived from the cranial group of lateral mesonephric arteries (15).

With these views, in the present case, the right TA was derived from the cranial group and the left TA was derived from the middle group of the lateral mesonephric arteries.

Conclusion

Testicular arterial anatomy variations should be kept in mind because of its importance in testicular perfusion, as well as testicular and renal surgery (17). Variations of the TA must be carefully identified in order to preserve and prevent testicular atrophy especially during surgeries of male abdomen and pelvic regions.

References

1. Hollinshead WH. Anatomy for Surgeons. Vol. 2. New York: Harper and Row, 1971, 579–80.

2. Asala S, Chaudhary SC, Masumbuko-Kahamba N, Bidmos M. Anatomical variations in the human testicular blood vessels. *Ann Anat* 2001; 183(6): 545-9.
3. Merklin RJ, Michels NA. The variant renal and suprarenal blood supply with data on the inferior phrenic, ureteral and gonadal arteries: a statistical analysis based on 185 dissections and review of the literature. *J Int Coll Surg* 1958; 29 (1 Pt 1): 41-76.
4. Bergman RA, Thompson SA, Afifi AK. Compendium of human anatomic variation: text, atlas, and world literature. Baltimore, Munich:Urban and Schwarzenberg, 1988, 83.
5. Machnicki A, Grzybiak M. Variations in testicular arteries in fetuses and adults. *Folia Morphol (Warsz)* 1997; 56(4): 277–85.
6. Moore KL, Dalley AF. Clinically oriented anatomy. 4th edition. Philadelphia: Lippincott Williams & Wilkins, Philadelphia, 1999, 292.
7. Shinohara H, Nakatani T, Fukuo Y, Morisawa S, Matsuda T. Case with high-positioned origin of the testicular artery. *Anat Rec* 1990; 226(2): 264–6.
8. Brohi RA, Sargon MF, Yener N. High origin and unusual suprarenal branch of a testicular artery. *Surg Radiol Anat* 2001; 23(3): 207–8.
9. Onderoglu S, Yuksel M, Arik Z. Unusual branching and course of testicular artery, *Ann Anat* 1993; 175(6): 541–4.
10. Xue HG, Yang CY, Ishida S, et al. Duplicate testicular veins accompanied by anomalies of testicular arteries. *Ann Anat* 2005; 187(4): 393-8.
11. Bordei P, Antohe SD, Sapte E, Iliescu D. Morphological aspects of the inferior suprarenal artery. *Surg Radiol Anat* 2003; 25(3–4): 247–51.
12. Manso JC, DiDio LJ. Anatomical variations of the human suprarenal arteries. *Ann Anat* 2000; 182(5): 483-8.
13. Notkovich H. Variations of the testicular and ovarian arteries in relation to the renal pedicle. *Surg Gynecol Obstet* 1956; 103(4): 487–95.
14. Machnicki A, Grzybiak M. Variations in testicular arteries in fetuses and adults. *Folia Morphol* 1997; 56(4): 277-85.

15. Çiçekcibaşı AE, Salbacak A, Seker M, Ziylan T, Büyükmumcu M, Uysal II. The origin of gonadal arteries in human fetuses: anatomical variations, *Ann Anat* 2002; 184(3): 275–9.
16. Felix W. Mesonephric arteries (aa. Mesonephricae). In: Keibel F, Mall FP eds. *Manual of Human Embryology. Vol. 2.* Philadelphia: Lippincott, 1912, 820–5.
17. Tarhan S, Gümüş B, Gündüz I, Ayyıldız V, Gökten C. Effect of varicocele on testicular artery blood flow in men - color Doppler investigation. *Scand J Urol Nephrol* 2003; 37(1): 38-42.