

CASE REPORT

Tuberculosis of the Prostate Presenting as Benign Prostatic Hyperplasia

FAZARINA M¹, TAN GH², BADRULHISHAM B², SHIRAN MS³, TAN GC¹

¹Department of Pathology, ²Department of Surgery, Faculty of Medicine, Universiti Kebangsaan Malaysia Medical Centre, Jalan Yaacob Latif, Bandar Tun Razak, 56000 Cheras, Kuala Lumpur, Malaysia.

³Department of Pathology, Perdana University, Jalan MAEPS Perdana, 43400 Serdang, Selangor, Malaysia.

ABSTRAK

Sistem genitourinari ialah tapak kedua paling lazim untuk tuberkulosis (TB) selepas sistem pulmonary. Tuberkulosis prostat ialah manifestasi tuberkulosis yang jarang berlaku dalam sistem genitourinari. Ia lebih jarang berlaku pada individu yang mempunyai tahap imun yang memuaskan. TB prostat selalunya ditemui semasa reseksi transuretral prostat (TURP). Kami melaporkan kes prostat TB dalam lelaki berusia 70 tahun yang menghidap hiperplasia prostat benigna selama dua tahun. TB didiagnosa secara kebetulan selepas TURP. Dalam laporan kes ini, kami juga akan membincangkan ujian-ujian lain yang boleh dijalankan untuk mendiagnosis tuberkulosis dalam sistem genitourinari.

Kata kunci: genitourinari, prostat, tuberkulosis

ABSTRACT

Genitourinary system is the second most common site of tuberculosis (TB) after pulmonary system. Tuberculosis of the prostate is a rare manifestation of genitourinary tuberculosis. It is even more uncommon if occurring in an immune-competent individual. Prostate TB is usually an incidental finding in transurethral resection of prostate (TURP). Here, we report a case of TB of the prostate in a 70-year-old man who had benign prostatic hyperplasia for two years. TB was diagnosed incidentally post-TURP. In this report, we also discuss additional tests which may help in establishing the diagnosis of genitourinary tuberculosis.

Keywords: genitourinary, prostate, tuberculosis

Address for correspondence and reprint requests: Dr. Tan Geok Chin, Department of Pathology, Faculty of Medicine, Universiti Kebangsaan Malaysia Medical Centre, Jalan Yaacob Latif, Bandar Tun Razak, 56000 Cheras, Kuala Lumpur, Malaysia. Tel: +603-91455362 Fax: +603-91456676 Email: tan_geok_chin@yahoo.com /tangc@ppukm.ukm.edu.my

INTRODUCTION

Tuberculosis still poses a significant health problem in Malaysia. Based on WHO tuberculosis report 2013, the incidence rate of tuberculosis in Malaysia is 80/100,000 population and the mortality rate is 5.4/100,000 population (Global tuberculosis report 2013). Genitourinary system is the second most common site of TB following pulmonary system. Genitourinary tuberculosis (TB) contributes 10-41% of the extrapulmonary tuberculosis (Eastwood et al. 2001; Gupta et al. 2008). However, TB affecting the prostate is less common than renal, vesiculo-seminal and epididymal TB, as a result it may pose some difficulties in its diagnosis and management. Many cases were found incidentally following transurethral resection of prostate (Gow 1998). Here, we report a case of TB of the prostate presenting as benign prostatic hyperplasia.

CASE REPORT

A 70-year-old man was admitted for acute urinary retention. He also gave history of haematuria for the past three days. There was no history of fever, cough or weight loss. He was diagnosed to have lower urinary tract symptoms (LUTS) secondary to benign prostate enlargement (BPE). He had been treated with alfuzosin for the past two years. Rectal examination revealed an enlarged but smooth prostate. There was no history of contact with patient with tuberculosis.

The patient's peripheral blood and renal profile were normal.

Urine analysis showed presence of leucocytes (500/ul), pus cells (20-50), red blood cells (50/ul) and bacteria (1+), along with protein (0.25g/L) and glucose (3mmol/L). However, urine culture for mycobacterium tuberculosis was negative. Ultrasound revealed an enlarged prostate that measured 6 x 6 x 6 cm. Transurethral resection of the prostate was done, along with insertion of suprapubic tube. Histopathological examination of the prostate revealed tuberculous caseating granulomatous inflammation with benign prostatic hyperplasia (Figure 1). Ziehl Neelsen stain showed presence of acid fast bacilli, confirmed the diagnosis of tuberculosis (Figure 2).

He was given anti-tuberculosis treatment which consisted of ethambutol, rifampicin, isoniazid and pyrazinamide, along with vitamin B12. Subsequently, further investigations were performed to look for any pulmonary involvement of TB. Chest X-ray was clear with no evidence of tuberculosis. Sputum examination for acid-fast bacilli was also negative. Erythrocyte sedimentation rate was elevated (81 mm/hr). Incidentally, urine culture showed growth of *Klebsiella* ESBL which was sensitive towards ertapenem.

DISCUSSION

TB of the prostate is uncommon and the possible modes of involvement include descending infection from the urinary organs or hematogenous spread (Gupta et al. 2008). Based on clinical observations and animal experiments, Sporer and Auerbach (1978) suggested

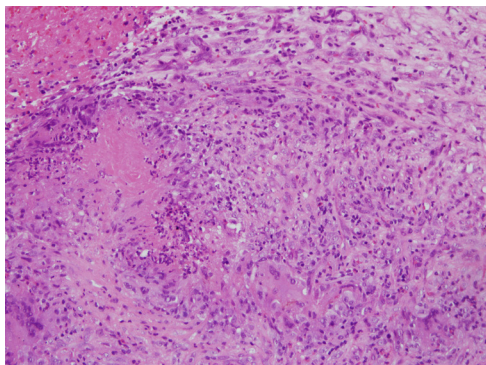


Figure 1: TURP sample showed granulomatous inflammation accompanied by central necrosis

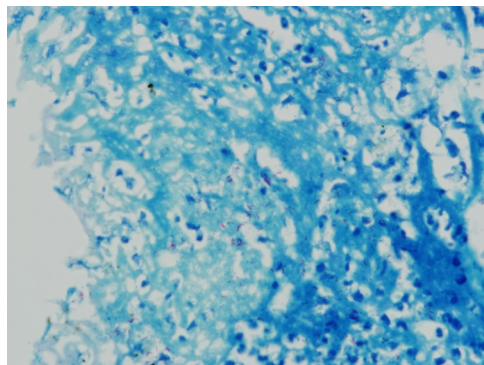


Figure 2: Zeihl Neelsen stain was positive for acid fast bacilli

that TB of the prostate is almost always the result of one or perhaps repeated hematogenous seedings. Direct extension may occur (Sporer & Auerbach 1987; Rai et al. 2009). The predisposing factors associated with the development of TB are related to poor immune status such as long-term use of steroid, the use of immunosuppressive drugs and diseases that impaired cell-mediated immunity (Gow 1998).

The diagnosis could be difficult, if there was only a microscopic focus of granuloma in a large quantity of TURP prostatic sample. Furthermore, if occurring in an immunocompetent individual without any respiratory symptoms to suggest tuberculosis, it could be missed. Hence, this represents a diagnostic pitfall for histopathologists. Indeed, it is a differential diagnosis to be kept in mind, especially in endemic countries.

Culture is the gold standard for diagnosis of genitourinary tuberculosis. Tissue and urine may be obtained for culture for mycobacterium tuberculosis. However, tissue samples are rarely sent for culture, unless there is a suspicion

of tuberculosis. A study by Mortier et al. (1996) suggested that urine sampling for mycobacterium tuberculosis culture is useful for genitourinary tuberculosis exhibiting signs and symptoms of the disease. It is possible to perform Ziehl-Neelsen (ZN) staining of urine. However, the test requires certain amount of bacteria present in order to yield a positive result. It has a high specificity (100%) but low sensitivity (25%) (Ghaleb et al. 2013).

It is also possible to perform polymerase chain reaction (PCR) using tissue and urine to detect tuberculosis. Study by Chawla et al. (2012) showed that tissue and urine PCR results are coinciding with histopathological results. Tissue and urine PCR have a sensitivity of 87.5% and a specificity of 86.7% with some variations. However, urine PCR may not be useful in isolated involvement of the prostate, penis and the seminal vesicles (Chawla et al. 2012).

In conclusion, there are various ancillary tests that may be used to detect mycobacterium tuberculosis in order to establish its diagnosis. Culture and ZN stain are the most widely available tests

offer by most laboratories, while PCR is technically more demanding, offers usually by laboratory with molecular diagnostic facility. Lastly, tuberculosis of the prostate is possible even in an immunocompetent individual. It should be a differential diagnosis in men who present with lower urinary tract symptoms, if they lived in areas where TB is endemic.

REFERENCES

- Chawla, A., Chawla, K., Reddy, S., Arora, N., Bairy, I., Rao, S., Hegde, P., Thomas, J. 2012. Can Tissue PCR Augment the Diagnostic Accuracy in Genitourinary Tract Tuberculosis? *Urol Int* **88**(1): 34–8.
- Eastwood, J.B., Corbishley, C.M., Grange, J.M. 2001. Tuberculosis and the kidney. *J Am Soc Nephrol* **12**(6): 1307-14.
- Ghaleb, K., Afifi, M., El-Gohary, M. 2013. Assessment of diagnostic techniques of urinary tuberculosis. *Mediterr J Hematol Infect Dis* **5**(1): e2013034.
- Global Tuberculosis Report. 2013. *World Health Organization Press*. Switzerland. <http://www.who.int/tb/country/en/index.html>. [8 February 2014].
- Gow, J.G. 1998. Genitourinary tuberculosis. In: *Campbell's Urology*. 7th edition. Edited by Walsh PC, Retik AB, Vaughan EA, Wein AJ. Philadelphia: WB Saunders; 817-8.
- Gupta, N., Mandal, A.K., Singh, S.K. 2008. Tuberculosis of the prostate and urethra: A review. *Indian J Urol* **24**(3): 388-91.
- Mortier, E., Pouchot, J., Girard, L., Boussougan, Y., Vinceneux, P. 1996. Assessment of urine analysis for the diagnosis of tuberculosis. *BMJ* **312**(7022): 27–8.
- Rai, A., Pahwa, H., Jain, V., Misra, S. 2009. Management of Genito-Urinary Tuberculosis. *The Internet Journal of Surgery* **23**(1): DOI: 10.5580/173a.
- Sporer, A., Auerbach, O. 1978. Tuberculosis of prostate. *Urology* **11**(4): 362–5.