

[Manuscript received 28th October, 1970

HISTOLOGICAL AND HISTOCHEMICAL OBSERVATIONS OF THE CEPHALIC NEUROSECRETORY SYSTEM OF THE CRAB, *PARAGRAPSUS GAIMARDII* (H. MILNE EDWARDS)

By

P. S. LAKE,

Department of Zoology, University of Tasmania

(With full plates of five text figures)

ABSTRACT

Anatomical, cytological and histochemical features of the neurosecretory system of the crab, *Paragrapsus gaimardii* are described. In the brain and the commissural ganglia, three types of neurosecretory cells are distinguished. The distribution of these cells in the brain and the commissural ganglia is described. In the eyestalk, four types of neurosecretory cells are identified and the distribution of these cells is described. The neurosecretory cells of the brain, the commissural ganglia, and of the eyestalks are all paraldehyde fuchsin — positive (PF-positive). Their tinctorial properties with the chrome-haematoxylin phloxine technique are described. The neurohaemal organ of the eyestalk, the sinus gland, is described both as regards its anatomical characters and its staining properties. The presence of allochthonous cells in the sinus gland is revealed. The allochthonous neuroglial cells of the sinus gland do not appear to be active gliosecretory cells. However, some of the neuroglial cells of the brain, especially those of the protocerebrum, do appear to be active gliosecretory cells. The neurosecretory material of the cephalic neurosecretory system of *P. gaimardii* is proteinaceous with disulphide groups being markedly present.

INTRODUCTION

The neurosecretory cells and organs of the eyestalk of crabs have attracted considerable attention from both histologists and physiologists. Studies of the structure and cytology of the neurosecretory system of the crab eyestalk have been made by Hanström (1937, 1947), Enami (1951), Bliss and Welsh (1952), Bliss, Durand and Welsh (1954), Potter (1954, 1958), Miyawaki (1956a, c, 1960), Matsumoto (1958), Valente (1959) and Szudardky (1963). Similarly, a number of studies have been made of the neurosecretory cells of the cerebral ganglion (Enami 1951, Bliss and Welsh 1952, Bliss, Durand and Welsh 1954, Parameswaran 1956, Inoue 1957, Matsumoto 1958, Miyawaki 1960, Szudardky 1963 and Baid, Hafidh and Dabagh 1967). Histochemical observations on the nature of the neurosecretory material in crabs have been made by Gabe (1952), Miyawaki (1956b, c, 1960) and Rehm (1959).

In view of the importance of neurosecretion in controlling many major aspects of the physiology of crabs and in view of the lack of clear correlations in the

types of neurosecretory cell types so far described in various species of crabs, the cerebral and optic ganglia of *Paragrapsus gaimardii* were examined histologically as a preliminary step to further studies of the neurosecretory system.

MATERIALS AND METHODS

Mature male or female *P. gaimardii*, in the stage of Intermoult (C3-C4 of Drach 1939) and with a carapace width ranging from 15 to 36 mms. were used in this study. The cerebral ganglion and the optic ganglion were dissected out in the fixative. In the case of the eyestalks, prior to their removal, fixative was injected into the eyestalk from the proximal end, using a hypodermic syringe with a No. 26 needle. The majority of ganglia were fixed in Masson's Bouin (Foot 1933) or in 4% Formalin (Baker 1958). The tissues were dehydrated in ethanol, cleared in methyl benzoate, often with 1% celloidin added, and embedded in Paraplast (M.P. 56°C). Serial sections, 7 or 8 μ thick, were cut and mounted on glass slides.

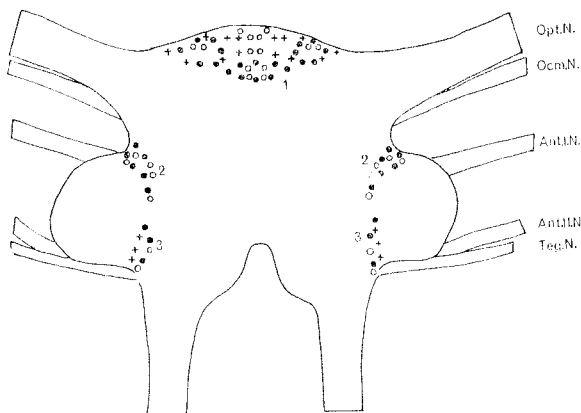


Fig. 1.—Diagram of the dorsal side of the brain of *P. gaimardii* indicating the location and the distribution of the neurosecretory cells. Opt. N., optic nerve; Ocm. N., oculomotor nerve; Ant. I. N., first antennary nerve; Ant. II. N., second antennary nerve; Teg. N., tegumentary nerve; +, large monopolar neurosecretory cells; o, small monopolar neurosecretory cells. Magnification x approximately 20.

Complete series of serial sections of either the brain or the eyestalks were stained with one of the following procedures:

- (a) Paraldehyde fuchsin (PF). (Ewen 1962).
- (b) Chrome-haematoxylin phloxine. (CHP). (Bargmann 1949).
- (c) Mallory's Triple. (Pantin 1946).
- (d) Azan. (Hubschman 1962).

The histochemical tests carried out on serial sections of either brain or optic ganglia included:

- (a) the alloxan-Schiff technique for protein-bound amino groups after Yasuma and Ichikawa (1953).
- (b) the performic acid-alcian blue technique for disulphide groups after Adams and Sloper (1956).
- (c) the permanganate oxidation-alcian blue technique for disulphide groups after Arvy and Gabe (1962).
- (d) the dihydroxy-dinaphthyl-disulphide (DDD) technique for sulphhydryl groups after Barrnett and Seligman (1952, 1954).
- (e) the periodic acid-Schiff (PAS) technique after Hotchkiss and McManus (cf. Barka and Anderson 1963) for 1,2-glycol groups and a variety of other materials. Complete series of serial sections were treated with either (1) the standard method for PAS-reactive groups or (2) diastase digestion (2 hours at 26°C) followed by the standard method for the detection of glycogen.
- (f) the alcian yellow-alcian blue technique for strongly acidic disulphide groups and weakly acidic glycol groups after Van De Kamer (1967).

The photographs were taken on a Wild Photoautomat fitted to a Wild M-20 microscope using either Kodak Plus-X Pan film or Ilford Pan F film.

RESULTS

In the brain and the commissural ganglia, there are three basic types of neurosecretory cells. The first type of cells are the large monopolar cells (Plates 1 and 2).

These cells are oval in shape and they have mean diameter of $59.76 \pm 8.60 \mu$. The cytoplasm of these cells is finely granular and shows an affinity for the Light Green component of the PF counterstain. In the cytoplasm, there are fine, purple PF-positive granules which reach their greatest concentration around the nucleus. In some cells, especially in the protocerebrum, vacuoles up to 16μ across may occur in the outer part of the cytoplasm. These cells do not, in general, stain intensely with the PF technique but do possess distinct granules, suggestive of neurosecretory activity. The nuclei are oval, with a mean diameter of $21.16 \pm 3.30 \mu$. With the PF technique, the nuclei are lightly stained with a greenish tinge. Only one nucleolus appears to occur per nucleus. The nucleoli are large, up to 5μ in diameter and are Orange G - positive. The reactions of these cells to the three other histological stains are given in Table 1.

The medium neurosecretory cells of the brain are the most common type of neurosecretory cell in the brain (Plate 1). These cells are monopolar and are oval to elliptical in outline. They have a mean diameter of $36.96 \pm 14.46 \mu$. The oval nuclei have a mean diameter of $16.27 \pm 2.81 \mu$. There may be either one or two nucleoli. The cytoplasm of these cells is often coarsely granular and may have a great density of coarse, purple neurosecretory granules, notably concentrated around the nucleus. The nuclei have an affinity for Light Green and the nucleoli are stained orange with the PF technique. Small vacuoles up to 7μ across are sometimes observed near the periphery of these cells. The reactions of these cells to the other histological techniques are given in Table 1.

The small neurosecretory cells are monopolar and are generally oval in shape. They have a mean diameter of $23.75 \pm 2.74 \mu$ and the oval nuclei have a diameter of $13.79 \pm 1.50 \mu$. With the PF technique, the ground substance of the cytoplasm is stained a pale green, and within this, there occur distinct purple secretory granules.

TABLE 1.

Reactions of the neurosecretory cells of the brain and the commissural ganglia to the Chrome-haematoxylin phloxine technique (CHP), the Azan technique and Mallory's Triple technique.

Cells	Technique	Cytoplasm	Neurosecretory material	Nucleus	Nucleoli
Large Cells	CHP	pale red	purple	pink	red
	Azan	pale blue	grey-blue	pale red	red
	Mallory's Triple	reddish-purple	purple	pale purple	red
Medium cells	CHP	clear pink	purple to black	orange	red
	Azan	blue	grey-blue	brown	brick red
	Mallory's Triple	pink-purple	purple	pale red	red
Small cells	CHP	red	purple-black	pale red	red
	Azan	purple	reddish-purple	red	brick red
	Mallory's Triple	blue to reddish-purple	purple	pale purple	red

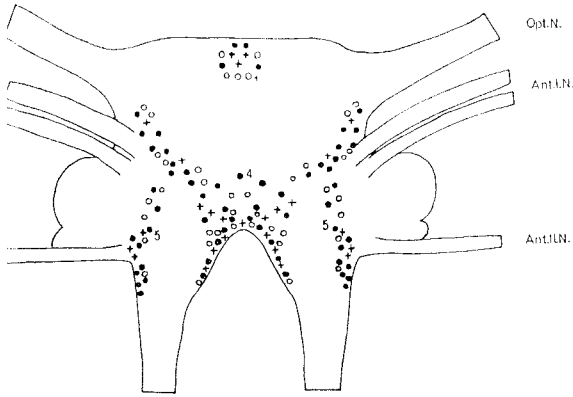


Fig. 2.—Diagram of the ventral side of the brain of *P. guimardii*, indicating the location and distribution of the neurosecretory cells. Opt. N., optic nerve; Ant. I. N., First antennal nerve; Ant. II. N., Second antennal nerve; +, large monopolar neurosecretory cells; ●, medium monopolar neurosecretory cells; ○, small monopolar neurosecretory cells. Magnification \times approximately 20.

A few small vacuoles, up to $4\ \mu$ across are sometimes observed in these cells. With the PF technique, the nuclei stain a pale green, while the nucleoli are red. For reactions of these cells to the other histological stains see Table 1.

Some neuroglial cells in the brain appear to be active secretory cells (Plate 3). The secretion appears as clustered deep purple granules, when stained with the PF technique. The secretory glial cells are predominantly located in and around the median group of protocerebral neurosecretory cells (Group 1), though some are also located in and near Group 4 of the brain. The pathway(s) by which such secretion is discharged is unknown, though there are indications that secretory granules from the protocerebral group of neuroglial cells are transported along the optic nerve. The neuroglial cells have oval nuclei which stain a pale blue with the PF technique.

The principal region of neurosecretory cells on the dorsal side of the brain is the median group of cells in the protocerebrum (Group 1): (Figure 1). This region contains a considerable number of large neurosecretory cells. The regions of neurosecretory cells around the olfactory lobes of the brain, although continuous, can be divided into two groups, the anterior group (Group 2) and the posterior group (Group 3) for each side of the dorsal aspect of the brain.

The ventral aspect of the brain is notably richer in neurosecretory cells (Figure 2). Anteriorly, neurosecretory cells are present in the continuation to the ventral surface of the median protocerebral group of cells (Group 1). The most prominent area for the localization of neurosecretory cells on the ventral side of the brain is the central group (Group 4). This central group extends posteriorly to where the circum-oesophageal connectives leave the brain. Anteriorly and posteriorly of the base of the second antennal nerve, a small region of neurosecretory cells (Group 5) is located. The tritocerebral commissural ganglia are situ-

ated on the circum-oesophageal connectives. They occur as ganglionic swellings anterior to the tritocerebral commissures. In the ganglia, both medium and small neurosecretory cells are found (Figure 3). The greatest concentration of these cells occurs on the dorso-lateral margins of the anterior sides of the ganglia.

Neurosecretory Cells of the Eyestalk

In the eyestalk, four types of neurosecretory cells are identified. The large monopolar neurosecretory cells of the eyestalk are oval in outline and have a mean diameter of $45.15 \pm 4.90\ \mu$ (Plate 4). The cytoplasm of these cells varies in texture. In many of these cells, the cytoplasm is granular with fine purple secretory granules in the cytoplasm and in such cases the granules are not so markedly concentrated around the nucleus (Plate 4). Other cells of this type may have coarser granules in the cytoplasm and in such cases the granules are frequently in such cells, vacuoles are present near the peripheries of the cells. Like the large monopolar cells of the brain, the ground substance of the cytoplasm of the eyestalk cells, shows an affinity for Light Green. The nuclei are oval and have a mean

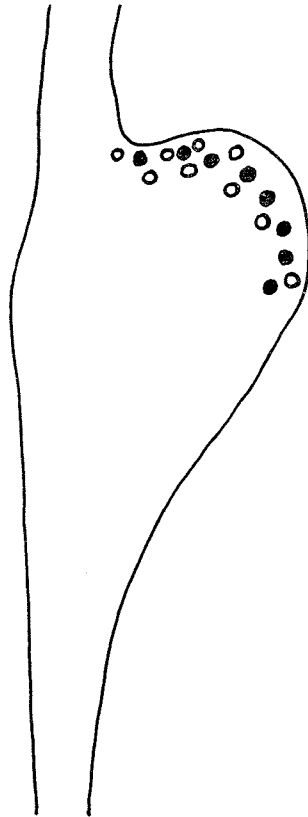


Fig. 3.—Dorsal view of a tritocerebral commissural ganglion, showing the position of the neurosecretory cells. ●, medium monopolar neurosecretory cells; ○, small monopolar neurosecretory cells. Magnification \times approximately 120.

TABLE 2.

Reactions of the neurosecretory cells of the eyestalks to the Chrome-haematoxylin phloxine technique (CHP), the Azan technique and Mallory's Triple Technique.

Cells	Technique	Cytoplasm	Neurosecretory Material	Nucleus	Nucleoli
Large cells	CHP	pink	purple	pale red	red
	Azan	blue	purple	brick red	pale red
	Mallory's Triple	maroon	purple	red-maroon	red
Medium oval cells	CHP	pale pink	purple	pale red	red
	Azan	grey	blue	brick red	red
	Mallory's Triple	maroon	purple	red	red
Medium elongated cells	CHP	pink	purple	red	red
	Azan	blue-grey	blue	purple	pale red
	Mallory's Triple	maroon	blue-purple	purple	red-purple
Small cells	CHP	pale pink	purple-black	red	deep red
	Azan	blue	blue-purple	magenta	pink
	Mallory's Triple	pale purple	purple	deep red	red

diameter of $18.47 \pm 2.67 \mu$. There is one nucleolus per nucleus. The nucleoli are large, up to 5μ in diameter and are stained orange with the PF technique.

The medium monopolar neurosecretory cells of the eyestalk are of two different types. The medium oval cells of the eyestalk are more prevalent than the medium elongated cells of the eyestalk.

The medium oval cells have a mean diameter of $28.95 \pm 3.12 \mu$. Their cytoplasm is stained a light green with the PF technique, and has in it fine purple secretory granules. Some cells have vacuoles in the cytoplasm and when this vacuolated condition occurs, the secretory granules are coarse. The nuclei have a diameter of $15.27 \pm 1.67 \mu$ and are generally stained a pale green. There is one nucleolus per nucleus.

The medium elongated neurosecretory cells are generally pear-shaped in outline. The mean length of these cells is $29.68 \pm 2.46 \mu$, while the mean width of these cells is $15.82 \pm 1.81 \mu$. The cytoplasm is finely granular and stained a light green. In the cytoplasm both fine and coarse purple secretory granules occur. The nuclei are oval in outline and have a mean diameter of $14.94 \pm 1.73 \mu$. One small nucleolus occurs per nucleus.

The small monopolar cells of the eyestalk are oval to elongated in outline. They have a mean diameter of $18.26 \pm 2.82 \mu$. The cytoplasm is stained a pale green with the PF technique, with a limited number of purple secretory granules in the cytoplasm. The nuclei are Light Green-positive and have a mean diameter of $12.35 \pm 1.71 \mu$.

The reactions of these four types of cells to the three other histological staining techniques are given in Table 2.

The principal neurohaemal organ of the eyestalk, the sinus gland is located in the dorsal posterior side of the optic ganglia, adjacent to the Medulla Interna (Plate 5).

The sinus gland is a flattened ovoid in shape with the flattening occurring in the dorso-ventral plane. In transverse cross section, the sinus gland is a flattened ellipse in shape. The central part of the gland is occupied by the blood sinus. The swollen axonal endings containing the neurosecretory material are separated from the blood sinus by a thin basement membrane, which is stained dark green with the PF technique. In mature animals, the sinus gland is about 300μ long, while in transverse section it is about 120μ wide.

The size of the granules present in the sinus gland varies considerably with a consistent gradient from the external to the internal surfaces of the organ. The larger granules, in the outer part of the gland, are approximately 6 to 7μ in diameter and are stained a deep purple with the PF technique. Smaller purple granules, 0.5 to 1μ in diameter, are located near the internal surfaces of the gland. Close to the internal surfaces of the gland, the secretory granules are very fine. There is a difference in the staining properties of the secretory material between the outer and the inner parts of the gland. The large granules stain a deep purple with the PF technique. Smaller purple granules, are stained greenish-blue to a deep green. Near the basement membrane homogeneous, light green secretory material is also found. The changes in the staining properties of the secretory material in the sinus gland may indicate changes in the chemical nature of the neurosecretory material prior to or at the site of release. When stained with the CHP technique, large lilac globules are observed. Scattered purple globules are also present close to the internal surfaces of the gland, while very strongly phloxophilic granules are located in the outer parts of the gland.

Three types of secretory materials were observed in the sinus gland, when the Mallory's Triple staining procedure was used. The predominant type of secretory

TABLE 3.

Reactions of the secretory materials of the neurosecretory cells of the brain and the eyestalks and of the sinus gland to the various histochemical tests.

Test	Brain			Eyestalks				Sinus gland	
	Large cells	Medium cells	Small cells	Large cells	Medium oval cells	Medium elongated cells	Small cells	Region A	Region B
Alloxan-Schiff	+	+	+	+	++	+	+	++++	++
PFAAB									
POAB	+	++	+	+	++	++	+	+++++	++
DDD	+	+	+	+	±	+	±	+	-
PAS	+	++	+	+	±	±	-	-	+
PAS-diastase	-	-	-	-	-	-	-	-	-
Alcian yellow-									
Alcian Blue	Blue	Blue	Pale blue	Blue	Blue	Blue	Pale blue	Green-yellow	Green-blue

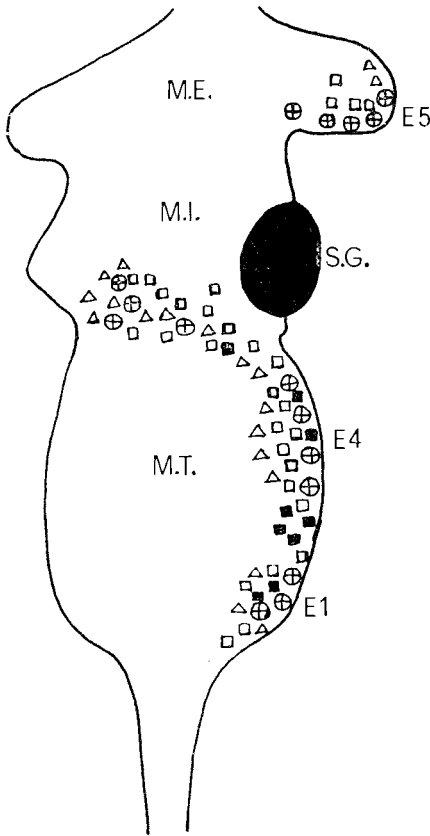


Fig. 4.—Dorsal view of the right eyestalk of *P. gaimardii*, showing the location and distribution of the neurosecretory cells and the sinus gland (S.G.) ⊕, large monopolar neurosecretory cells; ◻, medium monopolar neurosecretory cells; ■, medium elongated neurosecretory cells; Δ, small monopolar neurosecretory cells; M.E., medulla externa; M.I., medulla interna; M.T., medulla terminalis. Magnification \times approximately 35.

material stains with the acid fuchsin component. Near the basement membrane of the gland, fine purple and small orange granules are present.

With the Azan technique, the predominant type of secretory material is in the form of large brick-red granules with some orange granules within this material. Near the basement membrane, fine purple and blue granules are found. There is a change from the purple to the blue colour with decreasing distance from the basement membrane.

The sinus gland tract is clearly visible in sections, leading into the sinus gland. Near the gland it is approximately 35μ wide. Within the tract there are aggregations of large fuchsinophilic granules, though the intensity of their colour is not as intense as that of the large purple granules in the sinus gland.

The presence of allochthonous cells in the sinus gland was revealed by staining their nuclei with the Feulgen reaction after fixation of the eyestalk in neutral formalin.

The cells were largely confined to the outer half or so of the sinus gland and reached their greatest density near the outer surface of the gland. The most common type of nucleus encountered was oval in shape and had a diameter of approximately 8μ . Close to the outer surface of the sinus gland a second type of nucleus was encountered. These nuclei were also small but were elongated in shape. The oval nuclei may be the nuclei of neuroglial cells, while the elongated nuclei may be the nuclei of connective tissue cells associated with the connective tissue sheath of the sinus gland. The neuroglial cells of the sinus gland do not appear to be active secretory components as observed by Adiyodi (1969).

The sinus gland lies on the dorsal surface of the optic ganglia, opposite the Medulla Interna (Figure 4). A group of neurosecretory cells is found in the Medulla Externa occupying the dorsal and ventral posterior side of this region, near the junction of the Medulla Externa and the Medulla Interna (Figures 4 and 5). In the Medulla Interna, near the sinus gland, on the dorsal surface there is an extension of neurosecretory cells from Group E4 of the Medulla Terminalis, while on

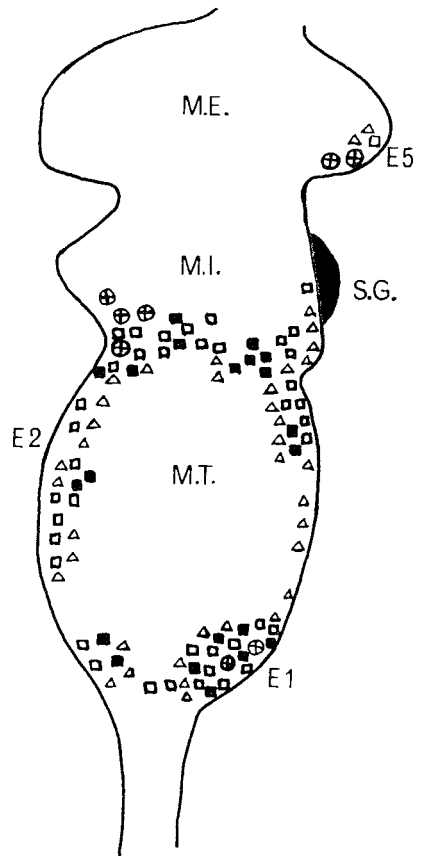


Fig. 5.—Ventral view of the right eyestalk of *P. gaimardii*, showing the location and distribution of the neurosecretory cells and the sinus gland (S.G.) Symbols, legend and magnification identical to that of Figure 4.

the ventral posterior surface of the Medulla Interna, Group E4 also extends from the Medulla Terminalis. On the ventral anterior surface of the Medulla Interna, neurosecretory cells extend from Group E2 of the Medulla Terminalis.

Three groups of neurosecretory cells are found in the Medulla Terminalis, making this the most notable region for neurosecretory cells in the eyestalk. On the ventral anterior surface of the Medulla Terminalis, Group E2 is located, while on the posterior ventral surface, Group E4 extends back proximally to join with Group E1. Group E1 is located on the proximal margins of the Medulla Terminalis and constitutes the Medulla Terminalis Ganglionic X-organ.

Histochemical Observations of the Neurosecretory cells of the Brain and the Eyestalk and of the Sinus Gland.

In this series of observations, the sinus gland is divided into two regions. Region A constitutes that region containing rather large granules, 6-7 μ in diameter, while Region B constitutes that region of the sinus gland adjoining the basement membrane and containing the fine secretory granules. The results of the reactions in the neurosecretory cells are for the secretory material only. The results of the tests are given in Table 3.

Alloxan-Schiff. This test for protein-bound amino groups is recommended by Barka and Anderson (1963) as a general protein staining technique. Proteins are stained from pink to red. In general, the secretory material of the neurosecretory cells of the brain and the eyestalks was only mildly stained, while that of the sinus gland was stained a deep red indicating the presence of significant amounts of protein.

Performic acid Alcian Blue and Permanganate-oxidation Alcian Blue.

The results of both of these tests for disulphide groups are basically similar. As in the alloxan-Schiff test, the sinus gland proved to be the most active neurosecretory region.

DDD Reaction. This reaction indicates the presence of sulfhydryl groups. Using Fast Blue B as the diazonium salt, the presence of high concentrations of -SH groups is indicated by a violet-blue or blue colour. However, in this study, regions of high reactivity were indicated only by a red colour.

Periodic acid-Schiff. This test demonstrates the presence of carbohydrates and a number of related substances, such as some neutral mucopolysaccharides, some glycolipids and glycoproteins. Used in conjunction with diastase digestion pre-treatment, the PAS technique may demonstrate the presence of glycogen. From the results of the PAS and the PAS-diastase tests, it appears that the reactivity of granular material in the cells and in the sinus gland is largely due to the presence of glycogen.

Alcian Yellow-Alcian Blue. This test distinguishes between weakly acidic glycol groups and the strongly acidic S-S groups in proteins. The weakly acidic glycol groups in neurosecretory material are stained blue and the strongly acidic S-S groups are stained yellow. The neurosecretory material in *P. gaimardii* in the cell perikarya contains a predominance of weakly acidic glycol groups while that in the sinus gland contains a predominance of strongly acidic S-S groups.

DISCUSSION

In the brain and tritocerebral commissures of the crab, *Paragrapsus gaimardii*, three types of neurosecretory cells could be distinguished. The number of types of neurosecretory cells detected in the brain of brachyurans investigated to date, varies from one to three. Only one distinct type of neurosecretory cell was reported by Szudardky (1963), while two types have been reported by Enami (1951), Parameswaran (1956), Miyawaki (1960) and Baid, Hafidh and Dabagh (1967). Three types of cells have been reported by Inoue (1957) and Matsumoto (1958).

The large monopolar cells of the brain of *P. gaimardii* may correspond to the α neurosecretory cells of Enami (1951), the A cells of Parameswaran (1956), Inoue (1957) and of Matsumoto (1958), the median cells of Miyawaki (1960) and the B3 cells of Szudardky (1963). The medium cells of the brain of *P. gaimardii* may correspond with the β cells of Enami (1951), the B cells of Parameswaran (1956), Inoue (1957) and Matsumoto (1958) and the B2 cells of Szudardky (1963). The small cells of the brain of *P. gaimardii* may similarly correspond to the γ neurosecretory cells of Enami (1951), the D cells of Inoue (1957), the E cells of Matsumoto (1958), the small cells of Miyawaki (1960) and of Baid, Hafidh and Dabagh (1967).

The regions where neurosecretory cells occur in the brain are basically similar to those reported for *Sesarma dehaani* by Enami (1951), for *Pachygrapsus crassipes* by Inoue (1957) for *Paratelphusa hydrodromous* by Parameswaran (1956) for *Potamon dehaani* and *Neptunus trituberculatus* by Matsumoto (1958) and for *Rhithropanopeus harrisi* by Szudardky (1963). The routes of axonal transport of the neurosecretory material synthesized in the neurosecretory cells of the brain of *P. gaimardii* are not clearly known, though there are indications that neurosecretory material is transported along the optic nerve from cells in Groups 1 and 2. This is similar to the results of Bliss and Welsh (1952) and Bliss, Durand and Welsh (1954).

The phenomenon of gliosecretion is noticeable in the brain of *P. gaimardii*. Indeed gliosecretion appears to be a more active process in the brain than in the optic ganglia. The routes of discharge or transport of the gliosecretion in *P. gaimardii* are not known. Gliosecretion has been reported in crabs by Szudardky (1963) and by Adiyodi (1969). Adiyodi (1969) observed that the gliosecretion underwent cyclical changes in relation to the moulting cycle, being most abundantly present in adult female *Paratelphusa hydromous* in the late C3 and early C4 stages (Intermoult) of the moult cycle. These were the stages in which *P. gaimardii* was examined. It is interesting to note that the phenomenon of gliosecretion by the allochthonous cells of the sinus gland as reported by Adiyodi (1969) was not clearly evident in *P. gaimardii*.

In the eyestalk of *P. gaimardii*, four types of neurosecretory cells were detected. The two types of medium neurosecretory cells are generally similar in their staining properties but differ notably in their shape. In the eyestalk of crabs, investigators have distinguished a number of different types of cells. The number of types varies

from two (Miyawaki 1956a, 1960) to six (Potter 1958, Matsumoto 1958). Although, as in the case of the neurosecretory cells of the brain, it is difficult to relate the neurosecretory cells of the eyestalk of *P. gaimardii* to those reported in the eyestalk of other crabs by other authors, some similarities can be discerned. The large cells of the eyestalk of *P. gaimardii* may correspond to the β cells of Enami (1951), the giant cells of Miyawaki (1956a) the α and the β cells of Matsumoto (1958) the Type I and Type II cells of Potter (1958), the median cells of Miyawaki (1960), the α cells of Valente (1959) and the B3 cells of Szudardky (1963). The medium oval and medium elongated neurosecretory cells of *P. gaimardii* may correspond to the α cells of Enami (1951), the B cells of Matsumoto (1958) and the B2 cells of Szudardky (1963). The medium elongated cells are also similar to the δ cells of Matsumoto (1958). The small cells of the eyestalk of *P. gaimardii* may be similar to the γ cells of Enami (1951), and of Matsumoto (1958), the Da Fano cells of Miyawaki (1956a), the Type IV cells of Potter (1958), the small cells of Miyawaki (1960) and the B1 cells of Szudardky (1963).

The distribution of the neurosecretory cells in the eyestalk of *P. gaimardii* resembles that figured for the crab, *Gecarcinus lateralis* (Bliss and Welsh 1952, Bliss Durand and Welsh 1954), except that Group E1 in *P. gaimardii* is fused with Group E4. This condition is somewhat similar to that reported for *Sesarma intermedia* by Matsumoto (1958). The E5 Group of cells reported by Matsumoto (1958) is present in *P. gaimardii* but Group E6 is absent.

The presence of different types of neurosecretory materials in the sinus gland of crabs has been reported by a number of investigators (Enami 1951, Bliss, Durand and Welsh 1954, Potter 1954, 1958, Rehm 1959, Szudardky 1963). In intermoult *P. gaimardii*, using the PF technique, three types of secretory materials were observed. The predominant type of secretory material is basophilic and occurs as large globules, while near the basement membrane two types of acidophilic material are present. Three types of secretory materials are also detectable in the sinus gland, using the CHP, Mallory's Triple and the Azan techniques. A multiplicity of secretory material types, as reported by Potter (1958), both in the cells of the Medulla Terminalis X-organ and in the sinus gland was not observed in *P. gaimardii*. The PF-positive secretory material in the sinus gland of *P. gaimardii* may correspond to that of the A and AB endings of *Carcinus maenas* (Rehm 1959) and to the fuchsinophilic material of *Rhithropanopeus harrisi* (Szudardky 1963). The acidophilic material near the basement membrane of the sinus gland may likewise correspond to the B and D endings of Rehm (1959).

Whether there is a change in the chemical nature of the neurosecretory material in the process of storage or of release or of both, as has been suggested by Enami (1951), and by Szudardky (1963), cannot at present be ascertained for *P. gaimardii*. However, it is clear from this study and from an earlier one (Lake 1969), that a considerable modification in the histochemical properties of the neurosecretory material during the process of axonal transport does occur in *P. gaimardii*.

The presence of allochthonous cells in the sinus gland of *P. gaimardii* is established. These cells are of two basic types; those on the periphery of the sinus gland and which may be connective tissue cells and those within the sinus gland itself, which may be neuroglial cells. The neuroglial or 'allochthonous' cells of the sinus gland have been suggested by Enami (1951) and Miyawaki (1956a) to produce secretory material, or to be involved in the process of release of secretory material (Hodge and Chapman 1958) or to be involved in the process of both elaboration and transformation of the secretory material (Gabe 1966). Adiyodi (1969) has recently produced evidence for the idea that allochthonous cells of the sinus gland actively elaborate and release their own secretory products.

The presence of allochthonous cells or neuroglial cells in the sinus gland of crabs has been shown at the electron microscope level by Hodge and Chapman (1958) and Meusy (1968) and in crayfish by Shivers (1967) and Bunt and Ashby (1967). It is interesting to note that Meusy (1968) observed that the cytoplasm of the neuroglial cells was very rich in glycogen. This abundance of glycogen may correspond to the gliosecretion or part of the gliosecretion reported by Adiyodi (1969).

The histochemical tests applied to serial sections of the cephalic neurosecretory system of *Paragrapsus gaimardii* reveal that the neurosecretory material is a protein (alloxan-Schiff), rich in S-S groups (Performic acid-Alcian blue and permanganate oxidation-Alcian Blue), with some SH groups present (DDD). The PAS test reacts with granular material in the perikarya of neurosecretory cells and this reaction is abolished by pre-treatment with diastase. Thus weakly acidic 1,2 glycol groups may be present in the neurosecretory material, especially when the material is in the cell perikarya but not when it is in the neurohaemal organ. The presence of PAS-positive material in the neurosecretory cells of crabs has been observed by Miyawaki (1956b, c) and by Gabe (1952, 1966). As is the case in *P. gaimardii*, Miyawaki (1956c) found that the degree of PAS-reactivity was greater in the cell perikarya than in the neurohaemal sites (sinus gland). The PAS-positive material in *Telmessus cheiragonus* was metachromasia-negative and diastase-resistant (Miyawaki 1956c). Miyawaki (1956b, c) concluded that the PAS-positive material was probably a neutral mucopolysaccharide or a mucoprotein. The PAS-positive material in *P. gaimardii* is not diastase-resistant. Glycol groups may be associated with the neurosecretory material or alternatively as in other cells of the cerebral nervous system, glycogen is commonly present in neurosecretory cells.

That the neurosecretory material of crustaceans is a protein, rich in disulphide groups has been suggested from histochemical evidence by Rehm (1959), and Lake (1969, 1970). Using chromatographic techniques, Otsu (1965) and Otsu and Sonobe (1965) have produced evidence to indicate that chromactivating substances from the brain and the thoracic ganglion of the crab *Eriocheir japonicus*, are polypeptides, of 10 to 13 amino acids, including cystine and rich in S-S Bonds.

ACKNOWLEDGEMENTS

I am grateful for the technical assistance of Mrs L. Lowrey and Mr B. Dixon as well to the assistance of Mr R. Mawbey and Mr T. L. Sward in collecting some of the crabs used in this study. I would like to thank Dr I. S. Wilson for valuable criticism and discussion of the manuscript. This study was supported by a University of Tasmania Research Grant.

REFERENCES

- ADAMS, C. W. M., and SLOPER, J. C., 1956: The hypothalamic elaboration of posterior pituitary principles in man, the rat and dog. Histochemical evidence derived from a performic acid-alcian blue reaction for cystine. *J. Endocrinol.*, vol. **13**, pp. 221-8.
- ADIYODI, R. G., 1969: Gliosecretion in the crab, *Paratelphusa hydrodromous* (Herbst.). *Gen. Comp. Endocrinol.*, vol. **13**, pp. 306-8.
- ARVY, L., and GABE, M., 1962: Histochemistry of the neurosecretory product of the Pars Intercerebralis of Pterygote insects. In *Neurosecretion* (edited by H. Heller and R. B. Clark), pp. 331-44. Academic Press, New York.
- BAID, I. C., HAFIDH, R. A., and DABAGH, S., 1967: Studies on the neurosecretory cells in the cerebral ganglion of *Potamon magnum magnum* (Pretzman). *Experientia*, vol. **23**, p. 564.
- BAKER, J. R., 1958: *Principles of Biological Technique*. Methuen and Co., London.
- BARGMANN, W., 1949: Über die neurosekretorische Verknüpfung von Hypothalamus und Neurohypophyse. *Z. Zellforsch.*, vol. **34**, pp. 610-34.
- BARKA, T., and ANDERSON, P. J., 1963: *Histochemistry: Theory, Practice and Bibliography*. Hoeber Medical Division, Harper and Row, New York.
- BARNETT, R. J., and SELIGMAN, A. M., 1952: Histochemical demonstration of protein-bound sulfhydryl groups. *Science*, vol. **116**, p. 323.
- , 1954: Histochemical demonstration of sulfhydryl and disulfide groups of protein. *J. Natl. Cancer Inst.*, vol. **14**, pp. 769-803.
- BLISS, D. E., and WELSH, J. H., 1952: The Neurosecretory system of brachyuran Crustacea. *Biol. Bull.*, vol. **103**, pp. 157-69.
- BLISS, D. E., DURAND, J. P., and WELSH, J. H., 1954: Neurosecretory systems in decapod Crustacea. *Z. Zellforsch.*, vol. **39**, pp. 520-36.
- BUNT, A. H., and ASHBY, E. A., 1967: Ultrastructure of the sinus gland of the crayfish, *Procambarus clarkii*. *Gen. Comp. Endocrinol.*, vol. **9**, pp. 334-42.
- DRACH, P., 1939: Mue et cycle d'intermue chez les Crustacés Decapodes. *Ann. Inst. Oceanogr.* vol. **19**, pp. 103-91.
- ENAMI, M., 1951: The sources and activities of two chromatophoretropic hormones in crabs of the genus *Sesarma*. II. Histology of incretory elements. *Biol. Bull.*, vol. **101**, pp. 241-58.
- EWEN, A. B., 1962: An improved aldehyde fuchsin technique for neurosecretory products in insects. *Trans. Amer. Micr. Soc.*, vol. **81**, pp. 94-6.
- FOOT, N. C., 1933: The Masson trichrome staining methods for routine laboratory use. *Stain. Technol.*, vol. **8**, pp. 101-10.
- GABE, M., 1952: Particularités histochimiques de l'organe de Hanstrom (organe X) et de la glande du sinus chez quelques Crustacés Decapodes. *Compt. Rend.*, vol. **235**, pp. 90-2.
- , 1966: *Neurosecretion*. Pergamon Press, Oxford.
- HANSTRÖM, B., 1937: Die Sinusdrüse und der hormonal bedingte Farbwechsel der Crustaceen. *Kgl. Svenska. Vetenskapsakd. Hdl.* (3), vol. **16**, part 10, pp. 1-99.
- , 1947: The brain, the sense organs and the incretory organs of the head in the Crustacea Malacostrac. *Lunds. Univ. Arsskr. N.F. Adv.* 2, vol. **43**, part 9, pp. 1-45.
- HODGE, M., and CHAPMAN, G. B., 1958: Some observations on the fine structure of the sinus gland of a land crab, *Gecarcinus lateralis*. *J. Biophys. Biochem. Cytol.*, vol. **4**, pp. 571-4.
- HUBSCHMAN, J. H., 1962: A simplified Azan process well suited for crustacean tissue. *Stain. Technol.*, vol. **37**, pp. 379-80.
- INOUE, H., 1957: On the neurosecretory cells of *Pachygrapsus crassipes*. *Mem. Gakugei. Fac. Akita. Univ. Nat. Sci.* vol. **7**, pp. 84-92.
- LAKE, P. S., 1969: Changes in the histochemical nature of neurosecretory material during axonal transport in the crab, *Paragrapsus gaimardii*. *Experientia*, vol. **25**, p. 1314.
- , 1970: Histochemical studies of the neurosecretory system of *Chirocephalus diaphanus*. Prévost (Crustacea: Anostraca). *Gen. Comp. Endocrinol.* vol. **14**, pp. 1-15.
- MATSUMOTO, M., 1958: Morphological studies on the neurosecretion in crabs. *Biol. J. Okayama. Univ.*, vol. **4**, pp. 103-76.
- MEUSY, J., 1968: Précisions nouvelles sur l'ultrastructure de la glande du sinus Crustacé Decapode Brachyoure, *Carcinus maenas*. *Bull. Soc. Zool. France*, vol. **93**, pp. 291-9.
- MIYAWAKI, M., 1956a: Histological observations on the incretory element in the eyestalk of a Brachyura, *Telmessus cheiragonus*. *J. Fac. Sci. Hokkaido. Univ. Ser. VI. Zool.* vol. **12**, pp. 325-32.
- , 1956b: PAS-positive material in the neurosecretory cells of the crab, *Telmessus cheiragonus*. *Annot. Zool. Japon.* vol. **29**, pp. 151-4.
- , 1956c: Cytological and cytochemical studies on the neurosecretory cells of a Brachyura, *Telmessus cheiragonus*. *J. Fac. Sci. Hokkaido. Univ. Ser. VI. Zool.* vol. **12**, pp. 516-20.
- , 1960: On the neurosecretory cells of some decapod Crustacea. *Kumamoto. J. Sci. Ser. B. Sec. 2.* vol. **5**, pp. 1-20.
- ÖTSU, T., 1965: Component amino acids of chromatophore concentrating hormones from Decapoda, Crustacea. *Naturwissenschaften*, vol. **52**, pp. 187-8.
- ÖTSU, T., and SONOBE, H., 1965: Component amino acids of chromactivating substances in the thoracic ganglion of the crab, *Eriocheir japonicus*. *Annot. Zool. Japon.* vol. **38**, pp. 127-33.

- PANTIN, C. F. A., 1946: Notes on Microscopical technique for zoologists. Cambridge Univ. Press, London.
- PARAMESWARAN, R., 1956: Neurosecretory cells of the central nervous system of the crab, *Paratelphusa hydrodromous*. *Quart. J. Micr. Sci.* vol. 97, pp. 75-82.
- POTTER, D., 1954: Histology of the neurosecretory system of the blue crab, *Callinectes sapidus*. *Anat. Rec.* vol. 120, p. 216.
- , 1958: Observations on the neurosecretory system of portunid crabs. 2nd. Internat. Symp. Neurosekretion. (Edited by W. BARGMANN, B. HANSTROM, E. SCHARRER, and B. SCHARRER), pp. 113-18. Springer, Berlin.
- REHM, M., 1959: Observations on the localisation and chemical constitution of neurosecretory material in nerve terminals in *Carcinus maenas*. *Acta. Histochem.* vol. 7, pp. 88-106.
- SHIVERS, R. R., 1967: Fine structure of crayfish optic ganglia. *Univ. of Kansas Science Bull.* vol. 47, pp. 677-733.
- SZUDARSKY, M., 1963: Neurosecretion of the central nervous system of the crab, *Rhithropanopeus harrisi* (Gould) subspecies *tridentata* (Maitl.). *Acta. Biol. et. Med. Soc. Sci. Gedan.* vol. 7, pp. 1-32.
- VALENTE, D., 1959: Contribuição para o estudo da Neurosecreção nos crustáceos. *Boletim. Fac. Fil. Ciên. Letr. Univ. São Paulo.* No. 232, Zoologia No. 22, pp. 5-74.
- VAN DE KAMER, J. C., 1967: Changes in the hypothalmo-hypophysial system of common frogs, under osmotic stress and in a temperature experiment. In IV. Internat. Symp. Neurosecretion. (Edited by F. STUTINSKY), pp. 95-100, Springer-Verlag, Berlin.
- YASUMA, A., and ICHIKAWA, T., 1953: Ninhydrin-Schiff and alloxan-Schiff staining. A new histochemical method for protein. *J. Lab. Clin. Med.* vol. 41, pp. 296-9.

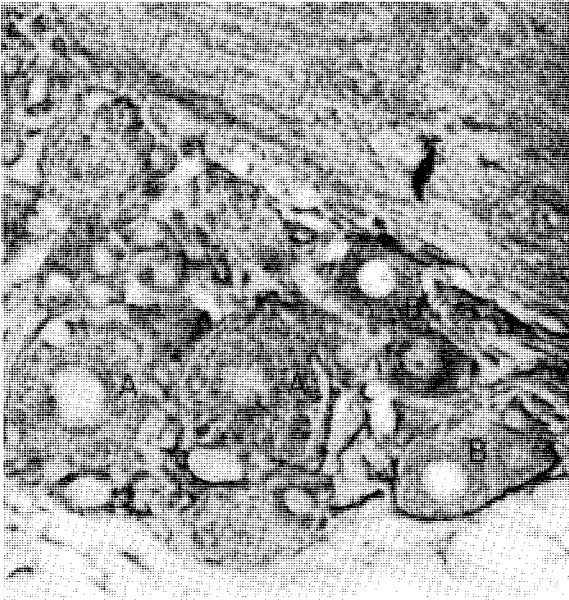


Plate 1.—Longitudinal section of Region 4 of the brain of *P. guimardii*, showing large monopolar neurosecretory cells (A) and medium monopolar neurosecretory cells (B). Stained with paraldehyde-fuchsin technique. Magnification x 800.

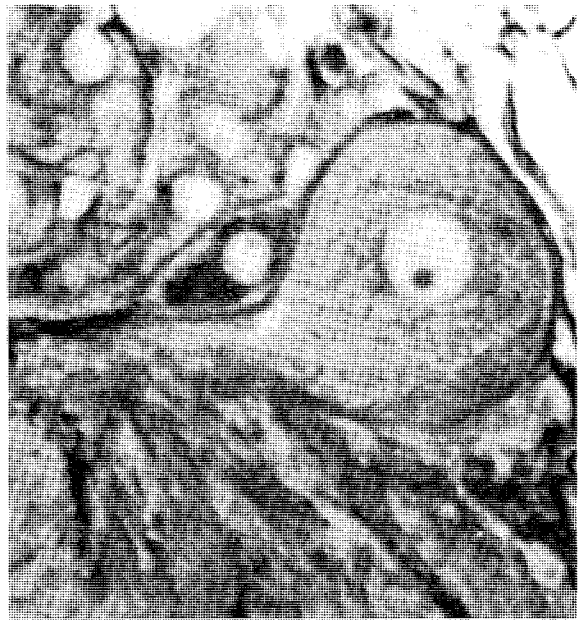

Plate 2.—View of large monopolar neurosecretory cell in Region I of the protocerebrum of *P. guimardii*. Stained with paraldehyde-fuchsin technique. Magnification x 1,700.

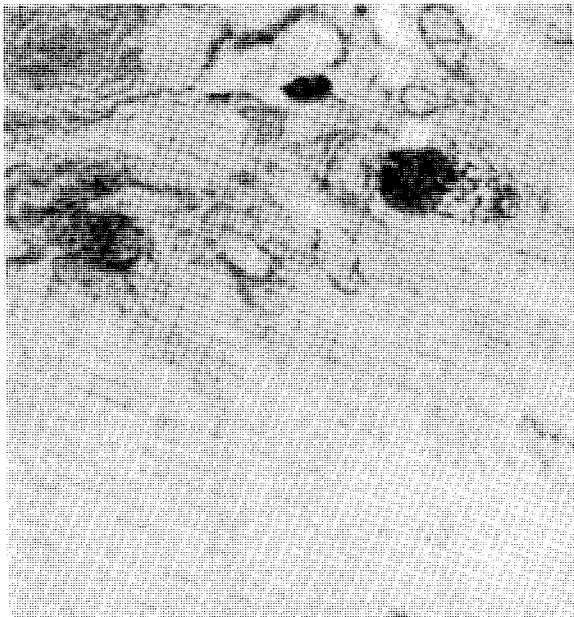

Plate 3.—Neuroglial cells displaying signs of secretory activity. They are located near Region I of the protocerebrum of *P. guimardii*. Stained with the paraldehyde-fuchsin technique. Magnification x 1,500.

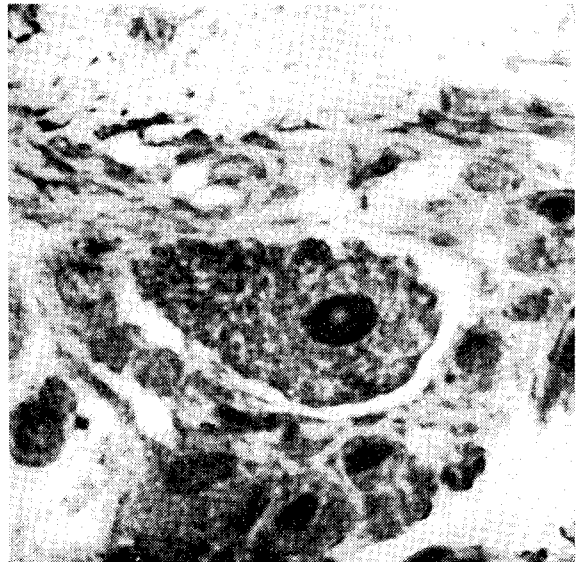


Plate 4.—Large monopolar neurosecretory in position EI of the eyestalk of *P. guimardii*. Stained with Mallory's Triple technique. Magnification x 1,600.

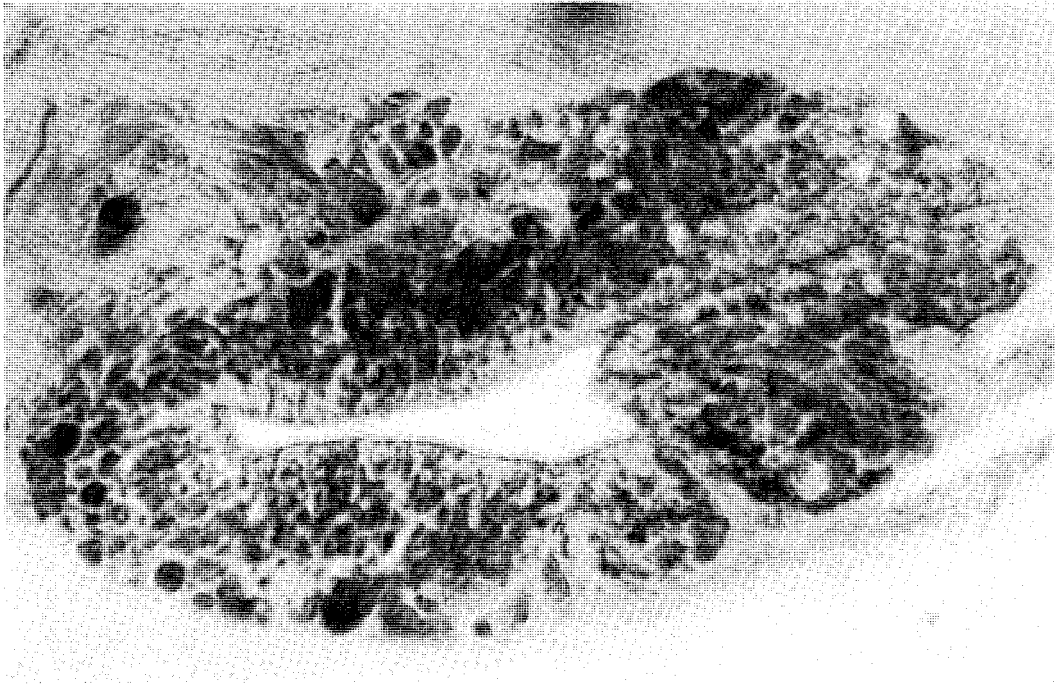


Plate 5.—Longitudinal section of the sinus gland of *P. gaimardii*. Stained with the alcian yellow/alcian blue technique. Magnification x 800.