

VETERINARSKI ARHIV 86 (2), 273-285, 2016

## A rare severe enamel defect on an upper pig molar from an early medieval stronghold in Prague (Czech Republic) - short communication

Wolf-Rüdiger Teegen<sup>1\*</sup>, and René Kyselý<sup>2</sup>

<sup>1</sup>ArchaeoBioCenter and Institute for Pre- and Protohistoric Archaeology and Archaeology of the Roman Provinces, Ludwig-Maximilians-University Munich, Munich, Germany

<sup>2</sup>Institute of Archaeology of the Czech Academy of Sciences, Prague, v.v.i., Czech Republic

---

**TEEGEN, W.-R., R. KYSELÝ: A rare severe enamel defect on an upper pig molar from an early medieval stronghold in Prague (Czech Republic) - short communication. Vet. arhiv 86, 273-285, 2016.**

### ABSTRACT

The present communication describes the case of an approx. 9 month old pig from the early medieval fortress Vyšehrad in Prague (Bohemia, Czech Republic). It showed an exceptionally severe enamel defect (plane-form hypoplasia) in the upper half of the crown of a right upper first molar. The plane-form defect was probably triggered by short-term disturbances of the enamel matrix secretion. After a period of approximately 1.5 or 2 months, normal enamel secretion may be assumed. Such strong hypoplasia is extremely rare in osteo-archaeological records. Regarding the age of the pig in question, the enamel defect could have been caused by problems during or after birth and/or during weaning.

**Key words:** enamel hypoplasia, severe dental malformation, infection, pig (*Sus domesticus*), Middle Ages, weaning

---

### Introduction

In contrast to ruminant teeth, which are often covered by cementum, in pig teeth this is not the case. Therefore, their crowns can be studied easily for the presence of teeth malformations as well as enamel defects. If the enamel is (partially) gone, which is in archaeological teeth quite often the case, dentine defects may also be observed (TEEGEN, 2013, 55 Fig. 4).

Since the turn of the millennium, pig teeth have been an object of study in veterinary anatomy and pathology, as well as in osteo-archaeology (e.g. DOBNEY and ERVYNCK, 1998; 2000; DOBNEY et al., 2002; 2004; TEEGEN and WUSSOW, 2001; TEEGEN, 2005;

---

\*Corresponding author:

Prof. Dr. Phil. Habil. Wolf-Rüdiger Teegen, ArchaeoBioCenter and Institute for Pre- and Protohistoric Archaeology and Archaeology of the Roman Provinces, Ludwig-Maximilians-University Munich, Geschwister-Scholl-Platz 1, D-80539 Munich, Germany, Phone: +49 89 2180 5528; Fax: +49 89 2180 5662; E-mail: w.teegen@lmu.de

ISSN 0372-5480  
Printed in Croatia

2006; 2013; KIERDORF et al., 2009; MAGNELL and CARTER, 2007; PIGIÈRE, 2009; FRÉMONDEAU, 2012). In the classical work on teeth formation written by COLYER (1936), and the updated edition of this book (MILES and GRIGSON, 1990), a whole chapter is dedicated to this topic. Of particular importance, e.g. for veterinary pathology, forensics or osteo-archaeology, is the fact that the time of the onset of these defects can be determined approximately. So we can look at the life history of the individual.

The development of crowns and roots is generally well known for recent, domestic pigs (HABERMEHL, 1975 with an extensive bibliography). Modern pig breeding in the 20<sup>th</sup> century led, however, to races which mature early. Feeding experiments with undernourished pigs (McCANCE et al., 1961) were used as a model for medieval and prehistoric pigs. Recently, MAGNELL and CARTER (2007) proposed the tooth development of wild boars with known age as a model for the “primitive” domestic pigs from archaeological contexts.

Enamel defects in archaeological pig remains have only been studied in some European regions, such as the British Isles and Coastal Flanders (DOBNEY and ERVYNCK, 1998; 2000; DOBNEY et al., 2002; 2004), Gaul (TEEGEN, 2004b; PIGIÈRE, 2009; FRÉMONDEAU, 2012) and Coastal Germany and selected sites (TEEGEN, 2005; 2006; 2013). Similar studies are still missing from other European regions, including Bohemia and the Mediterranean area. Severe enamel defects in the canines of male domestic pigs from prehistoric and medieval Bohemia, which were of traumatic origin, were recently published (TEEGEN and KYSELÝ, 2014).

In this contribution, we present a case from Vyšehrad (district Prague, Bohemia, Czech Republic). As described below, it shows particularly severe enamel hypoplasia, which is found extremely rarely in the osteo-archaeological records.

**Acronyms:** EDJ = Enamel-Dentine-Junction, GL = greatest length, GB = greatest breadth, M1/M<sup>1</sup> = first molar/upper first molar. P4/P<sup>4</sup> = fourth premolar/upper fourth premolar, pd<sup>4</sup> = upper fourth deciduous molar.

### **Materials and methods**

Vyšehrad is an early medieval stronghold located in central Prague, on the promontory above the Vltava river. It was an important centre of Bohemian (Premyslid) nobility in the 10<sup>th</sup> and 11<sup>th</sup> century A.D. In 2003 excavations were carried out at the southern part of the former acropolis of Vyšehrad by L. Varadzin and I. Štefan, on behalf of the Institute of Archaeology of the Czech Academy of Sciences (archaeological description in MOUCHA et al., 2015). The evaluation of the osteological assemblage acquired during this excavation is part of a recently published archaeozoological synthesis on Vyšehrad (Kyselý, 2015). The specimen described in our paper was found within this excavation,

in trench II, layer 14/V (inv. no. 21). This context was dated to the timespan between the 2<sup>nd</sup> half of the 10<sup>th</sup> century and the 2<sup>nd</sup> third of the 11<sup>th</sup> century A.D.

The nomenclature of the domestic animals follows GENTRY et al. (2004). The age of the pig maxilla (Fig. 1; 6) was determined according to the development of the teeth (HABERMEHL, 1975; REICHSTEIN, 1991). Furthermore, the tooth development in the mandibles of undernourished pigs, according to McCANCE et al. (1961), and of wild boar with known age (MAGNELL and CARTER, 2007) was used. The onset of hypoplastic defects was determined using both the data by McCANCE et al. (1961) and MAGNELL and CARTER (2007). The maxilla fragment was studied macroscopically and using magnifying lenses. Furthermore, it was X-rayed at the National Museum in Prague.

### Description of the find

The object of the study is a fragment of the right upper jaw of a pig. On the basis of its small dimensions (compared with the reference collection in the archaeozoological department of the Institute of Archaeology of the Czech Academy of Sciences) it was ascribed to the domestic form (*Sus domesticus*). The upper deciduous molar (pd<sup>4</sup>) and the first permanent molar (M<sup>1</sup>) are the only teeth preserved in the fragment (Fig. 1-4). The distal part of the cavity of the permanent premolar (P<sup>3</sup>) is visible (Fig. 3). The cavity of the permanent P<sup>4</sup> is not visible, it is hidden under the pd<sup>4</sup> (cf. MAGNELL and CARTER, 2007, 46 Fig. 3) and can be seen only on the radiograph (Fig. 5). The roots of the M<sup>1</sup> are fully grown (Fig. 4-5). These observations suggest that the age at death of the present individual was around 9 months (cf. HABERMEHL, 1975; 1985; SILVER, 1969; REICHSTEIN, 1991; MAGNELL and CARTER, 2007, 47, Fig. 4). Its sex could not be determined.

The fragment of the upper jaw shows slight paradontitis at the alveolar margins (Fig. 3, arrow). Between the right pd<sup>4</sup> and M<sup>1</sup> a pocket is visible (Fig. 3, star). These alterations can often be observed in osteo-archaeological records.

Measurements of the pd<sup>4</sup>: GL = 13.1 mm, GB (anterior half) = 11.1 mm, GB (posterior half) = 10.8 mm, max. height of the crown (above EDJ) = 5.1 mm. The pd<sup>4</sup> shows no hypoplastic defects.

Measurements of the M<sup>1</sup>: GL = 15.5 mm, GB (anterior half) = 12.9 mm, GB (posterior half) = 12.5 mm, max. height of the crown (above EDJ) = ca. 7.7 mm, distance of the enamel defect from EDJ = 2.5 mm/3.5 mm to 7.7 mm.

Hypoplasia: The enamel defect of the M<sup>1</sup> is clearly visible on Figs. 1-4. All cusps are pronounced and sharp. At the base of the cusps, a clear step to the basilar part is present (Fig. 2; 4). This means that the enamel thickness is clearly reduced in the upper half of the crown. In some parts of the cusp tips no enamel at all is present (Fig. 2). It is not clear whether this fact was caused by a complete lack of enamel formation or the abrasion of

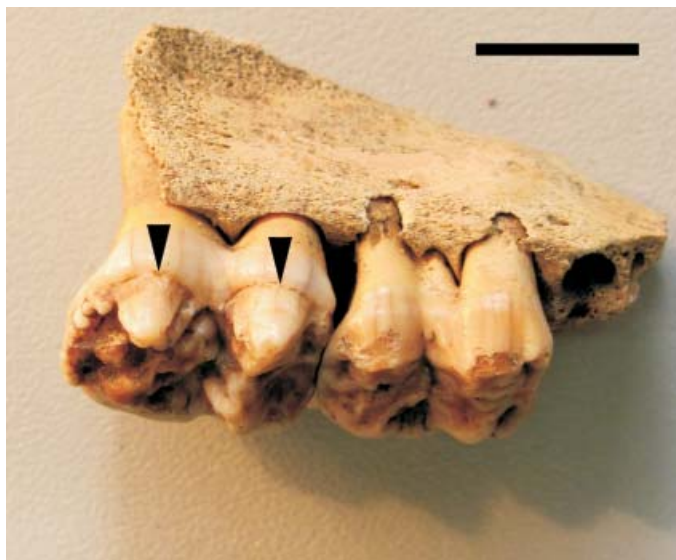

Fig. 1. Vyšehrad, 10<sup>th</sup>/11<sup>th</sup> cent. A.D. (Inv.-No. 21). Domestic pig, right maxilla fragment with severe plane-form enamel defects of the cusps of the right upper M<sup>1</sup> (arrows). View from the lateral aspect. Scale: 1 cm. Photo: R. Kyselý.

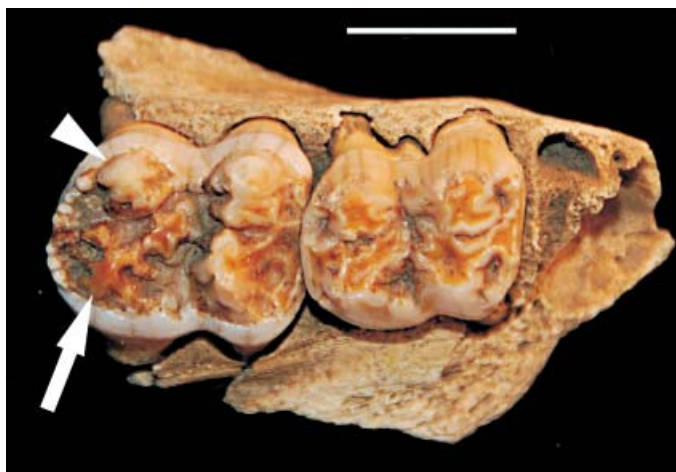

Fig. 2. The same case as in Fig. 1. View from the occlusal aspect. Arrow head: plane-form enamel defects of the cusps of the M<sup>1</sup>. Arrow: missing enamel of the disto-palatinal cusp. Scale: 1 cm. Photo: R. Kyselý.

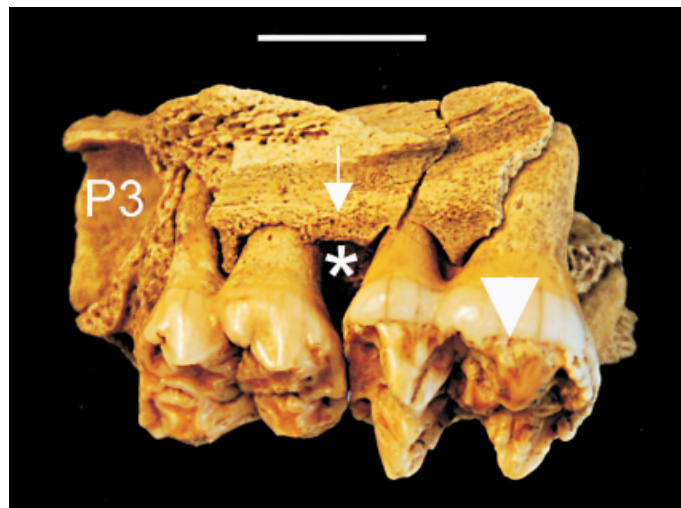


Fig. 3. The same case as in Fig. 1. View from the palatal aspect. Arrow head: plane-form enamel defects of the cusps of the M<sup>1</sup>. Arrow: paradontitis. Star: pocket between the pd<sup>4</sup> and M<sup>1</sup>. Scale: 1 cm. Photo: R. Kyselý.

a thin enamel layer due to wear. However, the latter seems to be more likely. In contrast, the enamel of the molar basis seems to be normally developed (Fig. 1-4). Therefore the disturbance of the enamel formation only occurred in the first half of the M<sup>1</sup> development.

The crown formation of the lower M<sub>1</sub> in undernourished pigs begins in utero (McCANCE et al., 1961), and in wild boars around birth (MAGNELL and CARTER, 2007, 46, Table 3) (cf. Fig. 6). In both, the crown is completed at 2-3 months (ibid.). For the upper dentition, similar formation rates can be assumed. The enamel of the M<sup>1</sup> at the level of the described defect had to have been formed between the beginning of the M<sup>1</sup> crown formation and the half-time of the formation. This means a time span from prior to birth or around birth up to 1.5 months (Fig. 6), depending on the age-scales used (McCANCE et al., 1961 or MAGNELL and CARTER, 2007).

As BERTEN (1895, 10; 11; 13) first described, there are three main types of enamel hypoplasia: “grübchenförmige Defekte” (pit-form defects), “furchenförmige Defekte” (furrow-form defects), and “flächenförmige Defekte” (plane-form defects). He also carried out first microscopic investigations on dental thin sections (cf. BERTEN, 1895, pl. 3).

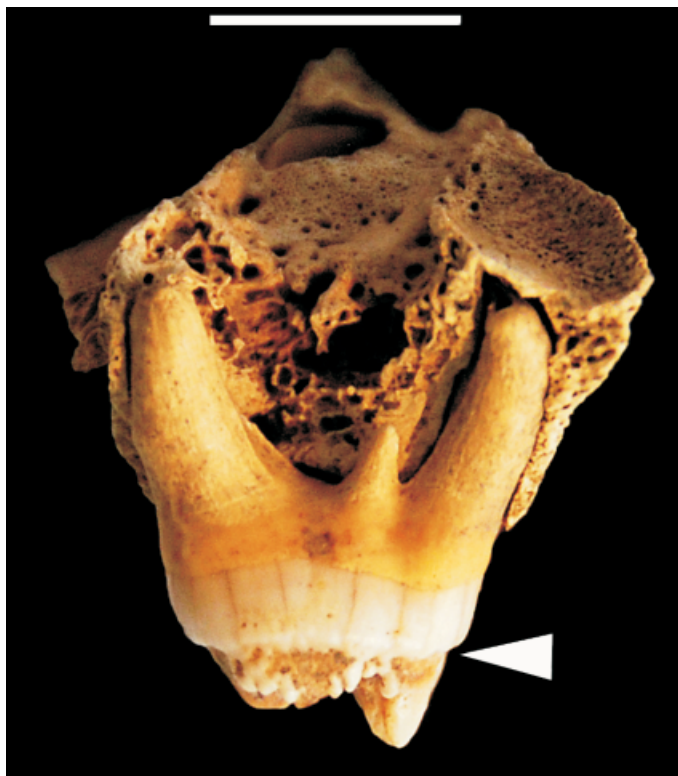

Fig. 4. The same case as in Fig. 1. View on M<sup>1</sup> from the distal aspect. Arrow head: end of the plane-form enamel defect. Scale: 1 cm. Photo: R. Kyselý.

The enamel defect described here (Fig. 1-5), may be classified as a typical plane-form defect (cf. HILLSON 2014, 167-170). The cervical ledge indicates the resumption of normal activity of the secretory ameloblasts.

HILLSON and BOND (1997) and WITZEL et al. (2006; 2008) analysed histologically thin sections of human and pig teeth, and found that plane-form defects may be triggered by short-term disturbances of the enamel matrix secretion.

The enamel formation here was, however, disturbed for a period of approximately 1.5 or 2 months (Fig. 3-5). Later, normal enamel secretion can be assumed (Fig. 4-5).

The fragmentary character of the evidence in the present case does not allow further conclusions regarding the other teeth, e.g. on the left upper side or the mandibles. Due to

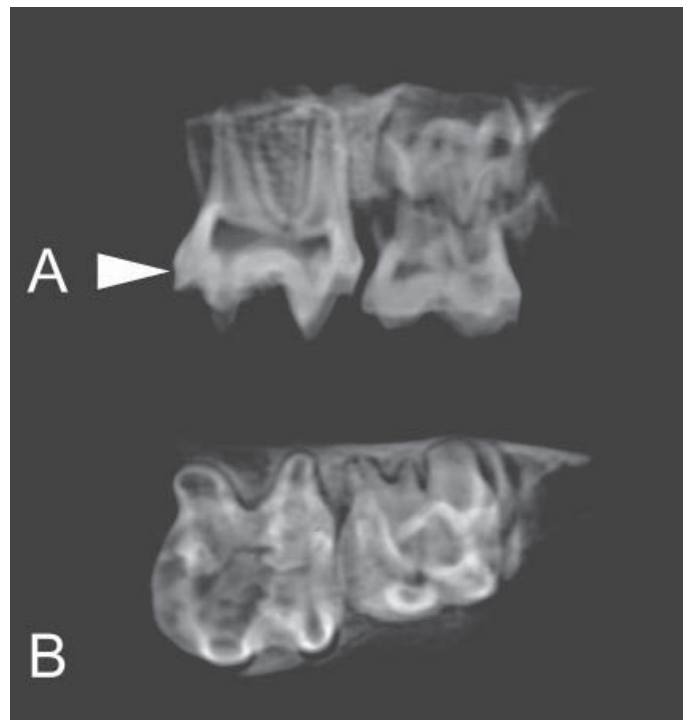


Fig. 5. The same case as in Fig. 1. Radiograph in palatal-buccal (A) and occlusal-apical (B) projections. Arrow head: end of the plane-form enamel defect (cf. Fig. 4). X-ray: National Museum in Prague.

the parallel development of the crown of the M<sup>1</sup> and the roots of pd<sup>4</sup> (cf. MAGNELL and CARTER, 2007, 46, Fig. 3), the roots of the latter were checked for the presence of root hypoplasia (cf. TEEGEN, 2004a). In the small parts visible due to fenestration (Fig. 1), no hypoplastic defects of the roots could be detected. Also the radiograph in two planes (Fig. 5) gave no clear evidence of dentine defects of the roots.

### Discussion

Such severe enamel hypoplasia, as observed in the case of the M<sup>1</sup> from Vyšehrad, are very rare in the osteo-archaeological records. During the analysis of enamel hypoplasia in northern Germany between the Iron Age and the Renaissance (approx. 500 B.C. to A.D. 1500), where totally 2410 pig mandibles and several hundred upper jaws were studied, no comparative case was detected at all (TEEGEN, 2006; 2013).







The only comparative case, studied by one of us (WRT), belongs to a recent wild boar shot in the former German Democratic Republic (TEEGEN and WUSSOW, 2001). In that case, severe enamel defects are present on the cusps of the M<sup>3</sup>. According to MAGNELL and CARTER (2007, 47, Fig. 4), this defect developed between 6<sup>th</sup> and 12<sup>th</sup> months of age. In that case, an origin in winter seems very likely.

MILES and GRIGSON (1990, 442-443, Fig. 20.8) published a similar severe enamel defect in the lower and upper M<sup>3</sup> of a recent baboon (*Papio spec.*). They studied thin sections of the upper M<sup>3</sup> and found poorly mineralized dentine, which corresponded to enamel defects. Also in this case, a longer period - probably some months - of growth disruption was present.

In a more recent paper, KIERDORF et al. (2009, 1639, Fig. 1, a-b) studied an archaeological find of a first upper pig molar from Fais Island, Micronesia. It is not entirely comparable with the present molar from Vyšehrad due to the fact that the Micronesian M<sup>1</sup> also shows enamel defects at the crown base. Their interpretation was severe nutritional stress after weaning.

### Conclusions

Due to the fact that only the cusps of the M<sup>1</sup> show reduced or no enamel, it is possible to deduce that the disturbed and incomplete amelogenesis was only a temporary condition for approx. 1-2 months (Fig. 6), which corresponds to the lactation period.

As WITZEL et al. (2006, 2008) have shown, a short-term disturbance could be responsible for the extended enamel defect, where the ameloblasts needed some time to recover.

The intrauterine development of the crown of the pd<sup>4</sup> was uneventful (Fig. 1-3). Also the overall root dentine formation was normal, as may be seen on the radiograph (Fig. 5). Slight defects are, however, not visible on the radiographs. The normal root formation could be an indication that only the ameloblasts showed reduced secretion and the dentine development was quite normal.

In wild boars and extensively used domestic pigs, the piglets are weaned between one and two months post-partum. Experiments in modern pigs indicate weaning after five weeks (BILKEI, 1996b, 38).

In the present case from Vyšehrad, the ameloblasts started to work normally sometime after weaning. The same is true for the dentine formation, since the roots are formed normally (Fig. 4).

What could have been the cause of these severe enamel defects? From modern veterinary medicine it is known that piglets are susceptible to several diseases following

birth and/or the weaning process (cf. BILKEI, 1996a, b; PLONAIT, 2001). Today, approx. 15 % of all piglets die during birth or during the first three days of life (PLONAIT, 2001, 503), when mainly non-infectious causes are responsible for their death. Later, in the first six weeks of life infectious diseases are the main cause of death (PLONAIT, 2001, 504 Fig. 16-19) - mainly diseases of the gastrointestinal tract, the lungs, the meninges, the joints or general infections. Also parasitic infections, which generally begin just after birth, should be considered. Such parasitic infections can induce enamel defects, as experiments have shown (SUCKLING et al., 1986). Finally, problems in lactation by the sow can lead to malnutrition of their piglets, and subsequently to developmental defects.

#### Acknowledgements

This study was supported in part from RVO: 67985912 (RK). The authors declare no conflict of interest. The helpful suggestions by the anonymous reviewer(s) and the careful editing by the editor are gratefully acknowledged.

#### References

- BERTEN, J. (1895): Hypoplasie des Schmelzes (congenitale Schmelzdefecte; Erosionen). Patholog.-anatom.-klinische Studie. Habilitation thesis, University of Würzburg. A. Th. Engelhardt, Leipzig. Also published in: Deutsche Monatsschrift für Zahnheilkunde 13, 1895, 425-439, 483-498, 533-548, 587-600.
- BILKEI, G. (1996a): Sauen-Management. Gustav Fischer, Jena, Stuttgart.
- BILKEI, G. (1996b): Ferkelverluste nach dem Absetzen. Gustav Fischer, Jena, Stuttgart.
- COLYER, F. (1936): Variations and Diseases of the Teeth of Animals. John Bale, Sons and Danielsson, London.
- DOBNEY, K., A. ERVYNCK (1998): A protocol for recording linear enamel hypoplasia on archaeological pig teeth. *Int. J. Osteoarchaeol.* 8, 263-273.
- DOBNEY, K., A. ERVYNCK (2000): Interpreting developmental stress in archaeological pigs: the chronology of linear enamel hypoplasia. *J. Archaeol. Sci.* 27, 597-607.
- DOBNEY, K., A. ERVYNCK, B. LA FERLA (2002): Assessment and further development of the recording and interpretation of linear enamel hypoplasia in archaeological pig populations. *Environ. Archaeol.* 7, 35-46.
- DOBNEY, K., A. ERVYNCK, U. ALBARELLA, P. ROWLEY-CONWY (2004): The chronology and frequency of a stress marker (linear enamel hypoplasia) in recent and archaeological populations of *Sus scrofa* in north-west Europe, and the effects of early domestication. *J. Zool.* 264, 197-208.
- FRÉMONDEAU, D. (2012): Rythmes saisonniers des élevages porcins archéologiques : propositions pour un protocole d'analyse isotopique. PhD thesis, Muséum National d'Histoire Naturelle, École Doctorale «Sciences de la Nature et de l'Homme» (ED 227), Paris.

W.-R. Teegen and R. Kyselý: A rare severe enamel defect from an early medieval stronghold

- GENTRY, A., J. CLUTTON-BROCK, C. P. GROVES (2004): The naming of wild animal species and their domestic derivatives. *J. Archaeol. Sci.* 31, 645-651.
- HABERMEHL, K.-H. (1975): Altersbestimmung bei Haus- und Labortieren. 2<sup>nd</sup> ed., Parey, Hamburg, Berlin.
- HABERMEHL, K.-H. (1985): Altersbestimmung bei Wild- und Pelztieren. Möglichkeiten und Methoden. Parey, Hamburg, Berlin.
- HILLSON, S. (2014): Tooth development in human evolution and bioarchaeology. Cambridge University Press, Cambridge, New York.
- HILLSON, S., S. BOND (1997): Relationship of enamel hypoplasia to the pattern of tooth crown growth: A discussion. *Am. J. Phys. Anthropol.* 104, 89-103.
- KIERDORF, H., U. KIERDORF, C. WITZEL, M. INTOH, K. DOBNEY (2009): Developmental defects and postmortem changes in archaeological pig teeth from Fais Island, Micronesia. *J. Archaeol. Sci.* 36, 1637-1646.
- KYSELÝ, R. (2015): Archeozoologická analýza raně středověkých kostí (An archaeozoological analysis of early medieval bones). In: Vyšehrad - knížecí a královská akropole. (Moucha, V., B. Nechvátal, L. Varadzin, Eds.). Svědectví archeologie. Institute of Archaeology of the Czech Academy of Sciences, Prague, Praha.
- MAGNELL, O., R. CARTER (2007): The chronology of tooth development in wild boar - A guide to age determination of linear enamel hypoplasia in prehistoric and medieval pigs. *Vet. zootech.* 40, 51-81.
- McCANCE, R. A., E. H. R. FORD, W. A. B. BROWN (1961): Severe undernutrition in growing and adult animals. 7. Development of the skull, jaws and teeth in pigs. *Brit. J. Nutr.* 15, 213-224.
- MILES, A. E. W., C. GRIGSON (1990): Colyer's variations and diseases of the teeth of animals, revised edition. Cambridge University Press, Cambridge.
- MOUCHA, V., B. NECHVÁTAL, L. VARADZIN (2015): Vyšehrad - knížecí a královská akropole. Svědectví archeologie. Institute of Archaeology of the Czech Academy of Sciences, Prague, Praha.
- PIGIÈRE, F. (2009): Évolution de l'économie alimentaire et des pratiques d'élevage de l'antiquité au haut moyen âge en Gaule du nord. Une étude régionale sur la zone limoneuse de la moyenne Belgique et du sud des Pays-Bas. *Brit. Archaeol. Rep. Int. Ser.* 2035, Tempus Reparatum, Oxford.
- PLONAIT, H. (2001): Geburt, Puerperium und perinatale Verluste. In: Lehrbuch der Schweinekrankheiten, 3<sup>rd</sup> ed. (Waldmann, K.-H., M. Wendt, Eds.), Parey, Berlin, pp. 471-512.
- REICHSTEIN, H. (1991): Die Fauna des germanischen Dorfes Feddersen Wierde, Teil 1-2. Feddersen Wierde. Die Ergebnisse der Ausgrabung der vorgeschichtlichen Wurt Feddersen Wierde bei Bremerhaven in den Jahren 1955 bis 1963, Vol. 4. Steiner, Stuttgart.
- SCHROEDER, H. E. (1997): Pathobiologie oraler Strukturen, 3<sup>rd</sup> ed. Karger, Basel.
- SILVER, I. A. (1969): The ageing of domestic animals. In: Science in Archaeology - Survey of Progress and Research. (Brothwell, D., E. Higgs, Eds.), Thames and Hudson, London, pp. 283-302.

W.-R. Teegen and R. Kyselý: A rare severe enamel defect from an early medieval stronghold

- SUCKLING, G. W., D. C. ELLIOT, D. C. THURLEY (1986): The macroscopic appearance and associated histological changes in the enamel organ of hypoplastic lesions of sheep incisor teeth resulting from induced parasitism. *Arch. Oral Biol.* 31, 427-439.
- TEEGEN, W.-R. (2004a): Hypoplasia of the tooth root: A new unspecific stress marker in human and animal paleopathology. *Am. J. Phys. Anthropol., Suppl.* 38, p. 193.
- TEEGEN, W.-R. (2004b): Paläopathologische Untersuchungen an Tierknochen aus Bibracte - Mont Beuvray. *Leipziger online-Beitr. Ur- u. Frühgesch. Archäol.* 15, 13-14. [https://www.gko.uni-leipzig.de/fileadmin/user\\_upload/historisches\\_seminar/02urundfruehgeschichte/Online\\_Beitraege/OnlBei15.pdf](https://www.gko.uni-leipzig.de/fileadmin/user_upload/historisches_seminar/02urundfruehgeschichte/Online_Beitraege/OnlBei15.pdf) (30.06.2015).
- TEEGEN, W.-R. (2005): Linear transverse enamel hypoplasias in medieval pigs from Germany: Starigard/Oldenburg (10<sup>th</sup> cent. AD). In: *Health and Diet in Past Animal Populations: Current research and future directions. Proceedings of the 9<sup>th</sup> ICAZConference, Durham 2002.* (Davies, J., M. Fabis, I. Mainland, M. Richards, R. Thomas, Eds.), Oxbow, Oxford, pp. 89-92.
- TEEGEN, W.-R. (2006): *Zur Archäologie der Tierkrankheiten von der frühen Eisenzeit bis zur Renaissance im deutschen Küstengebiet.* Unpubl. Habilitation thesis, University of Leipzig, Leipzig, Germany.
- TEEGEN, W.-R. (2013): So eine Schweinerei ... Vergleichende Untersuchungen zum Stress bei eisenzeitlichen bis mittelalterlichen Schweinen aus dem norddeutschen Küstengebiet. *Siedlungs- u. Küstenforsch. südl. Nordseegebiet* 36, 53-62.
- TEEGEN, W.-R., R. KYSELÝ (2014): Short contribution: Severe enamel defects and malformations of upper canines in pre-historic and historic male domestic boars from Bohemia. *Interdiscipl. Archaeol.* 5, 2014, 139-146. [http://iansa.eu/papers/iansa-2014-02-kyselý\\_onlinefirst.pdf](http://iansa.eu/papers/iansa-2014-02-kyselý_onlinefirst.pdf) (30.06.2015).
- TEEGEN, W.-R., J. WUSSOW (2001): Paläopathologische Untersuchungen an Beständen des Museums für Haustierkunde "Julius Kühn" der Martin Luther-Universität Halle-Wittenberg - Ein Beitrag zur Paläopathologie der Haustiere. In: *Homo - unsere Zukunft.* (Schultz, M., et al., Eds.), Cuvillier, Göttingen, pp. 356-359.
- WITZEL, C., U. KIERDORF, K. DOBNEY, A. ERVYNCK, S. VANPOUCKE, H. KIERDORF (2006): Reconstructing impairment of secretory ameloblast function in porcine teeth by analysis of morphological alterations in dental enamel. *J. Anat.* 209, 93-110.
- WITZEL, C., U. KIERDORF, M. SCHULTZ, H. KIERDORF (2008): Insights from the inside: histological analysis of abnormal enamel microstructure associated with hypoplastic enamel defects in human teeth. *Am. J. Phys. Anthropol.* 136, 400-414.

Received: 5 January 2015

Accepted: 10 December 2015

---

**TEEGEN, W.-R., R. KYSELÝ: Rijetko teško oštećenje cakline na gornjem kutnjaku svinje pronađenom u ranoj srednjovjekovnoj tvrđavi u Pragu (Republika Češka) - kratko priopćenje. Vet. arhiv 86, 273-285, 2016.**

**SAŽETAK**

Opisan je nalaz ostataka svinje, u približnoj dobi od 9 mjeseci, pronađene u ranoj srednjovjekovnoj tvrđavi Vyšehrad u Pragu (Češka). Opaženo je iznimno jako oštećenje cakline (glatka hipoplazija) na gornjoj polovici krune, gornjeg, prvog desnog kutnjaka. Glatka hipoplazija vjerojatno je potaknuta kratkoročnim poremećajem matrice u lučenju cakline. Normalna sekrecija cakline može se pretpostaviti nakon razdoblja od približno 1,5 ili 2 mjeseca. Takva jaka hipoplazija izuzetno je rijetka u arheološkim nalazima kosti. S obzirom na dob predmetne svinje, oštećenje cakline moglo bi biti uzrokovano problemima tijekom ili nakon rođenja i/ili tijekom odbića.

**Ključne riječi:** hipoplazija cakline, teška deformacija zuba, infekcija, svinja (*Sus domesticus*), srednji vijek, odbiće

---

