

Case Report

SEJODR

Skeletal, dental and profilometric effects of Sabbagh Universal Spring 2 (SUS²) in a patient at the end of growth: a case report

Marchionni, Pierdavide *; Di Bari, Roberto *; Sferra, Simone *; Grippaudo, Cristina *

* School of Dentistry, Faculty of Medicine "A. Gemelli", Università Cattolica del Sacro Cuore - Rome, Italy

ABSTRACT

Introduction: Malocclusions, which present a severe skeletal component, are difficult to solve through orthodontic treatment in patients at the end of growth and often require a combined orthodontic-surgical treatment. The mandibular propulsion appliances "no compliance" now offer new possibilities for functional orthopedic treatment in borderline cases.

Case presentation: A patient at the end of growth with a severe malocclusion (Class II Division 1), open bite with arches' transversal discrepancy, refused the hypothesis of an orthodontic-surgical treatment, which represents the gold standard in such occlusal and skeletal problems, especially in subjects at the end of growth; consequently, a complex orthopedic-orthodontic treatment was chosen as the second choice. The patient has been successfully treated also through the use of SUS² (Sabbagh Universal Spring 2; Dentaurem, Ispringen, Germany), a "no compliance" fixed functional appliance, which carried out a significant sagittal correction.

Conclusion: The case report especially highlights the important sagittal correction obtained through the use of SUS². The SUS² had a functional outcome, which resulted in the maxillary growth stop and an effective sagittal mandibular growth increase. The SUS² effects, enhanced by elastics biomechanics, led to the bite closure and at the achievement of Class I occlusion.

Marchionni P, Di Bari R, Sferra S, Grippaudo C. Skeletal, dental and profilometric effects of Sabbagh Universal Spring 2 (SUS2) in a patient at the end of growth: a case report. *South Eur J Orthod Dentofac Res.* 2016;3(1):18-23.

Submitted: October 10, 2015; Revised: January 10, 2016; Published: April 10, 2016

INTRODUCTION

Malocclusions, which present a severe skeletal component, are difficult to solve through orthodontic treatment in patients at the end of growth and often require a combined orthodontic-surgical treatment. The mandibular propulsion appliances "no compliance" now offer new possibilities for functional orthopedic treatment in borderline cases. A patient at the end of growth with a severe malocclusion (Class II Division 1), open bite with arches transversal discrepancy, has been successfully treated through the use of SUS² (Sabbagh Universal Spring 2; Dentaurem, Ispringen, Germany). Similar cases have been treated in the literature by various authors, but the characteristic of this case is that it was a patient at the end of growth.

Corresponding Author:

Di Bari, Roberto

Via Simone Martini, 125-Pal. A5-Int. 40, 00142 - Rome, Italy

e-mail: roberto.dibari@live.it

CASE REPORT

An Italian girl, 12 years and 8 months old, high 1.75 m., came for an initial consultation.

The patient had had menarche when she was 11 years and 5 months old. Anamnesis was positive for thumb sucking until she was 10 years old.

The extra-oral clinical examination showed facial symmetry (except for the nasal septum deviation) with a normal relationship between the upper, middle and inferior face parts. At rest, the patient showed a tendency to labial incompetence with a lip-chin sulcus accentuation and the interposition of the lower lip below the upper incisors. The patient tended to stretch the chin muscle to get a complete lip closure. The profile revealed an important convexity, a reduced distance chin - neck and a closure of nose to lip angle.

The intra-oral clinical examination revealed the presence of a complete permanent dentition (except for the wisdom teeth), caries absence, good level of oral hygiene, healthy and normochromic gums.

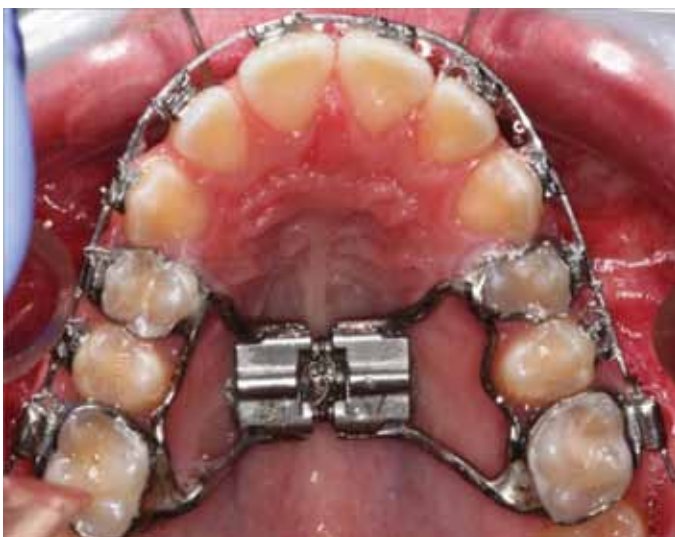confirmed by the cervical vertebrae evaluation: the patient was at CS4 stadium. The patient had had menarche when she was 11 years and 5 months old. Considering the occlusal and skeletal problems, the hypothesis of an orthodontic-surgical treatment, which represented the gold standard in such occlusal and skeletal problems, especially in subjects at the end of growth, was proposed to the patient and his parents. The patient's parents refused the orthodontic-surgical treatment, so the orthopedic-orthodontic treatment was chosen as the second choice.²

It was decided to perform the transversal correction of the upper jaw, using rapid palatal expander (RPE) banded on the first premolars and first permanent molars to achieve the maximum skeletal correction, relying on a not yet complete ossification of the sagittal median suture. Arches alignment and leveling, necessary to the Class II biomechanics preparation, have been achieved through a fixed straight wire appliance with MBT prescription. The Class II sagittal correction has been performed with the Sabbagh Universal Spring 2 (SUS²), a "no compliance" fixed functional appliance. During the treatment, elastics with an anterior box configuration and short intermaxillary elastics were used to facilitate the bite closure.

Treatment progression

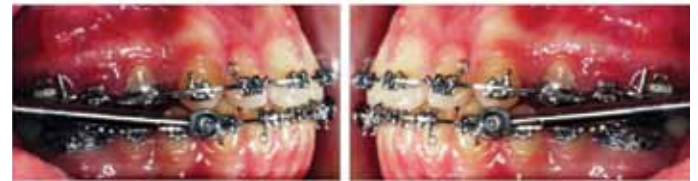The RPE was manufactured and then bonded on the 4th and the 6th (Figure 4). A 3 mm correction was achieved. The device was activated twice immediately after the bonding and then once per day for seven days. Since 0.25 mm expansion was gained per activation, after this first phase an overall correction of 2.25 mm was achieved. Afterward, the RPE was progressively activated in coordination to the sagittal correction achieved with the Sabbagh.

Figure 4. RPE (Rapid Palatal Expander) installed



Then the patient was fitted with upper and lower orthodontic fixed appliances and progressed rapidly (0.014 Ni-Ti, 0.016 stainless steel, 0.019x0.025 stainless steel) to fit the SUS² and use the potential residual growth. The SUS² has been maintained for seven months to achieve a sagittal hypercorrection. (Figure 5)

Figure 5. SUS² (Sabbagh Universal Spring 2).



At the same time of SUS² action, three elastics have been applied in anterior position (Figure 6):

- 1 orthodontic "box" elastic, applied on "Kobayashi" ligatures on 12-22-32-42
- 2 orthodontic Class III elastics between pins-braces 13-43 and 23-33.

As soon as the SUS² has been removed, TLL radiography was requested to control and to evaluate the skeletal and dental effects of the SUS² by cephalometric analysis. (Figure 7)

Figure 6. Arrangement of intermaxillary elastics.

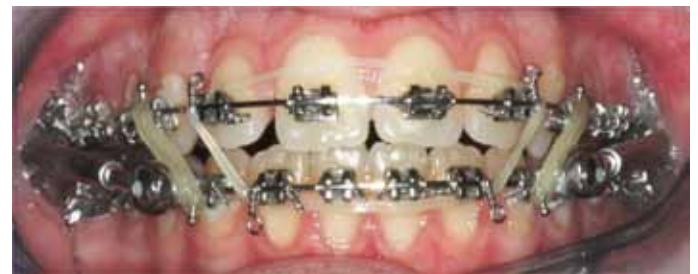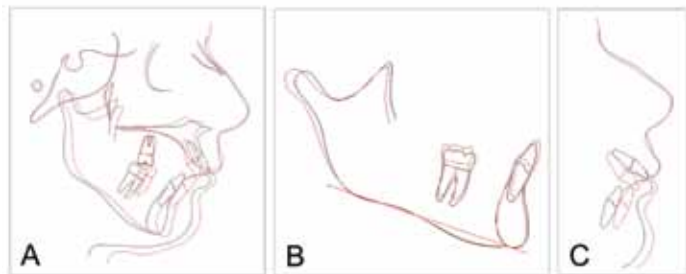


Figure 7. TLL X-ray and cephalometric values in progress.



Finally, aesthetic bends have been performed on the archwire to achieve the optimal occlusion before the debonding. A functional removable acrylic retainer has been realized with an anterior bite position to prevent relapses and to maintain the condylar position achieved. The retainers were put on the same day of the debonding. (Figure 8) An overview of the devices used and the times of action is summed in Figure 9.

Figure 13. Superimposition of pre-treatment and post-treatment tracings (A - Superimposition on the SN plane. B - Superimposition on the mandibular plane. C - Profilometric changes).



DISCUSSION

The severely increased overjet (14 mm) was due to a small lower jaw and caused by a prolonged thumb sucking habit.^{3,4} This was also showed by the spaced upper dental arch and the proclination of the upper incisors. Also, the open bite and the anterior rotation of the occlusal plane⁵ were a result of the finger sucking habit.

Since the growth peak was already gone, the reduced plasticity of jaw bone structures was requesting a quick orthopedic-orthodontic treatment.⁶

An RPE was used to obtain a possible skeletal expansion on the upper jaw.⁷ In fact, contracted upper arch prevents a mandibular forward advancement. Therefore, an initial correction of 2.25 mm was performed to let the lower jaw grow in a more forward position. The progressive mandibular advancement achieved by the SUS² required a further gradual expansion of the upper maxilla to transversally coordinate the dental arches while the sagittal correction is performed.

The SUS² (Dentaurum, Ispringen, Germany) is used as a mandibular propulsor⁸ and it can be considered a fixed functional appliance like the Herbst and the Forsus (Forsus Fatigue Resistant Device 3M Unitek, Monrovia, CA); it was designed as a combination of Herbst and Jasper Jumpers with the aim to combine the advantages of these devices and to reduce their limits. The SUS² is a telescopic device similar to Herbst but with a different type of activation. It consists of a telescoping rod located in a guide tube. Inside the tube has a spring that can be activated according to the level of forces desired. The device application is performed by engaging the Omega loop in the accessory tube of the 1st upper molar and inferiorly it is inserted on the arch between the first premolar and canine through an SUS arch adapter with the conical tip of the screw.⁹

A recent study, carried out on a sample with an average age of 15 years and 3 months, shows that in all the patients, a correct

Class I relationship was achieved in a 5 month time mainly due to dental-alveolar effects. In this age, significant skeletal changes have not been proved.¹⁰

In this case-study the patient showed significant changes to SNA, SNB and ANB decreased from 11° to 5°. The decreased SNA (from 83° to 80°) according to Pancherz¹¹, Valant and Sinclair¹² shows an inhibition of the maxilla forward growth. This can also be explained by the theory of the skull base growth, which places the N point forward while the A point does not change, leading to a decrease of the SNA angle. Therefore, the SUS² seems to have, in this patient, a stopping effect on the maxillary growth.

SUS² helped the lower jaw to grow in a more forward direction; this, in combination with limited effects on the jaw, promotes the correction of the jaw sagittal relationships. In the patient, the SNB angle increased 3° during therapy. The more advanced lower jaw position is related to the increase of the mandibular length. This is due to a condylar growth induced by the bite-jumping.

The mandible anterior displacement causes the lengthening of the muscular and tendinous fibers, which are inserted on the condyle. The traction of these fibers on the bone surface is increased by the mandibular protrusion and induces a bone remodeling process. The jaw may also undergo a stable displacement, linked to a remodeling process of the articular fossa as a result of bite-jumping or to a temporary anterior displacement due to muscle conditioning type “Sunday bite”.¹³

In the present case, there was a significant mandibular lengthening (Ar-Pg distance increased 3 mm) and a morphological condyle variation in the anterior growth direction.

The SUS² had no effect on verticality (SN GoMe and Y-axis): according to the works of Weiland and Bantleon¹⁴, Covell et al.¹⁵, Pancherz et al.¹¹

There was an appreciable post-rotation of the occlusal plane (3° of variation). This is SUS² characteristic effect formerly reported in other studies and it is determined by the intrusion of the upper molars (high or combi TEO-like effect) and the protrusion and intrusion of the lower incisors.¹⁶

A further dental effect, produced by the SUS², is the endo-inclination of the upper incisors. In the patient, the index upper incisor / SN is decreased from 115° to 105° with a total variation of 10°. The incisal tipping variation may also have been resulted in a retraction of the A point, contributing to the reduction in the SNA value.

At the lower incisors level the SUS² causes intrusion and lip-tipping.¹⁶ In this case, both effects did not occur: the intrusion was contrasted by the extrusive action of the “anterior box” configured elastics; the lip tipping has been prevented, giving crown-lingual torque to the anterior sector of the arch.

The elastics' use contributed decisively to the bite closure and it was suspended only after obtaining a correct overbite.¹⁷

It was decided to use a mandibular retainer, composed of a posterior retro-incisal wires, vestibular archwires and Adams clasps on 4.6 and 3.6. The maxillary retainer was composed of an acrylic splint with anterior bite, vestibular archwires and Adams clasps on 1.6 and 2.6. The retainer range of protrusion has been chosen to maintain mandibular advancement and to consolidate the excellent level of correction achieved.

CONCLUSION

This Case report describes how it can be dealt with a case of a patient at the end of growth with a severe malocclusion, open

bite and arches' transversal incongruity by means of orthopedic-orthodontic treatment, when the patient refuses an orthodontic-surgical treatment, much more appropriate in such occlusal and skeletal problems, especially in subjects at the end of growth.

In this case, the orthopedic-orthodontic therapy demonstrated to be an excellent option instead the challenging orthognathic surgery and permitted a rapid resolution of the malocclusion, exploiting optimally the residual growth potential of the patient. The SUS² had a functional outcome, which resulted in a maxillary growth stop and a effective sagittal mandibular growth promotion. The SUS² effects, enhanced by elastics biomechanics, led to the bite closure and the achievement of the correct occlusion.

REFERENCES

- Moimaz SA, Garbin AJ, Lima AM, Lolli LF, Saliba O, Garbin CA. Longitudinal study of habits leading to malocclusion development in childhood. *BMC Oral Health*. 2014;4;14:96.
- Matsumoto MA, Romano FL, Ferreira JT, Valério RA. Open bite: diagnosis, treatment and stability. *Braz Dent J*. 2012;23(6):768-78.
- Galletto L, Urbaniak J, Subtelny JD. Adult anterior open bite. *Am J Orthod Dentofacial Orthop*. 1990;97(6):522-6.
- Nielsen IL. Vertical malocclusions: etiology, development, diagnosis and some aspects of treatment. *Angle Orthod*. 1991;61(4):247-60. Erratum in: *Angle Orthod* 1992;62(2):87.
- Epker BN, Fish L. Surgical-orthodontic correction of open-bite deformity. *Am J Orthod. Dentofacial Orthop*. 1977;71(3):278-99.
- Subtelny JD, Subtelny JD. Oral habits--studies in form, function, and therapy. *Angle Orthod*. 1973;43(4):349-83.
- Lamparski DG Jr, Rinchuse DJ, Close JM, Sciote JJ. Comparison of skeletal and dental changes between 2-point and 4-point rapid palatal expanders. *Am J Orthod Dentofacial Orthop*. 2003;123(3):321-8.
- Hanandeh BA, El-Bialy AA. Evaluating the effect of Sabbagh Universal Spring during treatment of growing class II malocclusions. *Int J Orthod Milwaukee*. 2010;21(4):13-24.
- Papadopoulos MA. Classification of the non compliance appliances used for Class II correction. In: Papadopoulos MA. *Orthodontic treatment of Class II noncompliant patient*. 1st ed. Mosby; 2006:9-15.
- Blackwood HO 3rd. Clinical management of the Jasper Jumper. *J Clin Orthod*. 1991;25(12):755-60.
- Pancherz H. The mechanism of Class II correction in Herbst appliance treatment. *Am J Orthod Dentofacial Orthop*. 1982;82(2):104-13.
- Valant JR, Sinclair PM. Treatment effects of the Herbst appliance. *Am J Orthod Dentofacial Orthop*. 1989;95(2):138-47.
- Sabbagh A. The Sabbagh Universal Spring (SUS). In: Papadopoulos MA. *Orthodontic treatment of Class II noncompliant patient*. 1st ed. Mosby; 2006:203-215.
- Weiland FJ, Bantleon HP. Treatment of Class II malocclusions with the Jasper Jumper appliance -- a preliminary report. *Am J Orthod Dentofacial Orthop*. 1995;108(4):341-50.
- Covell DA Jr, Trammell DW, Boero RP, West R. A cephalometric study of Class II division 1 malocclusion treated with the Jasper Jumper appliance. *Angle Orthod* 1999;69(4):311-20.
- Oztoprak MO, Nalbantgil D, Uyanlar A, Arun T. A cephalometric comparative study of class II correction with Sabbagh Universal Spring (SUS(2)) and Forsus FRD appliances. *Eur J Dent*. 2012;6(3):302-10.
- Jefferson Y. Anterior open bite--simplified non surgical technique to correct in adults. *Int J Orthod Milwaukee*. 2015;26(1):19-24.