

Agminated Blue Nevus: Two Case Reports and a Mini-review of the Literature

Giovanni Paolino¹, Dario Didona¹, Teresa Lopez¹, Francesco Alesini², Carmen Cantisani¹, Antonio G. Richetta¹, Giuseppe Soda², Stefano Calvieri¹

¹Dermatology Clinic, Sapienza University of Rome, Italy; ²Pathology, Department of Experimental Medicine, Sapienza University of Rome, Italy

Corresponding author:

Dario Didona, MD
Viale del Policlinico, 155
00186 Rome
Italy
dario.didona@gmail.com

Received: January 31, 2015

Accepted: February 1, 2016

ABSTRACT Agminated blue nevus (ABN) is a melanocytic nevus rarely mentioned in the literature and not well known. The term agminated is used when many blue nevi are clustered together in a sharply demarcated area ≤ 10 cm. Specific dermatoscopic features have not currently been clearly defined. We describe two cases of ABN and provide a review of the literature, reporting the main points in order to facilitate the diagnosis of this rare entity.

KEY WORDS: dermatoscopy, head, melanocytes, blue nevus, scalp

INTRODUCTION

Blue nevi are melanocytic lesions which are often observed in acral sites and the buttocks. However, the trunk, face, scalp, and mucosae may be also affected. Clinically, blue nevi are solitary lesions with a homogeneous dermatoscopic blue pattern. An agminated pattern may be present, causing clinical and pathological challenges. Agminated blue nevus (ABN) is a rare entity. Currently only 23 cases are described in the literature.

CASE REPORT

Case 1

A 60-year-old woman presented with an asymptomatic blue lesion on her forehead. The lesion had

been present since she was 40-year-old without any substantial changes in size, color, and texture. Her personal and family history was negative for malignancies. Clinical examination revealed a group of 4-5 blue-brown macules and papules of different sizes, within the perimeter of about 2 cm \times 3 cm (Figure 1, a). Dermatoscopy showed a homogeneous pattern in each of the "pigmented islands" with blue or brown-blue color. Hair follicles were clearly visible inside the pigmented papules and had no pigmented infiltration. The skin between the papules did not show pseudo-cicatrical regression or peppering (Figure 1, b). After a follow-up of 30 months, the lesions did not show any changes in size, color, and texture and, after consultation with the patient, we did not perform a biopsy.

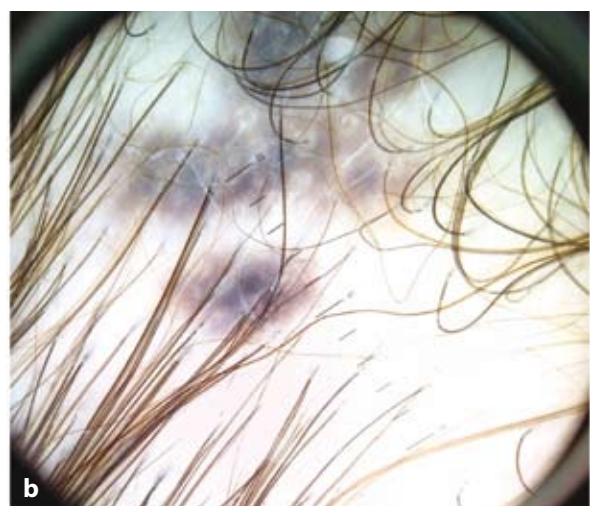
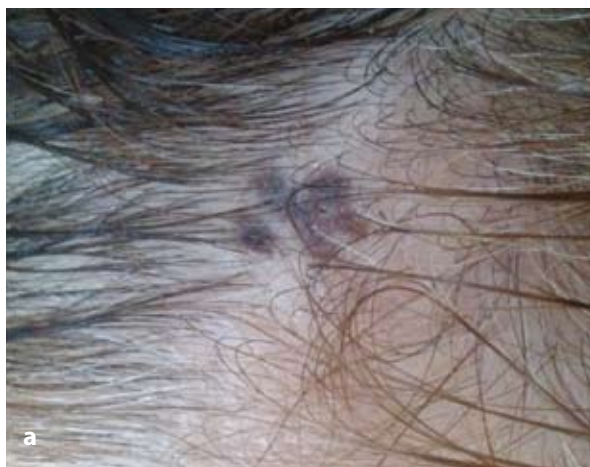

Figure 1. a) Asymptomatic blue lesion on the head, consisting of 3 macules interspersed with healthy skin. b) The dermatoscopy showed homogenous, well-circumscribed, bluish-to brown/gray lesions.

Case 2

A 58-year-old man presented with a melanocytic lesion in his vertex. The lesion was dome-shaped, with a dark blue color. Other multiple bluish nodular lesions were observed at the periphery of the lesion, interspersed with healthy skin. The central lesion had a diameter of 2.5 cm, while the peripheral ones had a maximum diameter of 1 cm. Dermatoscopic examination showed a homogenous blue-whitish pattern (Figure 2). Family and personal history were negative for melanoma. However, an excisional biopsy was performed. Histologically the lesion was characterized by dendritic melanocytes and islands of plump spindle melanocytes with abundant cytoplasm (Figure 3). Melanophages were present within and between the islands of spindle melanocytes. No mitoses, necrosis, or atypia were found (Figure 4). According to the clinical and dermatoscopic features, a diagnosis of agminated blue nevus was established.

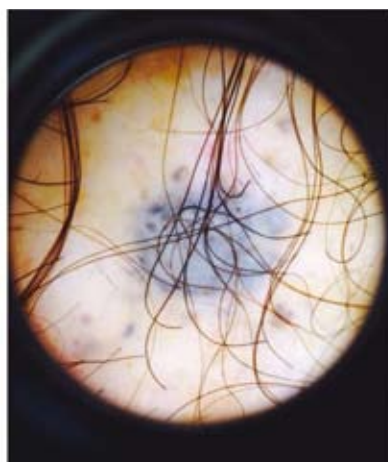


Figure 2. Five nodular melanocytic lesions, with a dermatoscopic homogeneous blue pattern surrounded by skin not affected by melanocytic proliferation.




Figure 3. Dendritic melanocytes together with islands of plump spindle melanocytes with abundant cytoplasm (hematoxylin and eosin, $\times 20$).

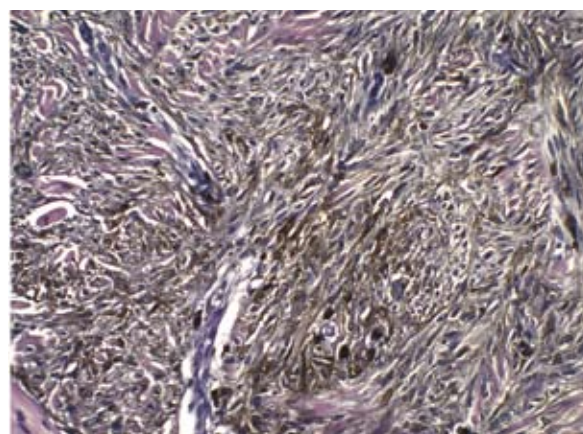


Figure 4. Pigmented spindle melanocytes. No mitoses, necrosis, or atypia were found (hematoxylin and eosin, $\times 40$).

DISCUSSION

ABN can be a dermatological pitfall. It is a rare lesion and its incidence is unknown. The differential diagnosis includes intradermal Spitz nevus, combined speckled lentiginous nevus (1), melanoma, and ma-

lignant blue nevus. Although different authors have used different terms such as “eruptive blue nevus” (2), “plaque-type blue nevus” (3), and “patch-type blue nevus” (4), the term “agminated blue nevus” has also been used when many blue nevi are clustered in a sharply demarcated area ≤ 10 cm (5).

Table 1. List of agminated blue nevi described in the literature (2-21)

AUTHOR	YEAR	AGE	SEX	SITE	CASE(S)	DERMATOSCOPY	HISTOLOGY
Upshaw	1947	9	M	Trunk	1	NP	Common blue nevus
Dorsey	1954	NP	NP	NP	2	NP	Cellular blue nevus
Pittman	1976	18	M	Leg	1	NP	Common blue nevus
Shenfield	1980	56	M	Epigastrium	1	NP	Common blue nevus
Atherton	1980	10	M	Trunk, limbs	1	NP	Common blue nevus
Hedricks	1981	14	M	Sternum	1	NP	Common blue nevus
Tuthill	1982	18	F	Collarbone	1	NP	Combined blue nevus
Ishibashi	1990	25, 16, 15	F, F, M	Chest, leg, shoulder	3	NP	Common blue nevus
Hofmann	1992	66, 36	NP	Arm, back	2	NP	Combined blue nevus
Misago	1993	67	M	Hypochondrium	1	NP	Combined blue nevus
Velez	1993	57	M	Shoulder	1	NP	Common blue nevus
Kiene	1995	29	F	Nasolabial area	1	NP	Combined blue nevus
El-ansary	2001	9	M	Sole	1	NP	Common blue nevus
Pizzichetta	2007	59	F	Leg	1	Homogeneous, linear pigmented structures. Darker-sulci.	Superficial blue nevus
Chen	2013	31	F	Forearm	1	NP	Common blue nevus
Milkova	2013	57	F	Forehead	1	NP	Common blue nevus
Rocha	2013	9	M	Thigh	1	Homogeneous pattern, diffuse brownish areas, regular network, numerous regularly distributed small dots.	Common blue nevus
Spring	2013	42	F	Ear	1	NP	Fusiform and epithelioid cells
Koba	2014	11	M	Sole	1	Homogeneous blue-grey pattern.	Common blue nevus
Our cases	2015	60, 58	F, M	Head	2	Homogeneous pattern. Absence of scar-like depigmentation and of pepper-like dots.	Cellular blue nevus. Fusiform and spindle melanocytes

*M: male; F: female; NP: not published

The word "agminated" derives from the Latin word *agminis* that means "troop" (6). ABN may be congenital or acquired. Although the pathogenesis is currently unknown, a case of ABN has been reported after an intense sunburn (2). However, in our cases the personal history was negative for injury.

The areas without pigment and with healthy skin ("saving areas") are probably due to the growth of nevus cells in the same anatomical area. In addition, several authors did not observe an important inflammatory infiltrate, explaining why the "saving areas" cannot be considered regression areas. Dermatoscopically this aspect has been confirmed by the absence of scar-like depigmentation areas and the absence of black/grayish, pepper-like dots, usually reported in regressed zones in malignant melanoma.

Heredity has not been established for this melanocytic proliferation, and only two papers have reported familial multiple blue nevi as an autosomal dominant trait (7,8). However, in our patients there was no family history of ABN or multiple blue nevi, as in other papers.

Few cases of ABN have been described in the literature so far (2-21) (Table 1). The first case of agminated blue nevus was described in 1947 by Upshaw *et al.* Since then, 22 other cases have been reported (Table 1). While common blue nevus is more common in female patients, with a 3:12 male-to-female ratio (1), ABN does not seem to be more common in either gender. Furthermore, while common blue nevi most commonly develop on the dorsal areas of the extremities (21), ABN has an equal distribution between the trunk, extremities, and head/neck. Although both our cases were located on the head, this is a rarely involved site. Indeed, only one other ABN on the head has been reported in the literature (18).

Regarding age, while common blue nevus usually occurs in the fifth-sixth decade (1), for ABN the median age is usually lower, at 31 years. However, age does not seem to be a key factor for the onset of ABN.

According to the literature, ABN presents with dermatoscopic patterns similar to the ones usually found in common blue nevi. However, according to the few dermatoscopic cases reported in the literature, a specific pattern has not yet been found. In this regard, a homogenous structureless pigmented pattern of various shades has been the commonest feature reported. Only Pizzichetta *et al.* have described linear pigmented structures appearing as "darker sulci" in ABN (9). In our two cases, we observed a blue-brownish pattern and a blue homogeneous pattern without the presence of darker sulci.

CONCLUSION

The clinical, dermatoscopic, and pathological features of ABN reported in our paper expand the spectrum of ABN in the literature. When possible, a surgical excision is advised because differential diagnosis with malignant melanoma is not always possible. However, our report also highlights that a careful dermatoscopic analysis can be useful in establishing a correct diagnosis.

References:

1. Ferrara G, Soyer HP, Malvey J, Piccolo D, Puig S, Sopeña J, *et al.* The many faces of blue nevus: a clinicopathologic study. *J Cutan Pathol* 2007;34:543-51.
2. Hendricks WM. Eruptive blue nevi. *J Am Acad Dermatol* 1981;4:50-3.
3. Pittman JL, Fisher BK. Plaque-type blue nevus. *Arch Dermatol* 1976;112:1127-8.
4. Misago N, Narisawa Y, Kohda H. A combination of speckled lentiginous nevus with patch-type blue nevus. *J Dermatol* 1993;20:643-7.
5. Vélez A, del-Río E, Martín-de-Hijas C, Furió V, Sánchez Yus E. Agminated blue nevi: case report and review of the literature. *Dermatology* 1993;186:144-8.
6. Chen T, Kurwa HA, Trotter MJ, Haber RM. Agminated blue nevi in a patient with dermatomyositis. *J Am Acad Dermatol* 2013;68:e52-3.
7. Knoell KA, Nelson KC, Patterson JW. Familial multiple blue nevi. *J Am Acad Dermatol* 1998;39:322-5.
8. Blackford S, Roberts DL. Familial multiple blue naevi. *Clin Exp Dermatol* 1991;16:308-9.
9. Pizzichetta MA, Soyer HP, Massone C, Cerroni L. Clinical and dermoscopic features of agminated blue nevus. *Arch Dermatol* 2007;143:1225-6.
10. Dorsey CS, Montgomery H. Blue nevus and its distinction from Mongolian spot and the nevus of Ota. *J Invest Dermatol* 1954;22:225-36.
11. Shenfield HT, Maize JC. Multiple and agminated blue nevi. *J Dermatol Surg Oncol* 1980;6:725-8.
12. Atherton DJ, Wells RS. Confluent and reticulate papillomatosis. *Clin Exp Dermatol* 1980;5:465-9.
13. Tuthill RJ, Clark WH Jr, Levene A. Pilar neurocristic hamartoma: its relationship to blue nevus and equine melanotic disease. *Arch Dermatol* 1982;118:592-6.
14. Ishibashi A, Kimura K, Kukita A. Plaque-type blue

- nevus combined with lentigo (nevus spilus). *J Cutan Pathol* 1990;17:241-5.
15. Hofmann U, Schacht B, Megahed M. Grouped and combined blue nevi. *Hautarzt* 1992;43:517-9.
 16. Kiene P, Brodersen JP, Fölster-Holst R. "Blue" variant of naevus spilus. *Hautarzt* 1995;46:349-51.
 17. El-Ansary MS, Al-Fouzan AS, Hassab-El-Naby HMM. Agminated blue nevus: a case report. *GJDV* 2001;8:50-2
 18. Milkova L, Treudler R, Simon JC, Kunz M. Agminated blue naevi in a patient with EMO syndrome. *Acta Derm Venereol* 2013;93:104-5.
 19. Rocha CR, Graziotin TC, Rey MC, Luzzatto L, Bonamigo RR. Congenital agminated melanocytic nevus-case report. *An Bras Dermatol* 2013;88:170-2.
 20. Spring P, Perrier P, Erba P, Hagmann P, Mihm MC, Hohl D. Large agminated cellular 'plaque-type' blue nevus surrounding the ear: a case and review. *Dermatology* 2013;227:21-5.
 21. Koba S, Mori M, Misago N, Narisawa Y. Agminated blue naevus on the sole. *J Eur Acad Dermatol Venereol* 2014;30:334-5.

