

DOI No: 10.15538/sejodr-2015-2468

Original Article

SEJODR

# Craniofacial morphology in Turner syndrome patients treated with growth hormone

Juloski, Jovana \*; Scepan, Ivana \*; Stefanovic, Neda \*; Pajevic, Tina \*; Markovic, Evgenija \*; Glisic, Branislav \*

\* Department of Orthodontics, School of Dental Medicine, University of Belgrade, Serbia

## ABSTRACT

**Introduction:** In addition to well-established physical characteristics, Turner syndrome patients have distinct craniofacial morphology. Since short stature is the most typical characteristic, Turner syndrome patients are commonly treated with growth hormone in order to increase final height. At the same time, growth hormone treatment was found to influence craniofacial growth and morphology in various groups of treated patients. Whereas craniofacial characteristics of Turner syndrome patients are well documented, comparatively little is known of craniofacial morphology of those who are treated with growth hormone.

**Aim:** The aim of this study was to investigate craniofacial morphology in Turner syndrome patients treated with growth hormone in comparison to healthy females.

**Materials and methods:** The cephalometric evaluation was conducted on twenty lateral cephalograms of Turner syndrome patients ( $13.53 \pm 4.04$  years) treated with growth hormone for at least one year ( $4.94 \pm 1.92$  years in average). As a control group, forty lateral cephalograms of healthy female controls, who matched Turner syndrome patients by chronological ( $11.80 \pm 2.37$  years) and skeletal age, were used. Eleven angular, seven linear measurements and six dimensional ratios were measured to describe craniofacial morphology.

**Results:** The results obtained for angular measurements, in cephalometric analyses for Turner syndrome patients treated with growth hormone, revealed bimaxillary retrognathism. The linear measurements indicated longer mandibular ramus, anterior cranial base and both anterior and posterior facial heights. However, posterior cranial base and maxilla were in proportion to the anterior cranial base, when comparing dimensional ratios. Anterior cranial base, maxilla and mandibular ramus were larger in proportion to mandibular body; as well as posterior facial height was when compared to anterior facial height.

Turner syndrome patients treated with growth hormone expressed distinct craniofacial morphology compared to controls. Apart from retrognathic maxilla and mandible, they exhibited overdeveloped mandibular ramus height and elongated facial heights.

**Conclusions:** The results from this study have shown that Turner syndrome patients treated with growth hormone expressed distinct craniofacial morphology compared to controls. These differences include retrognathic maxilla and mandible, overdeveloped mandibular ramus height and elongated facial heights. This specific craniofacial morphology was formed under combined influence of X chromosome deficiency and growth hormone therapy.

Juloski J, Scepan I, Stefanovic N, Pajevic T, Markovic E, Glisic B. Craniofacial morphology in Turner syndrome patients treated with growth hormone. *South Eur J Orthod Dentofac Res.* 2015;2(1):14-19.

Submitted: December 01, 2014; Revised: January 25, 2015; Published: May 14, 2015

## Corresponding Author:

Juloski Jovana

Department of Orthodontics, School of Dental Medicine,  
University of Belgrade,

Gastona Gravijea 2, 11000 Belgrade, Serbia

e-mail: [juloski.jovana@gmail.com](mailto:juloski.jovana@gmail.com)

## INTRODUCTION

Turner syndrome (TS) patients can be identified by short stature and gonadal dysgenesis.<sup>1</sup> In addition to these features, characteristic facial and craniofacial morphology have been established. Most commonly reported craniofacial characteristics are reduced lengths of cranial base, maxilla and mandible, as well as flattened cranial base, maxillary and mandibular retrognathism and retroinclination.<sup>2-7</sup>

Chromosome imbalance, lack of X chromosome linked genes expression, growth hormone resistance and lack of estrogen should be taken into consideration when discussing these girls' growth disturbances. The absence of X chromosome, which causes this syndrome, affects almost all structures of the craniofacial complex in terms of reducing their growth and altering growth direction.<sup>8,9</sup> Additionally, haploinsufficiency of SHOX (short stature homeobox) gene, which is located in pseudoautosomal region 1 of X chromosome, influences skeletal and craniofacial growth and development.<sup>10</sup> It is assumed that TS girls have short stature as a result of growth hormone or insulin-like growth factors resistance, even though they do not have classic growth hormone deficiency.<sup>11</sup> The lack of estrogen reduces speed of growth and skeletal maturation which is especially pronounced after the age of six or seven.<sup>11</sup> Growth disorders in TS girls, both skeletal and craniofacial, are complex and cannot be explained by the influence of any of these factors individually. Since short stature is the most common characteristic and evident repercussion of skeletal growth disorder in TS patients, they are routinely treated with growth hormone (GH).<sup>12,13</sup> GH therapy accelerates growth and improves their final body height up to 15 cm above predicted height.<sup>14,15</sup>

Besides its positive effects on body height, GH seems to influence craniofacial growth.<sup>16-20</sup> GH treatment was found to increase the length of maxilla and mandible,<sup>18-21</sup> as well as anterior and posterior facial heights<sup>17-19,22</sup> and cranial base length.<sup>17,21,23</sup> Afore cited data are the results from studies that have investigated GH effects on craniofacial morphology in growth hormone deficient children,<sup>16-18</sup> children born too small for their gestational age<sup>21,22</sup> and children who have been subjected to whole body radiation.<sup>20</sup>

As far as TS patients are concerned, most of the preceding studies have investigated craniofacial morphology in those who were not treated with GH. In these studies, distinct craniofacial morphology was established: flattened cranial base with reduced length, underdeveloped, retrognathic and retroinclined maxilla and mandible.<sup>2-7</sup> Only a few studies have evaluated GH influence on craniofacial morphology in TS patients.<sup>24-26</sup> It was noticed that after two years of GH treatment both maxilla and mandible achieved average length,<sup>24,25</sup> their anteroposterior position did not improve,<sup>24-26</sup> while mandible was anteriorly rotated.<sup>24,26</sup> Taking into consideration these findings it could be expected that craniofacial morphology in TS patients who are treated with GH has certain distinct characteristics.

Although craniofacial morphology in Turner syndrome patients is thoroughly described, data on those receiving growth hormone are still insufficient. The aim of this study was to investigate craniofacial morphology in Turner syndrome patients treated with growth hormone. The null hypothesis was that there are no differences between craniofacial morphology in Turner syndrome patients treated with growth hormone and healthy females.

## MATERIALS AND METHODS

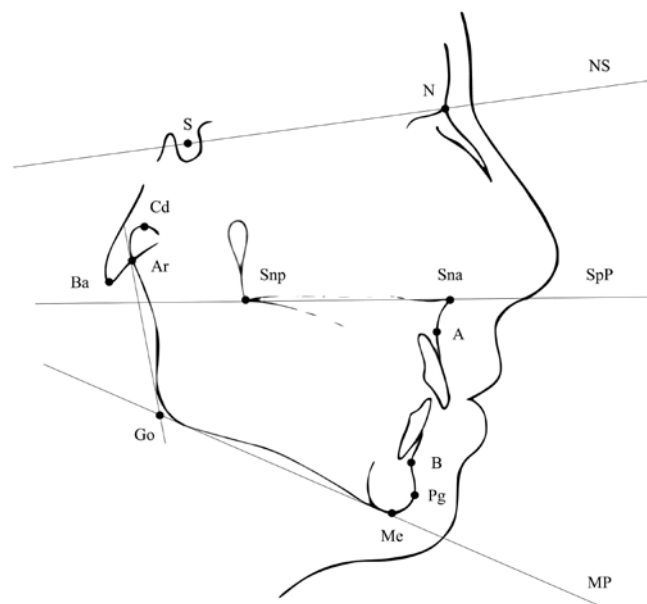
The Ethics Committee of School of Dental Medicine, University of Belgrade approved this study protocol (36/15). Informed consent was obtained from investigated individuals or their parents.

The study group comprised of 20 lateral cephalograms of TS patients ( $13.53 \pm 4.04$  years old) who were treated with GH for at least one year ( $4.94 \pm 1.92$  years in average). All patients were treated with GH according to administration protocol at the Institute for Mother and Child Healthcare of Serbia "Dr. Vukan Čupić". GH was administered as soon as height was lower than the tenth percentile of the normal female growth curve. Starting dose was 0.045-0.050 mg GH / kg of body weight per day which was adapted according to patient's growth response. The duration of GH therapy was also determined according to patient's height and growth response. The diagnosis was established using genetic karyotyping by routine chromosomal analysis performed on peripheral blood lymphocytes. The most common karyotype was 45,X (70%), followed by mosaic (30%) and isochromosome karyotype (10%).

Forty lateral cephalograms of healthy females, matching TS patients by chronological ( $11.80 \pm 2.37$  years) and skeletal age, were included in control group. The records were obtained at the Department of Orthodontics, School of Dental Medicine in Belgrade.

The lateral cephalograms were taken under standardized conditions, with teeth in centric occlusion and head fixed in a cephalostat. All cephalograms were traced and analyzed by one investigator. A caliper was used to measure distances between reference points (marked in pencil on a mat acetate film) to the nearest millimeter. Angular measurements were measured to the nearest degree, using a protractor. In case of duplicated structure, reference point was marked at the midpoint.

Figure 1. Cephalometric points and planes used in this study.



The following cephalometric points and planes were used in this study (Figure 1): N, Nasion: the most anterior point of the frontonasal suture; S, Sella: the midpoint of the sella; Cd, Condylion: the most posterior superior point of the condyle; Ar, Articulare: a constructed point at the intersection of the images of the posterior margin of the ramus and the outer margin of the cranial base; Ba, Basion: lowest point on the anterior margin of the foramen magnum; Go, Gonion: a constructed point at the intersection of the ramus tangent line and mandibular plane; Me, Menton: the most inferior point of the outline of the symphysis; Pg, Pogonion: the most anterior point of the bony chin; B, Point B: the deepest point on the outer contour of the mandibular alveolar process; A, Point A: the deepest point on the outer contour of the maxillary alveolar process; Sna, Spina nasalis anterior: the most anterior point of the tip of the anterior nasal spine; Snp, Spina nasalis posterior: the intersection of the continuation of the anterior wall of the pterygomaxillary fissure and the nasal floor; NS, anterior cranial base: the line from nasion through sella; SpP, Spina planum: the line through spina nasalis anterior and posterior; MP, Mandibula planum: the tangent to the lower border of the mandible through menton.

Eleven angular measurements were used to describe anteroposterior (SNA, SNB, ANB) and vertical position of maxilla and mandible (NS/SpP, NS/MP, SpP/MP), as well as cranial base angle (NSBa) and angles of Bjork's polygon (NSAr, SARGo, ArGoMe, sum of angles). Seven linear measurements were used to estimate the size of the maxilla (Snp - Sna), the mandibular body (Go - Pg) and ramus (Cd - Go), as well as the anterior and posterior cranial base (N - S, S - Ba) and facial heights (S - Go, N - Me). Six dimensional ratios were calculated to compare the lengths of maxilla, mandibular body and posterior cranial base to anterior cranial base (Snp-Sna/N - S, Go - Pg/N - S, S - Ba/N - S respectively) maxilla and mandibular ramus to mandibular body (Snp - Sna/Go - Pg, Cd - Go/Go - Pg) and posterior to anterior facial height (S - Go/N - Me).

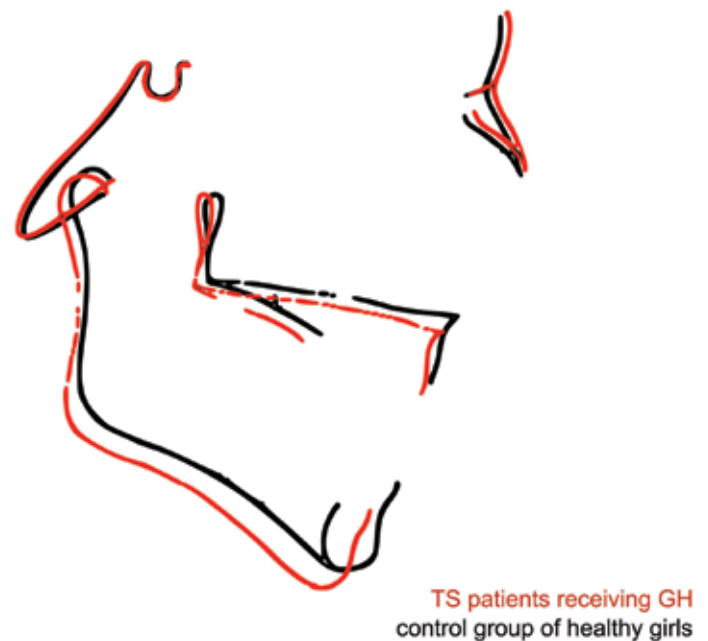
The cephalometric measurements were performed twice on ten randomly selected radiographs, five from each group, in an interval of four weeks. In order to estimate the measurement error, Dahlberg's formula was used  $\sqrt{(\sum d^2/2N)}$ , where d is the difference between the two measurements and N is the number of cephalograms. The intra - individual error of measurement was generally small, did not exceed 0.8 degrees for the angular measurements and 0.3 mm for the linear measurements.

The Kolmogorov - Smirnov test confirmed normal distribution pattern of cephalometric measurements which allowed the use of parametric statistical tests. Independent samples t test was used to compare measurements between study and control group in order to establish whether differences were statistically significant. The Statistical Package for Social Sciences, version 18 (SPSS inc.; Chicago, IL, USA) was used for statistical analysis.


## RESULTS

The results obtained in cephalometric analyses of Turner syndrome patients treated with growth hormone and control are summarized in Table 1. All angular measurements, except for SNA and SNB angles, were similar in both groups. In TS patients treated with GH, both maxilla (SNA) and mandible (SNB) were significantly repositioned, compared to control group (Figure 2). Some of the linear measurements (Cd - Go, N - S, S - Go, N - Me) were larger in examined group indicating longer mandibular ramus (Figure 3), anterior cranial base and

*Figure 2. Tracings of the Turner syndrome patients treated with growth hormone (red) and healthy controls (black) based on the mean cephalometric variables for each group, superimposed on the anterior cranial base (NS) and registered at the sella point (S).*



*Figure 3. Tracings of the Turner syndrome patients treated with growth hormone (red) and healthy controls (black) based on the mean cephalometric variables for each group, superimposed on the mandibular plane (MP).*



both anterior and posterior facial heights (Figure 2). However, when comparing dimensional ratios, we found that posterior cranial base and maxilla were in proportion to the anterior cranial base (S-Ba/N - S, Snp-Sna/N - S), while mandibular body was found to be smaller compared to anterior cranial base (Go - Pg/N - S) in TS patients compared to healthy controls. Both maxilla and mandibular ramus were larger in proportion to mandibular body (Snp - Sna/Go - Pg and Cd - Go/Go - Pg) as well as posterior facial height compared to anterior facial height (S - Go/N - Me) in study group.

## DISCUSSION

According to the results obtained in this study, the null hypotheses was rejected. Turner syndrome patients treated with growth hormone exhibited aberrant craniofacial morphology when compared to healthy females. The differences were most pronounced in anteroposterior position of jaws, facial heights, mandibular ramus and anterior cranial base lengths. The X chromosome deficiency in combination with GH therapy effects led to this specific craniofacial morphology in TS patients.

All TS subjects included in this study were treated with GH for not less than one year, while some of them were treated for as long as seven years. Most of the included subjects started GH treatment before the age of seven. According to the results from previous studies, early initiation of treatment is necessary in order to have significant effects on craniofacial development.<sup>18,25,27</sup> Since GH therapy effects are age dependent, it could have been beneficial if the subjects were divided into age groups. Still, the number of investigated TS patients in subgroups would not have been sufficient for adequate statistical analyses. In the view of the fact that short stature was the main indication for GH therapy in TS patients included in this study, it was not possible to influence the age of treatment outset nor the duration of therapy. Both of these parameters were determined by the pediatric endocrinologist dependent on patients' height and growth response.

Since craniofacial morphology did not differ significantly between patients with various karyotypes,<sup>2,3,7,24</sup> all karyotypes were included in this study. Even though 45,X TS patients had more variables differing from controls than other TS karyotypes, the only significant difference found was anteroposterior position of the mandible.<sup>28</sup> The karyotypes of TS patients selected for the study group were distributed somewhat differently compared to the average TS population. Monosomy of X chromosome was most frequent, similarly to an average TS population in Serbia. On the other hand, mosaic karyotypes were more frequent than isochromosomes, in contrast to what was expected.<sup>29</sup> It may be speculated that distribution of karyotypes did not alter the results in this study, since different karyotypes did not influence craniofacial morphology significantly.

Anteroposterior position of maxilla and mandible in Turner

syndrome patients treated with growth hormone differed significantly from healthy controls. Both jaws were retrognathic, even though maxillary and mandibular body average length increased under the influence of GH therapy. These results are in accordance with previous studies that have also found retrognathic jaws<sup>24-26</sup> and increase in mandibular ramus<sup>24-26</sup> and corpus lengths<sup>25,26</sup> in TS girls treated with GH. Bimaxillary retrognathism, also present in TS girls<sup>2,3,5-7</sup> and adult patients<sup>4,8</sup> that were not treated with GH, used to be explained by flattened cranial base<sup>3</sup> and reduced lengths of maxilla and mandible.<sup>2,8</sup> In TS patients treated with GH both jaws had average length, still their position was not orthognathic. On the other hand, the lack of X chromosome was proved to cause retrognathism<sup>8,9</sup> which is present even prenatally in TS patients.<sup>30</sup> The results of this study suggest that retrognathic position of maxilla and mandible in TS patients, caused mostly by X chromosome deficiency, cannot be corrected by GH treatment.

In accordance with previous investigations, vertical position of maxilla and mandible did not differ between groups. The growth of mandibular ramus under the influence of GH treatment causes anterior rotation of mandible in TS patients,<sup>24,26</sup> as well as in idiopathic short stature boys and GH deficient boys.<sup>18</sup> Similarly, in this study mandibular ramus height was found to be significantly larger in TS patients treated with GH compared to healthy controls and also overdeveloped in comparison to mandibular corpus length. However, even in TS patients naive to GH treatment ramus was found to be longer in proportion to corpus.<sup>3,5</sup> The fact that the vertical position of both jaws was similar between investigated groups in our study and that mandibular ramus height was larger in the study group, confirmed the earlier findings that GH therapy influences vertical position of jaws.

In contrast to the findings from previous studies, which found flattened cranial base angle and shorter posterior cranial base length in TS patients,<sup>2,3,5-8,30</sup> no significant differences were found between groups, excluding larger anterior cranial base in study group. Posterior to anterior cranial base ratio proved that in TS patients treated with GH, cranial base was normally developed. This finding can be explained by the results from clinical and experimental studies which found that GH has positive effects on enchondral ossification centers in the cranial base.<sup>17,18,27</sup> Additionally, the age of patients receiving GH has an impact on craniofacial growth, the effects being more pronounced in the younger patients.<sup>18,27</sup> The starting age of GH therapy, which was before the age of 7 in most of the patients in our study, contributed to normal cranial base development. Earlier studies of TS patients did not find significant differences when comparing annual changes of cranial base angle and lengths during GH therapy,<sup>24,25</sup> nevertheless growth rate and pattern were similar to healthy controls.<sup>31</sup>

The anterior cranial base was found to be longer in examined group, in spite of that the ratios imply that anterior cranial base

was proportionately developed when compared to posterior cranial base and maxillary length. Interestingly, mandibular corpus which was of average length in the examined group was found to be underdeveloped when compared to maxillary corpus and anterior cranial base length. These results indicate that mandibular corpus, which was significantly shorter in TS patients naive to GH treatment,<sup>2,3,5-7</sup> could not keep up with maxillary corpus and anterior cranial base length, despite the fact that it increased the length in patients treated with GH. On the other hand, mandibular ramus was overgrown in comparison to mandibular corpus most probably due to bone apposition on secondary mandibular condylar cartilage.<sup>32</sup> Increased length of mandibular ramus, in combination with the average length of posterior cranial base, was considered to contribute to increased facial heights in study group.<sup>18,19,21</sup> The ratio between posterior and anterior facial height indicated that the effects were more pronounced on posterior facial height.

The results from this study have shown that Turner syndrome patients treated with growth hormone expressed distinct craniofacial morphology compared to healthy controls. These differences include retrognathic maxilla and mandible, overdeveloped mandibular ramus height and elongated facial heights. This specific craniofacial morphology was formed under combined influence of X chromosome deficiency and growth hormone therapy.

Further carefully designed studies are necessary to explore possibility of changing craniofacial morphology in Turner syndrome patients by including orthodontic growth modification treatment.

## ACKNOWLEDGEMENTS

This research was supported by the Serbian Ministry of Education and Science, grant no. 175075.

*Table 1. The results obtained in cephalometric analyses of Turner syndrome patients treated with growth hormone and healthy females*

	TS patients receiving GH (n=20)			Control group of healthy girls (n=40)			T-test for independent samplest
	Mean	SD	SE	Mean	SD	SE	P value for independent samples
Angular measurements							
SNA (°)	78.09	4.83	1.08	81.57	4.33	0.68	.010*
SNB (°)	75.01	4.18	0.94	78.04	4.28	0.68	.012*
ANB (°)	3.09	1.23	0.28	3.53	2.39	0.38	.355
NS/SpP (°)	9.34	4.36	0.98	8.43	3.82	0.60	.433
NS/MP (°)	31.99	6.58	1.47	33.59	6.16	0.97	.373
SpP/MP (°)	22.65	6.05	1.35	24.85	6.74	1.07	.209
NSBa (°)	132.02	5.65	1.26	130.77	5.50	0.87	.420
NSAr (°)	125.71	6.80	1.52	122.75	5.38	0.85	.099
SArGo (°)	143.35	8.36	1.87	145.15	5.74	0.91	.395
ArGoMe (°)	123.22	9.26	2.07	125.72	7.43	1.17	.302
Sum of angles (°)	392.24	6.56	1.47	393.62	6.13	0.97	.438
Linear measurements							
Snp-Sna (mm)	51.78	4.41	0.99	49.63	3.24	0.51	.063
Go-Pg (mm)	67.67	5.37	1.20	67.62	4.57	0.72	.972
Cd-Go (mm)	55.77	5.86	1.31	51.26	5.51	0.87	.007*
N-S (mm)	68.05	4.77	1.07	64.97	3.36	0.53	.015*
S-Ba (mm)	43.92	5.48	1.23	42.55	2.96	0.47	.307
S-Go (mm)	77.68	8.42	1.88	69.60	4.92	0.78	.001*
N-Me (mm)	113.46	11.29	2.52	106.41	6.96	1.10	.017*
Dimensional ratios							
Snp-Sna/N-S (%)	76.09	4.67	1.04	76.43	3.84	0.61	.783
Snp-Sna/Go-Pg (%)	76.66	5.42	1.21	73.57	5.09	0.80	.041*
Go-Pg/N-S (%)	99.45	5.17	1.16	104.20	6.68	1.06	.004*
Cd-Go/Go-Pg (%)	82.81	7.57	1.69	75.85	6.96	1.10	.001*
S-Ba/N-S (%)	64.81	9.15	2.05	65.57	4.47	0.71	.727
S-Go/N-Me (%)	68.50	3.67	0.82	65.52	4.21	0.66	.007*

\*P < 0.05.

Standard deviation (SD); Standard error (SE).

## REFERENCES

1. Ranke MB, Saenger P. Turner's syndrome. *Lancet*. 2001;358(9278):309-14.
2. Rongen-Westerlaken C, vd Born E, Prah-Andersen B, Rikken B, Teunenbroek V, Kamminga N, et al. Shape of the craniofacial complex in children with Turner syndrome. *J Biol Buccale*. 1992;20(4):185-90.
3. Midtbø M, Wisth PJ, Halse A. Craniofacial morphology in young patients with Turner syndrome. *Eur J Orthod*. 1996;18(3):215-25.
4. Babic M, Glisic B, Scepan I. Mandibular growth pattern in Turner's syndrome. *Eur J Orthod*. 1997;19(2):161-4.
5. Grön M, Pietilä K, Alvesalo L. The craniofacial complex in 45,X/46,XX females. *Arch Oral Biol*. 1999;44(12):1077-84.
6. Perkiömäki MR, Kyrkanides S, Niinimaa A, Alvesalo L. The relationship of distinct craniofacial features between Turner syndrome females and their parents. *Eur J Orthod*. 2005;27(1):48-52.
7. Dumancic J, Kaic Z, Varga ML, Lauc T, Dumic M, Milosevic SA, et al. Characteristics of the craniofacial complex in Turner syndrome. *Arch Oral Biol*. 2010;55(1):81-8.
8. Babić M, Scepan I, Mičić M. Comparative cephalometric analysis in patients with X-chromosome aneuploidy. *Arch Oral Biol*. 1993;38(2):179-83.
9. Alvesalo L. Human sex chromosomes in oral and craniofacial growth. *Arch Oral Biol*. 2009;54 Suppl 1:S18-24.
10. Oliveira CS, Alves C. The role of the SHOX gene in the pathophysiology of Turner syndrome. *Endocrinol Nutr*. 2011;58(8):433-42.
11. Gravholt CH. Epidemiological, endocrine and metabolic features in Turner syndrome. *Eur J Endocrinol*. 2004;151(6):657-87.
12. Kirk J. Indications for growth hormone therapy in children. *Arch Dis Child*. 2012;97(1):63-8.
13. Saenger P, Wikland KA, Conway GS, Davenport M, Gravholt CH, Hintz R, et al. Recommendations for the diagnosis and management of Turner syndrome. *J Clin Endocrinol Metab*. 2001;86(7):3061-9.
14. Ross J, Lee PA, Gut R, Germak J. Impact of age and duration of growth hormone therapy in children with Turner syndrome. *Horm Res Paediatr*. 2011;76(6):392-9.
15. Sas TC, de Muinck Keizer-Schrama SM, Stijnen T, Jansen M, Otten BJ, Gera Hoorweg-Nijman JJ, et al. Normalization of height in girls with Turner syndrome after long-term growth hormone treatment: results of a randomized dose-response trial. *J Clin Endocrinol Metab*. 1999;84(12):4607-12.
16. Litsas G. Growth hormone therapy and craniofacial bones: a comprehensive review. *Oral Dis*. 2013;19(6):559-67.
17. Cantu G, Buschang PH, Gonzalez JL. Differential growth and maturation in idiopathic growth-hormone-deficient children. *Eur J Orthod*. 1997;19(2):131-9.
18. Kjellberg H, Wikland KA. A longitudinal study of craniofacial growth in idiopathic short stature and growth hormone-deficient boys treated with growth hormone. *Eur J Orthod*. 2007;29(3):243-50.
19. Funatsu M, Sato K, Mitani H. Effects of growth hormone on craniofacial growth. *Angle Orthod*. 2006;76(6):970-7.
20. Forsberg CM, Krekmanova L, Dahllöf G. The effect of growth hormone therapy on mandibular and cranial base development in children treated with total body irradiation. *Eur J Orthod*. 2002;24(3):285-92.
21. Van Erum R, Mulier M, Carels C, Verbeke G, de Zegher F. Craniofacial growth in short children born small for gestational age: effect of growth hormone treatment. *J Dent Res*. 1997;76(9):1579-86.
22. Van Erum R, Carels C, Verbeke G, de Zegher F. Craniofacial growth in short children born small for gestational age: two years follow-up after high-dose growth hormone treatment. *J Craniofac Genet Dev Biol*. 1997;17(4):184-9.
23. Poole AE, Greene IM, Buschang PH. The effect of growth hormone therapy on longitudinal growth of the oral facial structures in children. *Prog Clin Biol Res*. 1982;101:499-516.
24. Rongen-Westerlaken C, vd Born E, Prah-Andersen B, von Teunenbroek A, Manesse P, Otten BJ, et al. Effect of growth hormone treatment on craniofacial growth in Turner's syndrome. *Acta Paediatr*. 1993;82(4):364-8.
25. Hass AD, Simmons KE, Davenport ML, Proffit WR. The effect of growth hormone on craniofacial growth and dental maturation in Turner syndrome. *Angle Orthod*. 2001;71(1):50-9.
26. Simmons KE. Growth hormone and craniofacial changes: preliminary data from studies in Turner's syndrome. *Pediatrics*. 1999;104(4 Pt 2):1021-4.
27. Van Erum R, Mulier G, Carels C, de Zegher F. Craniofacial growth and dental maturation in short children born small for gestational age: effect of growth hormone treatment. *Horm Res*. 1998;50(3):141-6.
28. Rizell S, Bärrenas ML, Andlin-Sobocki A, Stecksén-Blicks C, Kjellberg H. 45,X/46,XX karyotype mitigates the aberrant craniofacial morphology in Turner syndrome. *Eur J Orthod*. 2013;35(4):467-74.
29. Djordjević VA, Jovanović JV, Pavković-Lučić SB, Drakulić DD, Djurović MM, Gotić MD. Cytogenetic findings in Serbian patients with Turner's syndrome stigmata. *Genet Mol Res*. 2010;9(4):2213-21.
30. Andersen E, Sonnesen L, Kjaer MS, Fischer Hansen B, Kjaer I. The prenatal cranial base complex and hand in Turner syndrome. *Eur J Orthod*. 2000;22(2):185-94.
31. Juloski J, Glisic B, Scepan I, Milasin J, Mitrovic K, Babic M. Ontogenetic changes of craniofacial complex in Turner syndrome patients treated with growth hormone. *Clin Oral Investig*. 2013;17(6):1563-71.
32. Solem RC, Eames BF, Tokita M, Schneider RA. Mesenchymal and mechanical mechanisms of secondary cartilage induction. *Dev Biol*. 2011;356(1):28-39.