

UPPER AIRWAY BLOCKS FOR AWAKE DIFFICULT AIRWAY MANAGEMENT

Tatjana Stopar Pintarič

Clinical Department of Anaesthesiology and Intensive Therapy, University Medical Centre and Institute of Anatomy, Medical Faculty, Ljubljana, Slovenia

SUMMARY – Airway anesthesia is pivotal for successful awake intubation provided either topically or by blocks. Airway blocks are considered technically more difficult to perform and carry a higher risk of complications. However, in experienced hands, they can be useful as they provide excellent intubating conditions. For complete upper airway anesthesia, bilateral glossopharyngeal and superior laryngeal nerve blocks with translaryngeal injection are required. Superior laryngeal nerve block and translaryngeal injection can be performed easily, safely and with a high success rate in patients with normal anatomy. In those with difficult landmarks, ultrasound can be of assistance. For the superior laryngeal nerve block, other targets than the nerve itself must be established to make the technique consistently successful, easy to teach, learn and perform. The same applies to the translaryngeal injection, where the use of ultrasound is necessary for correct midline identification. Intraoral glossopharyngeal nerve block is also safe and easy to perform, but associated with long lasting discomfort. Bilateral extraoral peristyloid approach should be discouraged since inadvertent blocks of the closely adjacent vagus nerve cannot be prevented in this location. A safe and easy method of blocking the distal portions of the glossopharyngeal nerve for awake intubation is therefore required.

Key Words: *Airway Obstruction; Airway Management – Methods; Respiratory System – Ultrasonography; Anesthesia, Local; Nerve Blocks; Wakefulness; Glossopharyngeal Nerve Block; Superior Laryngeal Nerve Block; Translaryngeal Block*

Introduction

Awake intubation remains the gold standard for anticipated difficult airway management where performance time and ease, patient comfort and safety primarily depend on the quality of upper airway anesthesia provided either topically or by regional blocks¹. Topical anesthesia is relatively easy, effective and well tolerated, but not without risks. In a patient with a tongue base abscess, systemic local anesthetic toxicity has been reported after topical anesthesia with

lidocaine for awake fiberoptic intubation². In heavily sedated patients with unstable cervical fracture, insufficient topicalization led to laryngospasm with total upper airway obstruction as a result of fiberoptic pharyngeal mucosa stimulation³. Airway blocks, on the other hand, are considered technically more difficult to perform and generally carry a higher risk of complications including bleeding, nerve damage, and intravascular injection⁴. However, in experienced hands, they can be useful as they provide excellent anesthesia and intubating conditions⁴. For complete upper airway anesthesia, a bilateral glossopharyngeal nerve (GPN) block, bilateral superior laryngeal nerve (SLN) block and translaryngeal injection are required. The aim of this article is to demonstrate techniques of the above-mentioned blocks and potential complications associated with their anatomical location.

Correspondence to: *Assoc. Prof. Tatjana Stopar Pintarič, MD, PhD, DEAA*, Clinical Department of Anaesthesiology and Intensive Therapy, University Medical Centre Ljubljana, Zaloška 7, 1000 Ljubljana, Slovenia
E-mail: tatjanas38@gmail.com

Received February 27, 2015, accepted October 28, 2015

Glossopharyngeal Nerve Block

The GPN, as it exits from the jugular foramen, is located posteromedially to the styloid process and the styloid muscle group, from where it descends along the posterior side of the stylopharyngeal muscle, innervates this muscle and finally passes anteriorly to branch at the level of the middle constrictor muscle⁵ (Fig. 1). It provides sensory innervation to the posterior third of the tongue, the vallecula, the anterior surface of the epiglottis, the wall of the pharynx, and the tonsils⁶. It can be anesthetized by either intraoral or extraoral peristyloid approaches. For intraoral approach, the patient must have enough mouth opening ability for visualization of the base of the posterior tonsillar pillar. In addition, adequate topical anesthesia must be provided to that area for easier patient cooperation. This block is performed with 5 mL of local anesthetic using a 22- or 25-gauge spinal needle after the patient's tongue is displaced in the anteroinferior direction⁴. Unfortunately, this technique is understandably unpopular in the anesthesia practice since it is associated with lasting oropharyngeal discomfort⁷. Intraoral approach can, moreover, be used for the treatment of neuralgia⁸, for abolishing exaggerated gag reflex during various intraoral surgical procedures

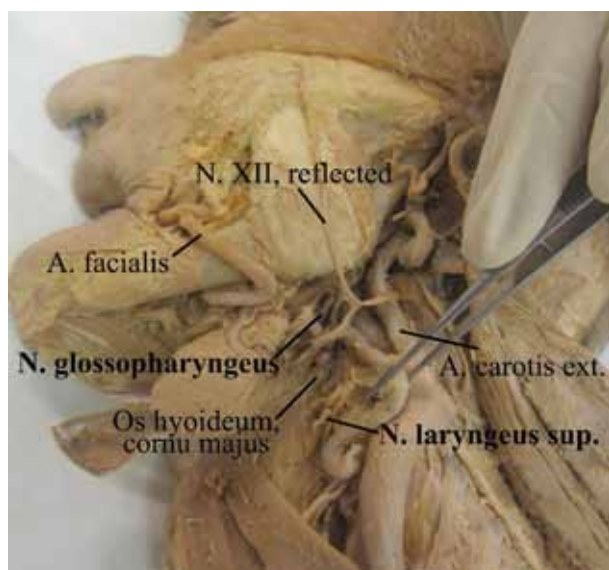


Fig. 1. Dissection of the left side of the neck revealing the glossopharyngeal nerve (*N. glossopharyngeus*) and superior laryngeal nerve (*N. laryngeus sup.*).

or endodontics⁹, or managing postoperative pain after tonsillectomy in adults and children¹⁰. Peristyloid approach, on the other hand, is associated with an increased risk of upper airway obstruction, related to the concomitant block of the hypoglossal nerve and the vagal nerve, proximal to the origin of the recurrent laryngeal nerve¹¹. Singh *et al.*, who used an extraoral peristyloid approach with the landmark technique for the treatment of glossopharyngeal neuralgia, needed to introduce a needle 3.5–4.5 cm deep to touch the styloid process and inject the drug behind it. In spite of using fluoroscopy, the styloid process was very difficult to locate due to its small width. In that study, no cardiac adverse events like dysrhythmia, bradycardia, hypotension, asystole and syncope were described. However, in a few of their cases, a simultaneous block of the vagal nerve was observed with hoarseness and swallowing difficulty, wearing off several hours later¹². Thus, bilateral peristyloid GPN blocks present a logical and unacceptable risk due to its intimately close proximity to the vagal nerve. Ultrasonography (US), which provides *in vivo* anatomy visualization, might nevertheless prove useful as it has already been successfully used to assist the performance of GPN block for the treatment of chronic pain at this level^{13,14}.

Superior Laryngeal Nerve Block

The superior laryngeal nerve slants forward to the greater horn of the hyoid bone before dividing into an internal and an external branch (Fig. 2). The former enters the thyrohyoid membrane through a foramen and provides visceral sensory and secretomotor innervation to the larynx above the true cords, whereas the latter descends along the outside of the thyrohyoid membrane beneath the sternothyroid muscle to the cricothyroid muscle, which it supplies with motor fibers⁴. A block of the internal branch of the superior laryngeal nerve (iSLN) provides anesthesia to the base of the tongue, posterior surface of the epiglottis, aryepiglottic folds and arytenoids¹⁵, and abolishes the glottis closure reflex. Thus far, various techniques have been suggested. The standard 'blind' landmark approach uses the close anatomical relation of the iSLN to the greater horn of the hyoid bone and the thyrohyoid membrane and requires some degree of neck extension, access to the anterior and lateral

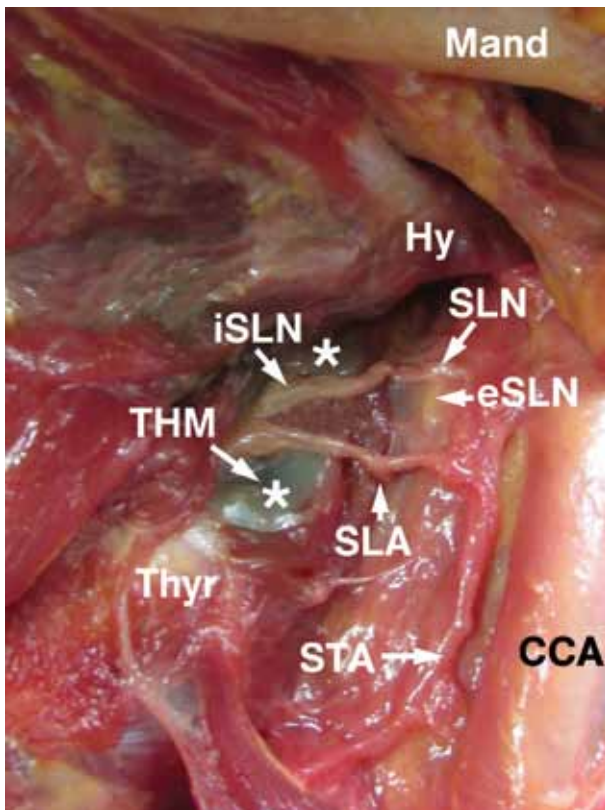


Fig. 2. Dissection of the left side of the neck showing the division of the superior laryngeal nerve (SLN) into external (eSLN) and internal branch (iSLN) which penetrates the thyrohyoid membrane (THM). Mand: mandible; Hy: hyoid bone, greater horn; Thyr: thyroid cartilage; CCA: common carotid artery; STA: superior thyroid artery; SLA: superior laryngeal artery.

neck, and the ability to identify the aforementioned structures^{4,16}. Nevertheless, it carries the risk of vessel puncture with hematoma formation or local anesthetic toxicity¹⁷. The SLN block is performed in a supine patient with the hyoid bone firmly displaced towards the side to be blocked. The short needle is then advanced just below its great horn, 1-2 cm deep into the thyrohyoid membrane, after which 2-4 mL of 1%-2% lidocaine is injected¹⁶.

Ultrasonography (US) has already been applied in assisting the performance of iSLN block, however, yielding conflicting results. Barberet *et al.*, for instance, describe a 'SLN space' as an anatomical basis for echo-guided SLN block after being unable to identify the SLN in 100 volunteers using a 12 MHz

linear probe¹⁸. They could not exclude the nerve being present in the SLN space, defined by them to be located between the hyoid bone superiorly, thyroid cartilage inferiorly, thyrohyoid muscle anteriorly and thyrohyoid membrane posteriorly – the structures optimally visualized in 81% of their scans. Iida *et al.* demonstrated clinical usefulness of a similar approach by injecting lidocaine at the surface of the greater horn of the hyoid bone, using an US-guided in-plane technique in a patient with laryngeal abscess¹⁹. Stopar Pintarič *et al.*, furthermore, suggested to use thyrohyoid membrane as a target plane for local anesthetic injection to make the US-guided iSLN block feasible²⁰. Nevertheless, there are investigators who report being able to consistently visualize the SLN with US. Manikandan *et al.*, for instance, located the nerve by identifying pulsation of the superior laryngeal artery (SLA) below the greater horn of the hyoid bone²¹, while Kaur *et al.* visualized the nerve by using a small hockey stick-shaped 8-15 MHz transducer²².

Translaryngeal Block

Translaryngeal block is a method of topical application of local anesthetic to the trachea and larynx, where sensory innervation is provided by the recurrent laryngeal nerve. Since it is invasive and potentially risky, it is grouped with the nerve blocks. The block provides anesthesia to the infraglottic larynx and the upper trachea immediately following injection and is used to prevent the cough reflex.

For cricothyroid membrane identification between the thyroid and the cricoid cartilages, the patient is placed in supine position with the neck extended. After a skin wheal, the needle is advanced nearly perpendicularly to the skin. After air aspiration, 3-5 mL of 2% lidocaine is injected into the airway⁴.

The difficulty of identifying landmarks can preclude the success of the block and awake intubation in patients with challenging airways²³. Using transverse scan at the level of the thyroid and cricoid cartilages can help identify the cricothyroid membrane. The thyroid cartilage had a hypo echoic inverted V-shape appearance, while the cricoid cartilage had a hypo echoic arch-like appearance. Using US, potential complications of blind puncture can be avoided such as bleeding and hematoma formation that can lead to airway obstruction²⁴.

Conclusions

Superior laryngeal nerve block and translaryngeal injection can be performed easily, safely and with a high success rate in patients with normal anatomy. In those with difficult landmarks, the ultrasound can be of assistance. For the superior laryngeal nerve block, other targets than the nerve itself must be established in order to make the technique consistently successful, easy to teach, learn and perform. The same applies to translaryngeal injection, where the use of US is necessary for correct midline identification in order to reduce the chance of puncturing the surrounding vessels, which could bring about subsequent complications. Intraoral glossopharyngeal nerve block is safe and easy to perform, but associated with long lasting discomfort. Bilateral extraoral peristyloid approach should be discouraged since inadvertent blocks of the closely adjacent vagus nerves cannot be prevented. A safe and easy method of blocking the more distal portions of the GPN for the purpose of awake intubation is therefore required.

Acknowledgments

I would hereby like to acknowledge the work of Professor Erika Cvetko and technical assistance of Ivan Blažinovič, Friderik Štandel and Marko Slak.

References

- Novak-Jankovič V. Management of the difficult airway. *Acta Clin Croat.* 2012;51(3):505-10.
- Giordano D, Panini A, Pernice C, Raso MG, Barbieri V. Neurologic toxicity of lidocaine during awake intubation in patient with tongue base abscess. Case report. *Am J Otolaryngol.* 2014;35(1):62-5. doi: 10.1016/j.amjoto.2013.08.009.
- Mcguire G, El-Beheiri H. Complete upper airway obstruction during awake fiberoptic intubation in patients with unstable cervical spine fractures. *Can J Anesth.* 1999;46:176-8.
- Simmons ST, Schleich AR. Airway regional anesthesia for awake fiberoptic intubation. *Reg Anesth Pain Med.* 2002;27:180-92.
- Faik OM, Ugur T, Memet OM, Necmett PM. Anatomic landmarks of the glossopharyngeal nerve: a microsurgical anatomic study. *Neurosurgery.* 2003;52(6):1400-10.
- Trivedi V, Sharma G. Evaluation of airway blocks versus general anaesthesia for diagnostic direct laryngoscopy and biopsy for carcinoma larynx. *J Indian Med Assoc.* 2012;110:78-83.
- Sitzman BT, Rich GF, Rockwell JJ, Leisure GS, Durieux ME, DiFazio CA. Local anesthetic administration for direct laryngoscopy. Are glossopharyngeal blocks superior? *Anesthesiology.* 1997;86(1):34-40.
- Mikula I. Craniofacial neuralgias. *Acta Med Croat.* 2008;62:163-72.
- Garg R, Singhal A, Agrawal K, Agrawal N. Managing endodontic patients with severe gag reflex by glossopharyngeal nerve block techniques. *J Endod.* 2014;40:1498-500. doi: 10.1016/j.joen.2014.01.028.
- Orntoft S, Løngreen A, Møiniche S, Dhal JB. A comparison of pre- and postoperative tonsillar infiltration with bupivacaine on pain after tonsillectomy. *Anaesthesia.* 1994;94:151-4.
- Bean-Lijewski JD. Glossopharyngeal nerve block for pain relief after pediatric tonsillectomy: retrospective analysis and two cases of life threatening upper airway obstruction from an interrupted trail. *Anesth Analg.* 1997;84:1232-8.
- Singh PM, Dehran M, Mohan V, Trikha A, Kaur M. Analgesic efficacy and safety of medical therapy alone *vs* combined medical therapy and extraoral glossopharyngeal nerve block in glossopharyngeal neuralgia. *Pain Med.* 2013;14:93-102. doi: 10.1111/pme.12001.
- Waldman SD. Styloid process injection. In: *Atlas of Pain Management Injection Techniques.* 3rd ed. Philadelphia, PA: Saunders Elsevier; 2013. p. 29-32.
- Bedder MD, Lindsey D. Glossopharyngeal nerve block using ultrasound guidance: a case report of a new technique. *Reg Anesth.* 1989;14(6):304-7.
- Stockwell M, Lozanoff S, Lang SA, Nyssen J. Superior laryngeal nerve block: an anatomical study. *Clin Anat.* 1995;8:89-95.
- Vannier JL, Vilett M, Bouaziz H, Ibrahim H, Marty J, Desmons JM. Block of the superior laryngeal nerve for ORL endoscopy. Description of a simplified technique. *Ann Fr Anesth Reanim.* 1989;8:379-81.
- Hsu CH, Lin TC, Yeh CC, Ho ST, Wong CS. Convulsions during superior laryngeal nerve block – a case report. *Acta Anaesthesiol Sin.* 2000;38:93-6.
- Barberet G, Henry Y, Tatu L, Berthier F, Besch G, Pili-Floury S, *et al.* Ultrasound description of a superior laryngeal nerve space as an anatomical basis for echo-guided regional anaesthesia. *Br J Anaesth.* 2012;109:126-8. doi: 10.1093/bja/aes203.
- Iida T, Suzuki A, Kunisawa T, Iwasaki H. Ultrasound-guided superior laryngeal nerve block and translaryngeal block for awake tracheal intubation in a patient with laryngeal abscess. *J Anesth.* 2013;27:309-10. doi: 10.1007/s00540-012-1492-5.
- Stopar Pintaric T, Vlassakov K, Azman J, Cvetko E. The thyrohyoid membrane as a target for ultrasound-guided block of the internal branch of the superior laryngeal nerve. *J Clin Anesth.* 2015;27(7):548-52. doi: 10.1016/j.jclinane.2015.07.016.
- Manikandan S, Neema PK, Rathod RC. Ultrasound-guided bilateral superior laryngeal nerve block to aid awake endotracheal intubation in a patient with cervical spine disease for emergency surgery. *Anaesth Intensive Care.* 2010;38:946-8.

22. Kaur B, Tang R, Sawaka A, Krebs C, Vaghadia H. A method for ultrasonographic visualization and injection of the superior laryngeal nerve: volunteer study and cadaver simulation. *Anesth Analg*. 2012;115:1242-5. doi: 10.1213/ANE.0b013e318265f75d.
23. Kristensen MS. Ultrasonography in the management of the airway. *Acta Anaesthesiol Scand*. 2011;55:1155-73. doi: 10.1111/j.1399-6576.2011.02518.x.
24. De Oliveira GS Jr, Fitzgerald P, Kendall M. Ultrasound-assisted translaryngeal block for awake fiberoptic intubation. *Can J Anesth*. 2011;58:664-5. doi: 10.1007/s12630-011-9501-y.

Sažetak

BLOKADA GORNJIH DIŠNIH PUTOVA U ZBRINJAVANJU OTEŽANOG DIŠNOG PUTA U BUDNOM STANJU

T. Stopar Pintarič

Za intubaciju u budnom stanju potrebna je dobra anestezija gornjeg dišnog puta koju se može postići topičnom anestezijom ili regionalnim blokadama. Blokovi su tehnički zahtjevniji i povezani su s mogućim ozbiljnim komplikacijama, ali u rukama stručnjaka omogućavaju dobru anesteziju i odlične uvjete za intubaciju u budnom stanju. Za kompletnu anesteziju gornjeg dišnog puta potrebna je obostrana blokada glosofaringealnog živca, unutarnjih grana gornjeg laringealnog živca i translaringealna blokada. Blokade gornjeg laringealnog živca i translaringealna injekcija su jednostavne, sigurne i uspješne kod većine bolesnika s normalnom anatomijom. U primjeru teške identifikacije anatomskih točaka može poslužiti ultrazvuk. Kod ultrazvučno vođene blokade gornjeg laringealnog živca potrebno je pronaći druge ciljeve od vizualizacije samog živca, jer je ta tehnika slabo reproducibilna, teška za učenje i izvođenje. U primjeru translaringealne blokade ultrazvuk može poslužiti za točnu identifikaciju medijalne linije. Intraoralni pristup blokadi glosofaringealnog živca jednostavan je za izvođenje i dosta siguran, ali zna nanositi neugodnu bol. Obostrani vanjski, peristiloidni pristup se apsolutno ne preporuča zbog blizine vagalnog živca i posljedične opstrukcije dišnoga puta. Iz toga slijedi da je za namjeru opskrbe dišnoga puta u budnom stanju potrebno pronaći jednostavniju metodu za blokadu glosofaringealnog živca koja će biti locirana na njegovom distalnom dijelu.

Ključne riječi: *Dišni put, opstrukcija; Dišni put, zbrinjavanje; Respiracijski sustav – ultrazvuk; Anestezija, lokalna; Živci, blokada; Budnost; Blokada glosofaringealnog živca; Blokada gornjeg laringealnog živca; Translaringealna blokada*