

## **Pug-headedness in the farmed triploid Atlantic cod, *Gadus morhua* Linnaeus, 1758 (Actinopterygii: Gadiformes: Gadidae) in Norway**

Laith JAWAD<sup>1\*</sup>, Anders THORSEN<sup>2</sup>, Håkon OTTERÅ<sup>2</sup> and Per FJELLDAL<sup>2</sup>

<sup>1</sup> Flat Bush, Manukau, Auckland, New Zealand

<sup>2</sup> Institute of Marine Research (IMR), Bergen, Norway

<sup>3</sup> Institute of Marine Research (IMR), Matre Research Station, Matredal, Norway

\*Correspondence: laith\_jawad@hotmail.com

---

*A farmed triploid pug-headed specimen of the Atlantic cod, *Gadus morhua* measuring 501 mm TL was obtained from IMR Parisvatn Field Station, Norway. The abnormal specimen had the following aberrant characters: short neurocranium and upper jaw, very short snout in comparison with the normal specimens, and asymmetrical upper and lower jaws. The right side of the head and the pre-maxilla were deformed, twisted downward and forward. The lower jaw was slightly distorted to the left. Causes for such aberrations are discussed.*

---

**Key words:** jaw malformation, Norway, cage aquaculture, osteology, Atlantic cod, pug-headedness

### **INTRODUCTION**

In 1860, Charles Darwin encouraged Jeffries Wyman to write a short paper describing the morphology of the head in Nāta Cattle (*Niata oxen*) and an abnormal Atlantic cod, *Gadus morhua* (DUPRE, 1951). Wyman came across the abnormal cod during an excursion to Labrador; it was an abnormal Atlantic cod (*Gadus morhua*) with arrested development of the upper jaw, which was sufficiently common to be known among fishermen as the ‘bull dog cod’. Wyman did not publish on this topic, but Darwin sited the information given by Wyman in “The Variation of Animals and Plants under domestication” (DARWIN, 1868). In Norway, where Atlantic cod supports important fisheries, this type of malformed cod has been known for centuries (LIL-

IESKIOLD, 1701). It is called ‘kongetorsk’ (king cod), because the forehead looks like a crown. It was believed that king cod led the cod during spawning migrations.

In both hatchery-raised and wild fish population, different levels of developmental anomalies have been observed. In his bibliographies, DAWSON (1964, 1966, 1971) compiled extensive lists of reported abnormalities in a large number of fish species, including the anomalous condition known as pug-headedness (MANUSUETI, 1960; DAWSON, 1964, 1966, 1971; WARLEN, 1969; DAWSON & HEAL, 1971; NAKAMURA, 1977; SHAR- IFF *et al.*, 1986; AL-HASSAN & NA’AMA, 1988; JAWAD & HOSIE, 2007; JAWAD *et al.*, 2014). Pug-headedness is usually associated with malformed bones of the head and in particular those of the upper jaw which is invariably shorter than the lower

jaw. The history of this anomaly dates back 1553 when the French naturalist Pierre Belon (in GUDGER, 1930) published the first figure of a pug-headed female salmonid. However, BUCKLAND (1877) is considered to have published the earliest account of pug-headedness in salmonids. Since then, over 120 published works have reported on this abnormal condition in different species of fish, mostly from Europe and North America (DAWSON, 1964, 1966, 1971; DAWSON & HEAL, 1971). The present study provides the first detailed morphological and radiographic description of pug-headedness in Atlantic cod, *Gadus morhua* is reported from Norway.

## MATERIAL AND METHODS

### Fish stock and rearing conditions

The cod brood stock was stripped for eggs and milt on the 14 and 15 March 2012 at IMR Parisvatn Field Station. The experiment was a part of a project on sexual maturation in Atlantic cod, and was approved by the Norwegian Animal Authority. The brood stock were obtained from a cage containing approximately 200 individual cod, which were born in captivity during spring 2008. Only individuals that easily released eggs and milt were used for the experiment. Batches of presumably low quality (milt, and overripe eggs) were discarded. Fertilization took place within 2 hours of stripping. The eggs and milt were kept in a 5.0 °C water bath until fertilization and the triploidization process. Five to ten ml of milt (a mixture of three milt batches from each day's stripping) was added to the unfertilized eggs (a mixture of 3-5 egg batches from each day's stripping) and carefully stirred. After one minute seawater was added to activate the eggs. On 30 March, 2012 the recently hatched larvae were transferred to three large plastic bags for larval and juvenile rearing. Approximately 60000 individuals were placed in each of the 45 m<sup>3</sup> volume bags that were floated in an enclosed seawater pond. The larvae were fed on natural zooplankton in the bags. They were later weaned on to a commercial dry feed (Gemma-series, followed by

Amber Neptun, Skretting, Norway), and eventually transferred to onshore tanks. During their period at the field station Parisvatnet, the larvae and juveniles were kept on ambient conditions. The temperature increased from approximately 5 ° at release into the bags to approximately 17 ° degrees during summer and subsequently down to about 8 ° during autumn. Salinity was between 32 and 35 ppt. On 17 October 2012, 300 fish were transported from IMR Parisvatnet Field Station to IMR Matre Research Station for further rearing, where the fish were kept in duplicate 1.5 m tanks until 14 February 2013, when the fish were transferred to one 5 m seawater tank. From 17 October 2012 onwards, the water temperature and salinity was stabilized at around 8.9 °C and 34 ppt respectively, and the fish were fed *ad libitum* with a commercial feed (Europa Marin S, Skretting AS, Norway) under a simulated natural photoperiod regime. On 07 May 2014, 100 fish were euthanized by administering an over-dose of anesthetics, measured, weighed sexed, and screened for externally detectable skeletal deformities.

## RESULTS

The dimensions of the 3 year old pug-headed female specimen were as follows: 501 mm total length, 465 mm standard length, 29 mm preorbital length and 46 mm postorbital length. This case of pug-headedness was an incidental finding and no other skeletal deformities recorded from the same specimen. The abnormal specimen was compared with ten normal specimens having similar body and head measurements. The pug-headed specimen exhibited the following aberrant features: neurocranium and the upper jaw shorter than lower jaw, very short snout in comparison with normal specimens, and asymmetrical upper and lower jaws (Fig. 1). The mouth was open and the premaxilla and maxilla were drooping down on the side of the mouth. On the right side of the head, the premaxilla was deformed, twisted downward and forward (Fig. 2). The left side of the premaxilla was normal. The lower jaw was slightly distorted to the left. The anterior nostril had moved

ventrally toward the mouth as a result of shortening of the snout.

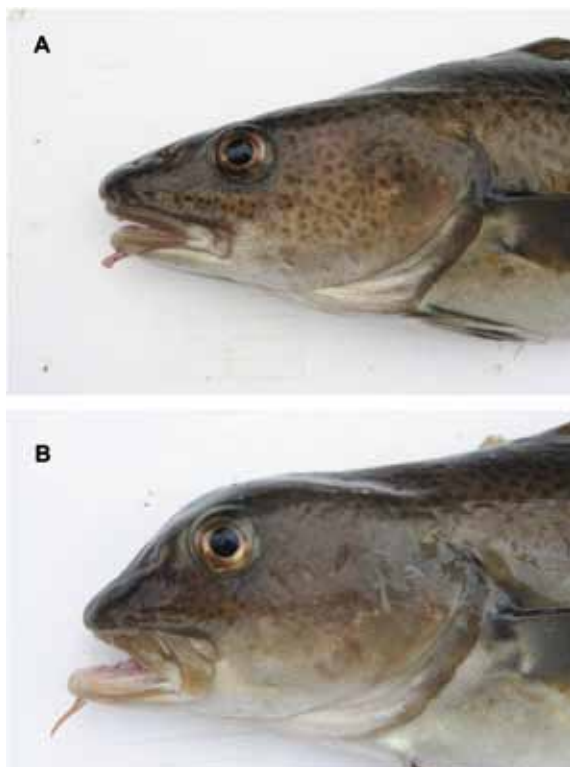


Fig. 1. *Gadus morhua* (a) normal specimen (468 mm TL); (b) abnormal specimen with pug-headedness (501 mm TL).



Fig. 2. Abnormal specimen of *Gadus morhua* 501 mm TL with pug-headedness showing right side of the head.

To evaluate the level of the damage in the skull of the abnormal pug-headed specimen, the osteological features were compared with those of normal specimens. Internally, the vomer, parasphenoid, and maxillaries were shortened, and displacement and/or curvature of the nasals,

frontals, vomer, and palatines were observed. Some of the teeth in the upper jaw were curved backward and others curved forward instead of being projected downward. For these reasons, the forehead was upraised and steep in the pug-headed specimen (Figs. 3, 4).

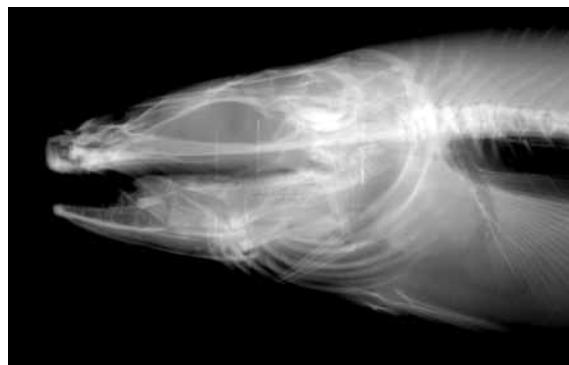

Fig. 3. X-ray of the right side of the head of normal specimen of *Gadus morhua*, 468 mm TL.

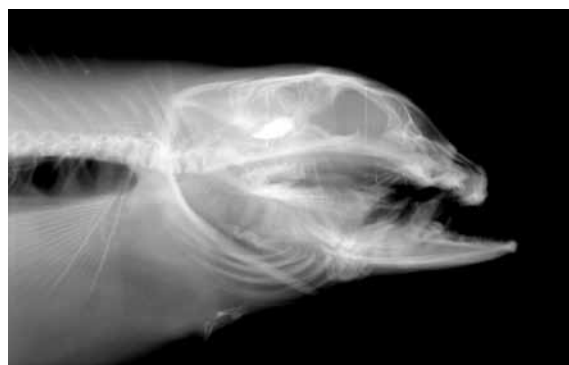

Fig. 4. X-ray of the left side of the head of abnormal specimen of *Gadus morhua*, 501 mm TL. With pug-headedness.

## DISCUSSION

HICKY *et al.* (1977) diagnosed four levels of pug-headedness in striped bass *Morone saxatilis*, including, normal, primary, secondary and tertiary. These stages fit all pug-headed cases previously reported in other teleost fishes. The present case of severe pug-headedness in Atlantic cod, represents the tertiary stage of HICKEY *et al.* (1977). It has been suggested that pug-headedness might hinder the ability of the affected fish to both breathe and feed (HICKEY, 1973) which in turn may reduce their ability to compete for food (BORTONE, 1972). However,

considering the fact that pug-headed Atlantic cod have been known among fishermen in both Canada and Norway for centuries suggests that wild pug-headed cod are able to survive and grow.

For example, FORD (1930) described a wild cod with a seriously deformed lower jaw which was 86.5 cm in length and had fairly good body condition.

The pug-headed cod in the present study clearly survived the period in the sea-cage and grew to a TL of 501 mm. Several causes have been suggested to explain the pug-headedness anomaly including genetic or epigenetic factors (DAHLBERG, 1970; SLOFF, 1982). During their developmental stages, fish larvae face many epigenetic defects especially in hatchery situations (SHARIFF *et al.*, 1986). Variations in water temperature, salinity, dissolved oxygen, diet, solar radiation, and chemical pollution can have epigenetic influences (TOFTEN & JOBLING, 1996; LEMLY, 1997; FURUITA *et al.*, 1998; CAHU *et al.*, 2003; PANEBIANCO *et al.*, 2010). On the other hand, genetic anomalies resulting from non-lethal

mutations or a recombination of genes may be heritable (BROWDER *et al.*, 1993). Although both parents of the abnormal *Gadus morhua* examined in the present study were morphologically normal, sexually mature and capable of spawning, it is possible that the single case of pug-headedness observed in one of their offspring might have been due to a heritable genetic defect (CHEW, 1973). A similar case of pug-headedness was recently observed and described in Atlantic salmon, *Salmo salar* by JAWAD *et al.* (2014).

## ACKNOWLEDGEMENTS

We wish to thank Britt SVÆREN DAAE at IMR for helping out with the radiology, and Karin Elisabeth BENGSSON at Bibliotek for Fiskeridirektoratet, NIFES og Havforsknings instituttet for helping with the older literature and to Declan QUIGLEY, Sea Fisheries Protection Authority, Dublin, Ireland for reading the manuscript and for his valuable advice and suggestions

## REFERENCES

- AL-HASSAN, L. A. J. & A.K. NA'AMA. 1988. A case of pugheadedness in the croaker, *Johnius aneus* from Khor al-Zubair, northwest of the Arabian Gulf, Iraq. *Indian Journal of Fisheries*, 35: 68–69.
- BENFEY, T. J. 2001. Use of sterile triploid Atlantic salmon (*Salmo salar* L.) for aquaculture in New Brunswick, Canada. *ICES Journal of Marine Science*, 58: 525–529.
- BORTONE, S. 1972. Pug-headedness in the pirate perch, *Aphredoderus sayanus* (Pisces: Aphredoderidae), with implications on feeding. *Chesapeake Science*, 13, 231–232.
- BROWDER, J., D. McCLELLAN, D. HARPER & W. KANDRASHOFF. 1993. A major developmental defect observed in several Biscayne Bay, Florida, fish species. *Environmental Biology of Fishes*, 37: 181–188.
- BUCKLAND, F. 1877. Snub-nosed Salmon. Reprinted from *Land and Water*. G. Carlet, 1879, "Sur une Truite Mopse." *Forest and Stream*, VIII, pp. 96.
- CAHU, C., J.L. ZAMBONINO & T. TAKEUCHI. 2003. Nutritional components affecting skeletal development in fish larvae. *Aquaculture*, 227: 245–258.
- CHEW, R. L. 1973. Pug-headedness in the Florida largemouth bass *Micropterus salmoides floridanus* (Lesueur). *Florida Science*, 36: 201–204.
- DAHLBERG, M. 1970. Frequencies of abnormalities in Georgia estuarine fishes. *Transaction of the American Fisheries Society*, 1: 95–97.
- DARWIN, C., 1868. *The Variation of Animals and Plants under Domestication*. Vol I. Cambridge University Press, U.K., 89 pp.
- DAWSON, C. 1964. A bibliography of anomalies of fishes. *Gulf Research Reports*, 1: 308–399.
- DAWSON, C. 1966. A bibliography of anomalies of fishes. *Gulf Research Reports*, 2 (Suppl. 1): 169–176.
- DAWSON, C. 1971. A bibliography of anomalies of fishes. *Gulf Research Reports*, 3: 215–239.

- DAWSON, C. & E. HEAL. 1971. A bibliography of anomalies of fishes. *Gulf Research Reports*, 5 (Suppl. 3): 35–41.
- DUPREE, A. H. 1951. Some letters from Charles Darwin to Jeffries Wyman. *Isis*, 42: 104–10.
- FORD, E. 1930. Some abnormal fishes received at the Plymouth Biological Laboratory. *Journal of the Marine Biological Association, U.K.*, 17: 53–64.
- FURUIT, H., T. TAKEUCHI & K. UEMATSU. 1998. Effects of eicosapentaenoic acids on growth, survival and brain development of larval Japanese flounder (*Paralichthys olivaceus*). *Aquaculture*, 161: 269–279.
- GUDGER, E. 1930. A pug-headedness in the striped bass, *Roccus lineatus*, and in related fishes. *Bulletin of Amsterdam Museum Natural History*, 61: 1–19.
- HICKEY, C. 1973. Common abnormalities of fishes, their causes and effects. *Transaction of the Northern Fish Wildlife conference*, 1972: 71–83.
- HICKEY, C., B. YOUNG & R. BISHOP. 1977. Skeletal abnormalities in striped bass. *New York Fish & Game Journal* 24: 69–85.
- JAWAD, L. A. & A. HOSIE 2007. On the record of pug-headedness in snapper, *Pagrus auratus* (Forster, 1801) (Perciformes, Sparidae) from New Zealand. *Acta Adriat.*, 48: 205–210.
- JAWAD, L.A., A.KOUSHA, F. SAMBRAUS, & P. FJELLDAL. 2014. On the record of pug-headedness in cultured Atlantic salmon, *Salmo salar* Linnaeus, 1758 (Salmoniformes, Salmonidae) from Norway. *J. of App. Ichth.*, 30: 537–539.
- LEMELY, D. A. 1997. A teratogenic deformity index for evaluating impacts of selenium on fish population. *Ecotoxicol. Environ. Saf.*, 37: 259–266.
- LILIENSKIOLD, H.H. 1701. *Speculum boreale*. Manuscript kept at the Royal Library, Copenhagen. Published in 1943–44 as «Lilienskiolds Speculum Boreale» O. Solberg (Editor). *Etnografisk Museum, Nordnorske Samlinger*, 4: 51–337.
- MANUSUETI, R. 1960. An unusually large pug headed striped bass, *Roccus saxatilis* from Chesapeake Bay, Maryland, USA. *Chesapeake Science*, 1: 111–113.
- NAKAMURA, I. 1977. A pug headed specimen found among a school of bluefin tuna, *Thynnus thynnus*. *Jpn. J. Ichthyol.*, 23: 204–205.
- PHROMKUNTHONG, W., M. BOONYARATPALIN & V. STORCH. 1997. Different concentrations of ascorbyl-2-monophosphate-magnesium as dietary sources of vitamin C for seabass, *Lates calcarifer*. *Aquaculture*, 151, 225–243.
- PANEBIANCO, A., A. LO PRESTI, F. GIARRATANA & G. DONATO. 2010. Characterization of skeletal deformities in reared *Sparus aurata*. *Inspective consideration. Rivista dell'Associazione Italiana Veterinari Igienisti*, 8: 59–63.
- SADLER, J., P.M. PNKHURST & H.R. KING 2001. High prevalence of skeletal deformity and reduced gill surface area in triploid Atlantic salmon (*Salmo salar* L.). *Aquaculture*, 198: 369–386.
- SHARIFF, M., A.T. ZAINUDDIN & H. ABDULLAH. 1986. Pug-headedness in bighead carp, *Aristichthys nobilis* (Richardson). *J. Fish Dis.*, 9: 457–460.
- SLOFF, W. 1982. Skeletal anomalies in fish from polluted surface waters. *Aquatic Toxicology*, 2: 157–173.
- SUTTERLIN, A. M., J. HOLDER & T.J. BENFEY. 1987. Early survival rates and subsequent morphological abnormalities in landlocked, anadromous and hybrid (landlocked x anadromous) diploid and triploid Atlantic salmon. *Aquaculture*, 64: 157–164.
- TOFTEN, H. & M. JOBLING. 1996. Development of spinal deformities in Atlantic salmon and Arctic char fed diets supplemented with oxitetracycline. *J. Fish Biol.*, 49: 668–677
- WALL, A. E. & R. H. RICHARDS. 1992. Occurrence of cataracts in triploid Atlantic salmon (*Salmo salar*) on four farms in Scotland. *Veterinary Records*, 131: 553–557.
- WARLEN, S. M. 1969. Additional records of pug headed Atlantic menhaden, *Brevoortia tyrannus*. *Chesapeake Science* 10: 67–68.

Received: 13 April 2015

Accepted: 31 August 2015

**Deformacije glave uzgojenog triploidnog bakalara,  
*Gadus morhua* Linnaeus, 1758  
(Actinopterygii: Gadiformes: Gadidae) u Norveškoj**

Laith JAWAD<sup>1\*</sup>, Anders THORSEN<sup>2</sup>, Håkon OTTERÅ<sup>2</sup> i Per FJELLDAL<sup>2</sup>

<sup>1</sup> Flat Bush, Manukau, Auckland, Novi Zeland

<sup>2</sup> Institut za istraživanje mora (IMR), Bergen, Norveška

<sup>3</sup> Institut za istraživanje mora (IMR), Matre Research Station, Matredal, Norveška

\*Kontakt adresa, e-mail: laith\_jawad@hotmail.com

**SAŽETAK**

Uzgojeni triploidni primjerak bakalara, *Gadus morhua*, s deformacijom glave, ukupne duljine 501 mm je ulovljen u blizini Instituta za istraživanje mora kod Parisvatn terenske postaje u Norveškoj. Abnormalni primjerak je imao sljedeće neprirodne znakove: kratki neurokranij (koštani pokrov mozga), i gornja čeljust, vrlo kratka gubica u usporedbi s normalnim primjercima, te asimetrična gornja i donja čeljust. Desna strana glave i gornja vilica (premaxilla) su deformirani, izvrnute su prema dolje i naprijed. Donja vilica je blago iskrivljena ulijevo. U radu se raspravlja o uzrocima takvih odstupanja.

**Ključne riječi:** malformacije čeljusti, akvakultura, osteologija, bakalar, deformacije glave, Norveška