

Reconstruction of Large Facial Defects after Delayed Mohs Surgery for Skin Cancer

Uwe Wollina

Department of Dermatology and Allergology, Dresden-Friedrichstadt Academic Teaching Hospital, Dresden, Germany

Corresponding author:

Prof. Uwe Wollina, MD
Department of Dermatology and Allergology
Dresden-Friedrichstadt Academic Teaching Hospital
Friedrichstrasse 41
01067 Dresden
Germany
wollina-uw@khdf.de

Received: January 17, 2015

Accepted: October 29, 2015

ABSTRACT The face is a common localization for skin malignancies. Mohs surgery or delayed Mohs surgery are considered the gold standard of treatment despite new drug developments.

We analyzed our patient files over a three-year period. Only large facial defects ≥ 3 cm in diameter after complete tumor removal were considered. Twenty patients (9 men and 11 women) were found, with a mean age of 83.6 years. The following tumor entities were responsible for large defects: basal and squamous cell carcinoma, melanoma, Merkel cell carcinoma, atypical fibroxanthoma, and cutaneous angiosarcoma. Surgery was performed in all cases using regional or local anesthesia. Defect repair was done using linear sutures (n=1), skin grafts (n=1), and flaps (n=18). The various types of repair are illustrated in this review, advantages and limitations of each type of repair are discussed. Patient satisfaction was high. Complications or adverse events were rare. The need for repair of large facial defects after tumor surgery is not uncommon. Careful planning and the use of a number of techniques allows a tailored approach for each patient.

KEY WORDS: skin cancer, facial localization, Mohs surgery, defect repair, skin flaps, skin grafts

INTRODUCTION

The face is a site of predilection for several skin tumors, such as lentigo maligna melanoma (LMM), squamous cell carcinoma (SCC), basal cell carcinoma (BCC), and Merkel cell carcinoma (MCC). Despite new and emerging medical drugs providing pharmacological opportunities for treatment of advanced tumors, Mohs surgery or delayed Mohs surgery remains the gold standard of current treatment (1).

Reconstruction of facial defects after tumor removal warrants a high standard of functional and aesthetic repair (2). Surgical repair relies on detailed knowledge and understanding of facial anatomy. In

many cases, defect closure following facial tumor surgery is possible through the use of linear sutures. In case of larger facial defects, the potential of more complex flaps offers additional opportunities for defect repair by transposition, rotation, advancement, or a combination of those. Flap viability is dependent on vascular supply. In this review, we will focus on random flaps. These flaps are particularly useful for facial repair and receive vascular supply from the subdermal plexus or musculocutaneous or septocutaneous perforators located at the base of the flap (3).



Local flaps offer a number of advantages such as similar color and texture, good survival rates, and no scar contracture, leading to good aesthetic results. Viscoelastic properties of the skin may be negatively influenced by age, internal disease and medications, and ultraviolet light exposure.

Since the majority of these patients are older and with multiple comorbidities, careful planning of the procedures is particularly important.

We describe various robust techniques for the closure of large facial defects after Mohs surgery, evaluated over a three-year interval at our Department.

PATIENTS AND METHODS

We investigated patients treated surgically for facial skin tumors between August 10th, 2009 and August 10th, 2013. Our preferred technique for the region was delayed Mohs surgery with local or regional anesthesia. From these cases we selected those patients who had a large skin defect after the Mohs surgery, i.e. defects ≥ 3 cm in diameter. Patients with metastatic spread were not considered. The various approaches for defect closure are discussed. Follow-up was between 8 and 24 months (mean 11.3 ± 6.7 months).

RESULTS AND DISCUSSION

A total of 20 suitable patients were identified. The ratio of men to women was 9:11. The average age of the patients was 83.6 ± 8.9 years (mean \pm standard deviation; SD). All of these patients had at least one comorbidity. The most common comorbidities were cardiac disease and/or hypertension (n=17), diabetes mellitus (n=13), renal insufficiency (n=5), and chronic pulmonary disorders (n=5).

The following tumor entities were observed: BCC, SCC, LMM, MCC, nodular malignant melanoma (NMM), cutaneous angiosarcoma, and atypical fibroxanthoma (AFX). Table 1 provides an overview of demographic data and tumor entities leading to large facial defects.

Various technical approaches had been used for defect closure: local flaps, grafts, and combinations of different techniques. During repair using skin flaps there is an additional loss of tissue from the removal of Burow's triangles. This can be described by the term "tissue efficiency", i.e. the ratio between the area of the defect and the defect plus lost tissue from Burow's triangles. The island pedicle flap and rhomboid flap show the highest tissue efficiency (4).

Table 1. Tumor entities leading to large facial skin defects

Age	Sex	Tumor	Area	Stage	Flaps or grafts
75	F	MCC	Temple	pT2c	Cheek & transposition flap
83	F	LMM	Cheek	pT1a	Cheek flap
87	F	MCC	Cheek	pT1c	Cheek flap and full thickness skin transplant
74	M	BCC	Temple	pT2c	Rhomboid flap
91	M	BCC	Cheek	pT2c	Cheek flap
80	M	Angiosarcoma	Cheek	pT2b	Banner transposition flap
99	F	SCC	Temple	pT1bG2	Lateral advancement flap
73	F	BCC	Cheek	pT2c	Cheek flap
90	F	LMM	Cheek	pT1a	Cheek flap
80	M	LMM	Cheek	pT2a	Cheek flap
77	F	BCC	Temple	pT2c	Rhomboid flap
68	M	SCC	Forehead	pT1bG2	Rhomboid flap
94	F	SCC	Cheek	pT1cG2	Cheek flap
96	M	SCC	Temple	pT2cG2	Full thickness skin graft
89	F	NMM	Cheek	pT4a	Advancement flap
87	M	BCC	Temple	pT2b	Rotational flap
76	F	NMM	Forehead	pT3b	Rotational flap
93	F	BCC	Forehead	pT4b	Full thickness skin graft
77	M	AFX	Temple	-	Kite flap

*LMM: lentigo maligna melanoma, SSC: squamous cell carcinoma, BCC: basal cell carcinoma, MCC: Merkel cell carcinoma, NMM: nodular malignant melanoma, AFX: atypical fibroxanthoma

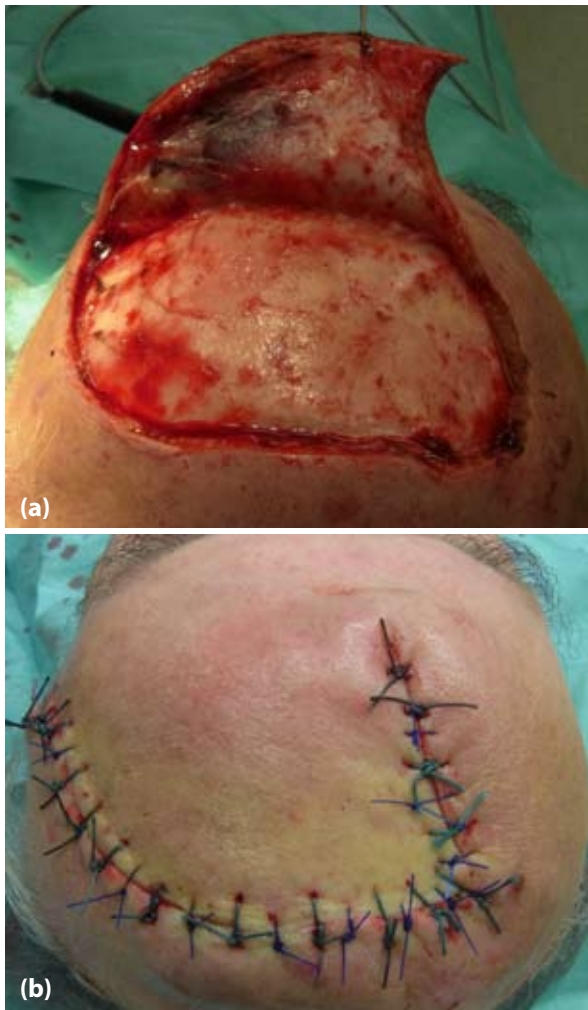


Figure 1. Large squamous cell carcinoma (SCC). (a) Worthen flap for forehead SCC. Venter frontalis muscle fascia exposed. (b) Tension-free wound closure.

Since the repair technique is dependent on the anatomical localization, we will discuss possible methods for different localizations. We start with the forehead:

If the defect is located in a more lateral on the forehead, the rhomboid flap is an easy, functional, and aesthetic solution (Figure 1, a, b). Larger defects can be closed with a Worthen rotational flap (Figure 1, c, d) (5). For medial defect closure of >3 cm in diameter, bilateral H advancement flaps provide an approach that leaves the brow line untouched. Small Burow's triangles are excised along the longer edge to circumvent standing cone deformities.

For the temporal region, rhomboid flaps are very useful. If the defect comes close to the orbital rim, there is a risk of lateral tension on the eyelids. Several modifications have been described in the surgical literature including the Limberg, Duformental,

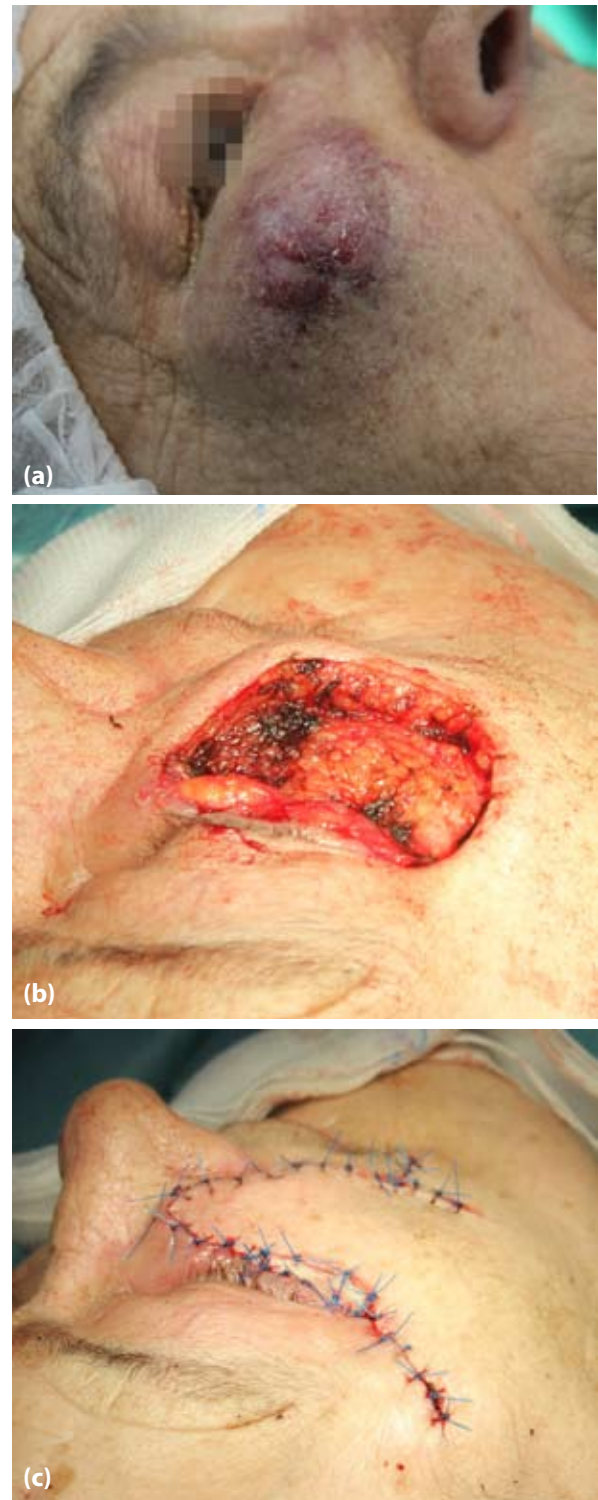


Figure 2. Locally advanced Merkel cell carcinoma (MCC). (a) Clinical presentation of an ill-defined large nodule. (b) Defect after complete tumor removal, exposing the medial fat pad. (c) After wound closure and lateral lower lid reconstruction by skin transplant obtained from the Burow triangle.

Webster, and diamond flap. These flaps are mainly differentiated by the rhomboid angles used. The diamond modification may circumvent the rare complication of partial flap necrosis since the acute corner is cut in the design of this flap (6). The kite flap with double-sided subcutaneous advancement flaps would be an alternative (7). Another option is the pre-auricular advancement flap mobilizing the skin of the temple and the lateral cheeks.

The cheeks represent the largest facial aesthetic subunit. Here, relaxed skin tension lines run parallel to rhytids. Cheek repair is based on the avoidance of undue tension and disfigurement. Advancement flaps may be a simple option for laterally localized defects of the cheeks, allowing linear wound closure (8). For medial cheek defects a V-Y-advancement flap or island pedicle flap is a useful option with acceptable scar formation (9). Cheek advancement flaps allow relatively simple and aesthetic defect repair for more medially localized cheek defects (Figure 2).

The preferred option for cheek repair in our study was the cheek rotational flap with various modifications. This type of flap allows closure of large defects a single step (Figure 3). The length of the arc should be approximately 4 times the diameter of the defect. A back-cut may be necessary. The ideal arc of closure should be <30 degrees. The flap has to be relatively thin to avoid stronger gravitational forces pulling it downwards, resulting in a negative impact on lower lid shape and the risk of ectropium. Subcutaneous suspensions anchoring the flap in the cheek bone region can reduce the likelihood of this possible complication.

Another option is the reading man flap designed for periocular and malar defects of a size up to 4 cm in diameter. Extra skin relaxation is gained by an unequivocal Z-plasty maneuver in favor of defect closure. It results in acceptable scars (10).

Sometimes tumors and the necessary safety margins cross aesthetic units of the face. In such situations a combination of flaps, e.g. the rhomboid flap and its modifications for the temple combined with the rotational cheek flap, is necessary for a good functional and aesthetic outcome (Figure 3). Another common combination consists of flaps and grafts.

Skin grafts are an option for very large defects or in cases of a poor tissue quality disallowing skin flaps. Full thickness skin grafts provide a good functional result on the forehead and temple. Aesthetic outcomes are rated lower compared to flaps. For deep facial defects after tumor surgery, a combination of dermal templates and (split thickness) skin grafts is an additional option with acceptable aesthetic outcome (11).

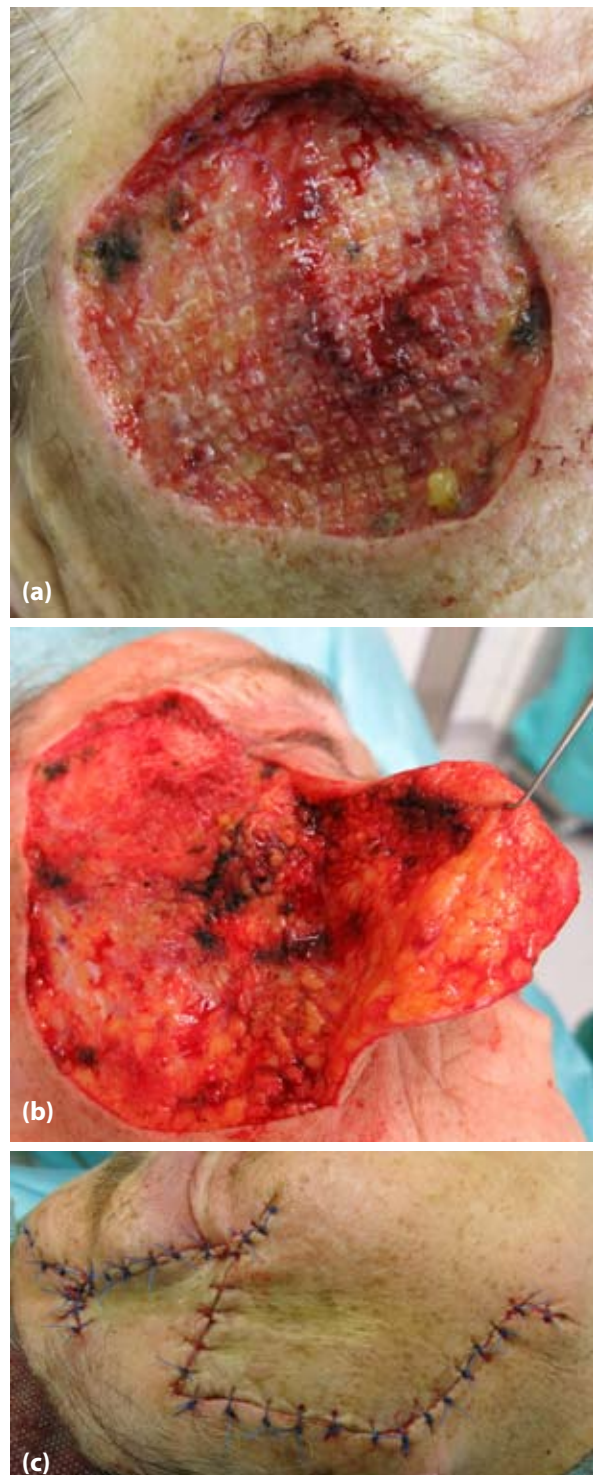


Figure 3. (a) Defect after delayed Mohs surgery for Merkel cell carcinoma (MCC) with the lateral orbital fat pad. (b) Preparation of a cheek advancement flap exposing the middle and medial fat pad. (c) Final closure by combined cheek advancement and rhomboid flap from the temple.

Patients scored their satisfaction with aesthetic and functional outcome as good or better in 18 of 20 cases. Complications and adverse effects presented in a minority of patients: minor bleeding due to anticoagulation (n=3) and lateral lower lid ectropium (n=1). The ectropium was treated by lateral canthopexy. We observed two minor hematomas in patients with oral anticoagulation, but no flap failure. We recommended that smokers stop smoking, although a recent study questioned this recommendation (12).

Although the techniques presented herein did not affect cervical lymph nodes, milder post-surgical edema is not uncommon. Physical therapy as an adjunct to surgery helps reduce pain, fibrosis, and edema and supports rehabilitation of cancer patients (13). Therefore, we pursue an interdisciplinary approach – surgical and physical – in our Department.

CONCLUSION

Surgical repair of larger facial defects after tumor surgery relies on understanding anatomy, the properties of local flaps, and the creativity of the surgeon.

References:

1. Semkova K, Tchernev G, Wollina U. Skin cancer treatment options: new horizons and promises for the future. *Wiener Med Wochenschr* 2013;163:345-6.
2. Rohrer TE, Cook JL, Nguyen TH, Melette Jr JR. *Flaps and Grafts in Dermatologic Surgery*. Philadelphia/PA: Saunders Elsevier. 2007.
3. Prendergast PM. Anatomy of the face and neck. In: Shiffman MA, Di Guiseppe A (eds) *Cosmetic Surgery*. Berlin-Heidelberg: Springer-Verlag. 2012; pp. 29-45.
4. Worthen EF. Repair of forehead defects by rotation of local flaps. *Plast Reconstr Surg* 1976;57:204-6.
5. Barlow JO. The tissue efficiency of common reconstructive design and modification. *Dermatol Surg* 2009;35:613-28.
6. Tamborini F, Cherubino M, Scamoni S, Frigo C, Valdatta L. A modified rhomboid flap: the "diamond flap". *Dermatol Surg* 2012;38:1851-5.
7. Ducours JL, Richard D, Aftimos J, Wangermez A, Poizac P. The "kite" flap in the reconstruction after excision of a basal cell carcinoma of the face. Our experience with 45 cases [Article in French]. *Rev Stomatol Chir Maxillofac* 1989;90:345-8.
8. Rapstine ED, Knaus WJ 2nd, Thornton JF. Simplifying cheek reconstruction: a review of over 400 cases. *Plast Reconstr Surg* 2012;129:1291-9.
9. Raklyar E, Zloty DM. Use of a patient and observer scar assessment scale to evaluate the V-Y advancement flap for reconstruction of medial cheek defects. *Dermatol Surg* 2012;38:1968-74.
10. Seyhan T, Caglar B. "Reading man flap" design for reconstruction of circular infraorbital and malar skin defects. *Dermatol Surg* 2008;34:1536-43.
11. Wollina U. One-stage reconstruction of soft tissue defects with the sandwich technique: Collagen-elastin dermal template and skin grafts. *J Cutan Aesthet Surg* 2011;4:176-82.
12. Dixon AJ, Dixon MP, Dixon JB, Del Mar CB. Prospective study of skin surgery in smokers vs. nonsmokers. *Br J Dermatol* 2009;160:365-7.
13. Guru K, Manoor UK, Supe SS. A comprehensive review of head and neck cancer rehabilitation: physical therapy perspectives. *Indian J Palliat Care* 2012;18:87-97.

