

# TREATMENT OF MEDIAL MENISCUS INJURY WITH PARTIAL MENISCECTOMY

Žarko Dašić<sup>1</sup>, Nikola Bulatović<sup>1</sup>, Miroslav Kezunović<sup>1</sup>, Ivan Benčić<sup>2</sup> and Vesna Bokan<sup>3</sup>

<sup>1</sup>Clinical Department of Orthopedics and Traumatology, Clinical Center of Montenegro, Podgorica, Montenegro;

<sup>2</sup>Traumatology Hospital, Sestre milosrdnice University Hospital Center, Zagreb, Croatia; <sup>3</sup>Center for Physical and Rehabilitation Medicine, Clinical Center of Montenegro, Podgorica, Montenegro

**SUMMARY** – Partial meniscectomy involves partial removal of the meniscus. This can vary from minor trimming of the damaged part of the meniscus to the removal of the rip from the meniscocapsular junction. Meniscus tears are the most common knee injury. They may occur in acute knee injuries in younger patients, or as part of a degenerative process in older individuals. The aim of the study was to demonstrate the method of choice for treatment of medial meniscus injuries that, in well selected cases, resulted in a small rate of complications and fast rehabilitation. The study analyzed the results of arthroscopic partial medial meniscectomy in 99 patients, in the period from 2005 to 2013, with follow up of 12-14 months. In our series of arthroscopically treated medial meniscus, tears were found in 29 patients with vertical complete bucket handle lesions, 14 with vertical incomplete lesions, 9 with longitudinal tears, 13 with oblique tears, 11 with complex, flap and degenerative lesions, 10 with radial lesions and 13 with horizontal lesions. The mean preoperative International Knee Documentation Committee score was 52.52%, then 81.81% at one month and 92.92% at six months of arthroscopic partial medial meniscectomy. Arthroscopic partial medial meniscectomy is a minimally invasive diagnostic and therapeutic procedure. This procedure is an acceptable and effective long-term treatment, particularly in patients without significant articular cartilage damage, and is associated with minimal morbidity.

**Key words:** *Menisci, tibial – surgery; Menisci, tibial – injuries; Arthroscopy – methods*

## Introduction

The menisci of the knee have an important role in load-bearing and shock absorption within the joint. They may also function as secondary stabilizers, have a proprioceptive role, and aid the lubrication and nutrition of the articular cartilage. Biomechanical testing has shown that the medial and lateral menisci transmit at least 50% to 70% of the weight bearing load when the knee is extended and up to 85%-90% when the knee is flexed<sup>1</sup>.

The medial meniscus is a fibrocartilage semicircular band that spans the knee joint medially, located between the medial condyle of the femur and the medial condyle of the tibia. The majority of collagen (90%) is of type I, whereas types II, III, V and VI are present in much smaller amounts. Elastin accounts for approximately 0.6% and non-collagenous proteins for 8% to 13%. The cells of the meniscus are fibrochondrocytes (Fig. 1).

The meniscus attaches to the tibia *via* meniscotibial (coronary) ligaments. The greatest displacement of the meniscus is caused by external rotation, while internal rotation relaxes it<sup>2</sup>.

The medial, lateral and middle geniculate arteries, which branch off the popliteal artery, provide major vascularization to the inferior and superior aspects of

Correspondence to: Prof. Žarko Dašić, MD, PhD, Department of Orthopedics and Traumatology, Clinical Center of Montenegro, Ljubljanska bb, Podgorica, Montenegro  
E-mail: zarko.dasic@kccg.me

Received September 29, 2014, accepted August 17, 2015

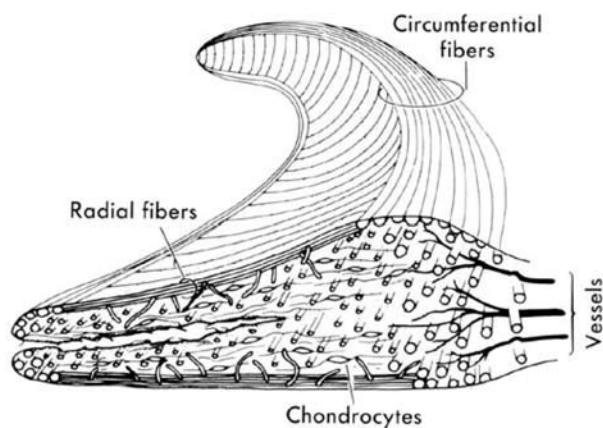


Fig. 1. Schematic presentation of the meniscal composite structure<sup>2</sup>.

each meniscus<sup>3</sup>. The premeniscal capillary network arising from branches of these arteries originates within the synovial and capsular tissues of the knee along the periphery of the menisci. Only 10% to 30% of the peripheral medial meniscus border and 10% to 25% of the lateral meniscus border receive direct blood supply<sup>3,4</sup>. Endoligamentous vessels from the anterior and posterior horns travel a short distance into the substance of the menisci and form terminal loops, providing another direct route for nourishment. The remaining portion of each meniscus (65% to 75%) receives nourishment only from the synovial fluid *via* diffusion<sup>2-4</sup>.

The knee joint is innervated by the posterior articular branch of the posterior tibial nerve and terminal branches of the obturator and femoral nerves. Ruffini, Pacinian and Golgi tendon mechanoreceptors have been identified in the knee joint capsule and in the peripheral menisci<sup>5,6</sup>.

The incidence of meniscal injury resulting in meniscectomy is 60/100 000 population *per year*<sup>7</sup>. This may occur in acute knee injuries in younger patients, or as part of a degenerative process in older individuals. Medial meniscal tears occur more frequently than tears of the lateral meniscus, at a ratio of approximately 2:1<sup>8</sup> (Fig. 2). Meniscal injuries can be classified by their appearance, location, shape, extent and origin.

The menisci themselves cannot be visualized on plain radiographs. Magnetic resonance imaging (MRI) is the imaging method of choice for diagnosing meniscal tears<sup>9</sup> (Fig. 3). This technique has replaced previous arthrography, which involved inject-

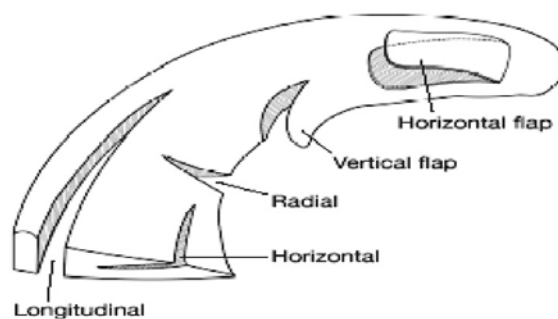


Fig. 2. Different types of meniscal tears: bucket handle – longitudinal, horizontal, radial, vertical and horizontal flap<sup>8</sup>.

ing contrast medium into the joint space. The accuracy of detecting meniscal tears was commonly reported at a level of 80% to 90%<sup>9,10</sup>. With improved technology and increased experience in reading these scans, the accuracy of detection is now considered to be approximately 95% or better<sup>11</sup>.

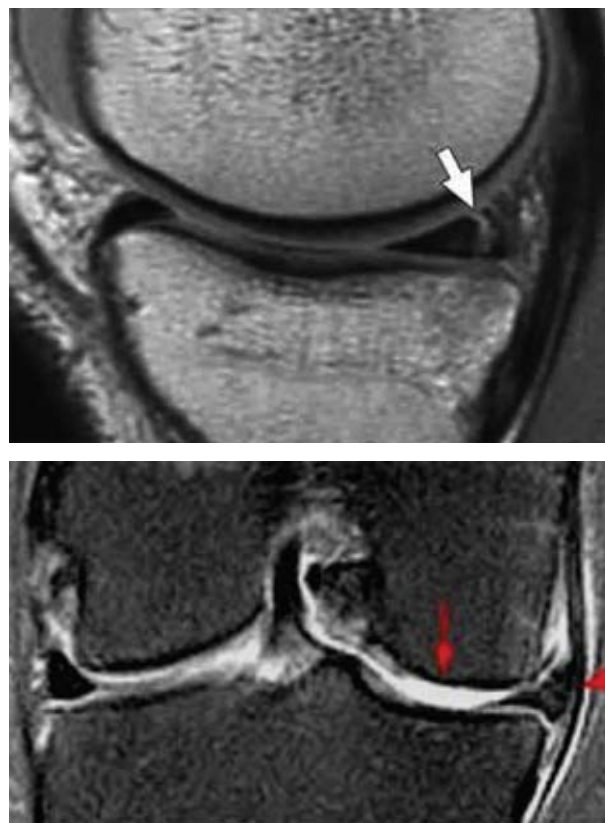


Fig. 3. Magnetic resonance image: medial meniscal ruptures<sup>11</sup>.

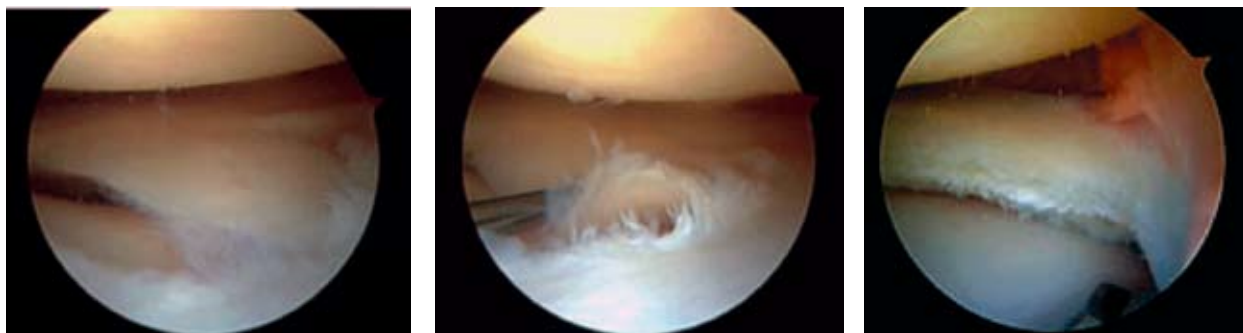


Fig. 4. Arthroscopic presentation of meniscal rupture and partial meniscectomy.

Treatment options for meniscal injuries include nonoperative management, meniscectomy, meniscal repair and meniscal replacement. Numerous studies have shown that knee osteoarthritis is more common after total meniscectomy and that partial meniscectomy is associated with less radiographic and clinical signs of osteoarthritis over time compared with total meniscectomy<sup>8,12</sup>.

The International Knee Documentation Committee (IKDC) score has an overall acceptable psychometric performance for outcome measures of meniscus injuries of the knee<sup>13</sup>.

The aim of our study was to demonstrate that partial meniscectomy is a good method and that it can be considered the method of choice in well selected cases. It is characterized by a simple surgical intervention with fast recovery and return to previous activities, with low morbidity and complication rate.

## Patients and Methods

In this study, results of arthroscopic partial medial meniscectomy in 99 patients treated at Clinical Department of Orthopedics and Traumatology, Podgorica Clinical Center, Podgorica, Montenegro, during the 2005–2013 period were analyzed. Follow up was 12–14 months.

Diagnosing medial meniscal injury included patient history, physical examination (joint line palpation: Bohler's sign, McMurray, Apley and Thessaly tests), MRI and arthroscopy.

Surgical indications for arthroscopic treatment of meniscal pathology include symptoms of meniscal injury that affect activities of daily living, work and/or sports, positive physical findings of joint line tender-

ness, joint effusion, limitation of motion, and positive provocative signs on specific tests.

We followed the general guideline by Metcalf *et al.* on arthroscopic resection that applies to most resectable meniscal lesions, i.e. all mobile fragments that could be pulled past the inner margin of the meniscus into the center of the joint were removed, the remaining meniscal rim was smoothed to remove any sudden changes in the contour that might lead to further tearing, and we tried to protect the meniscocapsular junction and the peripheral meniscal rim during resection<sup>14</sup> (Fig. 4).

Physical therapy exercises to achieve complete range of motion and optimal muscle strength were recommended to athletes and patients with long lasting complaints. We suggest that full range of motion be immediately allowed; 50% of weight bearing and forearm crutches were used for 7–15 days, patients were encouraged to return to normal daily activities approximately 2–3 weeks and sports activities approximately 6–8 weeks after the intervention. The pre- and postoperative results were compared by use of the 2000 IKDC subjective knee evaluation form.

## Results

Our retrospective study cohort classification of meniscal lesions by O'Connor showed 29 vertical complete bucket handle lesions, 14 vertical incomplete lesions, 9 longitudinal tears, 13 oblique tears, 11 complex, flap and degenerative lesions, 10 radial lesions and 13 horizontal lesions (Fig. 5).

In our sample, there were 88 men and 11 women, mean age 36.6 (range 15 to 49) years. Injuries of the right knee meniscus were found in 60 patients. Menis-

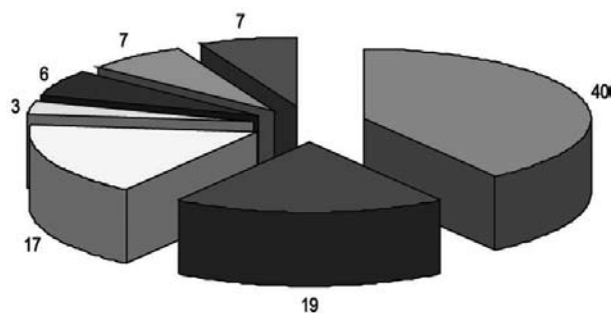


Fig. 5. Distribution of meniscal tear types.

cus injuries were most frequently inflicted in football (Fig. 6). Damage mostly occurs as a result of deceleration, sudden changes of direction, jump, landing, squatting and turning.

In this study, correlation between McMurray, Thessaly and/or Apley tests, and arthroscopic confirmation of medial meniscal tear was positive in 68.68% of cases. Fifty-six of 99 patients underwent knee MRI prior to arthroscopy and the accuracy of preoperative MRI was 71.71%.

During arthroscopy, we found signs of associated anterior cruciate ligament lesions (complete or partial rupture) in 51 cases, and bilateral lesions of the meniscus in 14 cases.

In our series, complications developed in 14 patients. There were 5 cases of knee hemarthrosis that was resolved by puncture and spontaneously resorbed during arthroscopy. In 2 cases, we had to perform minimal open joint (arthrotomy) meniscectomy, while in 2 cases there was instrument failure (arthroscopic knife breakage), three patients had inflammation of the synovial membrane (synovitis) with effusion, and

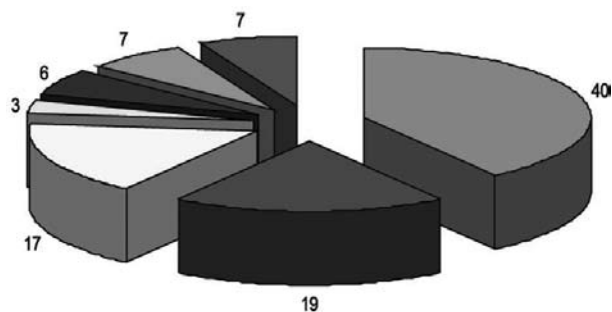


Fig. 6. Percentage distribution of study patients according to the mechanism of injury: 40 football, 19 basketball, 17 handball, 3 volleyball, 6 combat contact sports, 7 skiing, and 7 degenerative and other meniscus injury.

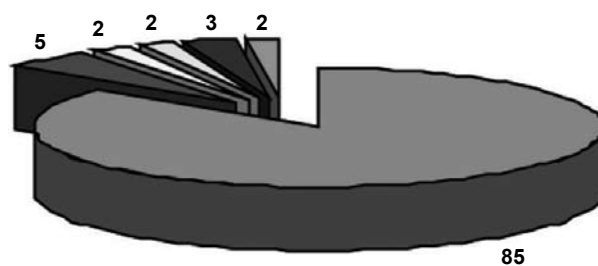


Fig. 7. Distribution of complications: 85 cases were free from complications, 5 had knee hemarthrosis, 2 had open joint (arthrotomy), 2 instrument failures, 3 inflammation of the synovial membrane (synovitis) with effusion, and 2 cases of infection.

two patients had infection (cultures were positive for *Staphylococcus aureus*), which was resolved by high doses of iv. antibiotics (Fig. 7).

The mean preoperative IKDC score was 52.52%. A month after physical rehabilitation of arthroscopic partial meniscectomy, the mean IKDC score was 81.81%, and six months after surgery the mean IKDC score was 92.92%. Six months after the procedure, 92 patients had good or excellent outcome, whereas seven patients had no significant subjective improvement after the intervention.

### Discussion

With the emergence of arthroscopy<sup>15</sup>, arthroscopic surgery of meniscal lesions has entered a new period, a period of partial meniscectomy, thus allowing for the undamaged part of the meniscus to continue to perform its amortization function. Arthroscopy has enabled the classification of meniscal lesions (bucket-handle tear, horizontal tear, longitudinal tear, posterior horn tears, radial tear and oblique tears), which in turn has resulted in better understanding of the injuries and their treatment.

Meniscal tears are the most common injury of the knee and account for one-third of all athletic injuries. Meniscus tears typically occur as a result of twisting or change of position of the weight-bearing knee in varying degrees of flexion or extension. Such injuries are especially prevalent among competitive athletes, particularly those who play football, basketball, volleyball, and sometimes tennis.

Early studies of open partial meniscectomy techniques demonstrated satisfactory results after 4- to 5-year follow up<sup>16</sup>.

In our study, we also had satisfactory results in the postoperative period, and control radiographies after three years did not show degenerative changes. During follow up of treatment results, we did not record poor functional results or degenerative changes on radiographs.

Long-term studies suggest that total meniscectomy results in both poor functional outcome and significant degenerative changes as noted on radiographs<sup>17</sup>. That is the reason why we performed partial meniscectomy in all our patients. There are reports on excellent to good results in 73.8% of 128 patients and in 179 of 194 patients after partial meniscectomy<sup>18,19</sup>. This is in line with our study in which we had good result in 92 of 99 patients. Major advantages of partial arthroscopic meniscectomy include decreased hospitalization, faster rehabilitation and a reduction in health care system costs<sup>20-25</sup>.

In our study, the length of hospitalization of our patients was from one to two (mean 1.75) days.

In our series, six months after partial arthroscopic meniscectomy we had hypotrophy of m. quadriceps only in those patients which had associated anterior cruciate ligament injuries LCA.

Roos *et al.*<sup>26</sup> report on a significant effect of the sports activity levels after meniscectomy. In a sample of 286 football players, the rate of arthritis in the knee was 1.6% in controls, 4.2% in non-elite players and 15.5% in elite players. In our series, three years after partial meniscectomy we recorded no arthritic changes in the operated knees. In their study of resuming physical activity after arthroscopy, Lubowitz *et al.*<sup>27</sup> concluded that most of the patients had no knee-related activity restrictions 4 weeks after arthroscopy. In our patients, full range of motion was allowed immediately, starting with about 50% weight bearing and forearm crutches were used for 2-3 weeks. Return to normal daily activities was allowed at 7-10 days and to sports at 6-8 weeks after the intervention.

We used the IKDC score to obtain appropriate assessments. The IKDC is considered as a reliable and valid instrument for use in a broad patient population. Complications related to arthroscopic partial meniscectomy can be divided into those related to arthros-

copy in general and those specific for partial meniscectomy.

Small<sup>28</sup> analyzed complications reported by 21 arthroscopists over a 19-month period and found the complication rate for medial meniscectomy to be 1.78%, with instrument failure accounting for 2.9% of all arthroscopic complications.

In our series, complications were found in 14 patients, which is consistent with the results reported elsewhere.

## Conclusion

Arthroscopic partial medial meniscectomy is a minimally invasive diagnostic and therapeutic procedure. In most cases, arthroscopic partial medial meniscectomy surgery stands as an ideal procedure for the concept of one-day surgery. The technique of arthroscopy has provided orthopedic surgeons a very powerful and highly successful tool in diagnosing and treating meniscal tears.

Meniscus tear is a common sports related injury. Arthroscopic partial meniscectomy has been a standard treatment for symptomatic cases. It is a minimally invasive diagnostic and therapeutic procedure, which allows preservation of normal meniscal function and avoids or reduces the risk of osteoarthritis that may develop after total meniscectomy. In all our patients, we extirpated all mobile and unstable meniscal parts, and we always tried to keep the meniscocapsular bond, i.e. meniscectomy was done up to the healthy tissue.

Analysis of our results showed that the greatest percentage of injuries of medial meniscus were vertical complete bucket handle lesions and vertical incomplete lesions, which is consistent with the findings of other authors (more than 50%). The IKDC score after 6 months was 92.92%, comparable to the findings reported by other authors; also 6 months after the procedure, almost 92% of patients had good or excellent outcome. Significant subjective improvement after the intervention was found in seven patients.

Partial meniscectomy is characterized by low percentage of complications and fast and simple rehabilitation of the patient. However, this procedure is not the ultimate treatment; it should rather be viewed as the beginning of a supervised rehabilitation program

for early and smooth return to sports activities without complications.

In the monitoring period, degenerative changes in the structure of the knee (cartilage) were not detected after partial meniscectomy, and if there were, these changes did not affect functional scoring, which remained excellent.

Since we had complications in two patients, i.e. breakage of meniscal knife, we consider that arthroscopic surgery should be performed by experienced surgeons to avoid complications. With partial meniscectomy, we prevent further damage to the internal knee structures while allowing early rehabilitation and fast return to everyday life, work and sports activities.

## References

- Radin EL, de Lamotte F, Maquet P. Role of the menisci in the distribution of stress in the knee. *Clin Orthop Relat Res* 1984;185:290-4.
- Messner K, Gao JJ. The menisci of the knee joint. Anatomical and functional characteristics, and a rationale for clinical treatment. *J Anat*. 1998;193(Pt 2):161-78.
- Platzer W. *Color Atlas of Human Anatomy, Vol. 1: Locomotor System*. 5th revised and enlarged English edition. Stuttgart, New York: Thieme; 2004.
- Arnoczky SP, Warren RF. Microvasculature of the human meniscus. *Am J Sports Med*. 1982;10:90-5.
- Day B, Mackenzie WG, Shim SS, Leung G. The vascular and nerve supply of the human meniscus. *Arthroscopy*. 1985;1:58-62.
- Schutte MJ, Dabezius EJ, Zimny ML, Happe LT. Neural anatomy of the human anterior cruciate ligament. *J Bone Joint Surg Am*. 1987;69:243-7.
- Baker PE, Peckham AC, Puppato F, Sanborn JC. Review of meniscal injury and associated sports. *Am J Sports Med*. 1985;13:1-4.
- Englund M. Meniscal tears, a feature of osteoarthritis. *Acta Orthop Scand Suppl*. 2004;75(312):1-45.
- Major NM, Beard LN Jr, Helms CA. Accuracy of MR imaging of the knee in adolescents. *AJR Am J Roentgenol*. 2003;180(1):17-9.
- Helms CA. The meniscus: recent advances in MR imaging of the knee. *AJR Am J Roentgenol* 2002;179(5):1115-22.
- Teller P, König H, Weber U, Hertel P. *MRI atlas of orthopedics and traumatology of the knee*. London: Springer, 2003.
- Weinstabl R, Muellner T, Vécsei V, Kainberger F, Kramer M. Economic considerations for the diagnosis and therapy of meniscal lesions: can magnetic resonance imaging help reduce the expense? *World J Surg*. 1997;21(4):363-8.
- Higgins LD, Taylor MK, Park D, Ghodadra N, Marchant M, Pietrobon R, *et al.* International Knee Documentation Committee. Reliability and validity of the International Knee Documentation Committee (IKDC) Subjective Knee Form. *Joint Bone Spine*. 2007;74(6):594-9.
- Metcalfe RW, Burks RT, Metcalfe MS, McGinty JB. Arthroscopic meniscectomy. In: McGinty JB, Caspari RB, Jackson RW, Poehling GG, editors. *Operative Arthroscopy*. 2nd ed. Philadelphia, PA: Lippincott-Raven, 1996;263-97.
- Simpson DA, Thomas NP, Aichroth PM. Open and closed meniscectomy – a comparative analysis. *J Bone Joint Surg (Br)*. 1986;65:388-90.
- Northmore-Ball MD, Dandy DJ, Jackson RW. Arthroscopic, open, partial, and total meniscectomy. A comparative study. *J Bone Joint Surg (Br)*. 1983;65:400-4.
- Teurlings L. Meniscal injuries. In: Arendt EA, editor. *Orthopaedic knowledge update: sports medicine 2*. Rosemont, IL: American Academy of Orthopedic Surgeons, 1999;349-53.
- Hede A, Larsen E, Sandberg H. Partial *versus* total meniscectomy: a prospective, randomised study with long-term follow-up. *J Bone Joint Surg (Br)*. 1992;74-B:118-21.
- Hulet CH, Locker BG, Schiltz D, Texier A, Tallier E, Vielpeau CH. Arthroscopic medial meniscectomy on stable knees: a 12-year follow-up. *J Bone Joint Surg (Br)*. 2001;83:29-32.
- Dašić Z, Radočić D. Arthroscopic partial medial meniscectomy. *Vojnosanit Pregl*. 2011;68(9):774-8.
- Bolano LE, Grana WA. Isolated arthroscopic partial meniscectomy: functional radiographic evaluation at five years. *Am J Sports Med*. 1993;21:432-7.
- Seitz AM, Lubomierski A, Friemert B, Ignatius A, Dürselen L. Effect of partial meniscectomy at the medial posterior horn on tibiofemoral contact mechanics and meniscal hoop strains in human knees. *J Orthop Res*. 2012;30(6):934-42.
- Neyret P, Donell ST, Dejour H. Results of partial meniscectomy related to the state of the anterior cruciate ligament: review at 20 to 35 years. *J Bone Joint Surg (Br)*. 1993;75-B:36-40.
- Appel H. Late results after meniscectomy in the knee joint: a clinical and roentgenologic follow-up investigation. *Acta Orthop Scand Suppl*. 1970;133:1-111.
- Hoser C, Fink C, Brown C, *et al.* Long-term results of arthroscopic partial lateral meniscectomy in knees without associated damage. *J Bone Joint Surg (Br)*. 2001;83B:513-6.
- Roos H, Lindberg H, Gardsell P, Lohmander LS, Wingstrand H. The prevalence of gonarthrosis and its relation to meniscectomy in former soccer players. *Am J Sports Med*. 1994;22:219-22.
- Lubowitz JH, Ayala M, Appleby D. Return to activity after knee arthroscopy. *Arthroscopy*. 2008;24(1):58-61.
- Small NC. Complications in arthroscopic meniscal surgery. *Clin Sports Med*. 1990;9(3):609-17.

## Sažetak

## LIJEČENJE OZLJEDA MEDIJALNOG MENISKUSA PARCIJALNOM MENISSEKTOMIJOM

Ž. Dašić, N. Bulatović, M. Kezunović, I. Benčić i V. Bokan

Parcijalna meniscektomija podrazumijeva djelomično uklanjanje meniskusa. Ovo može varirati od manje ekstirpacije oštećenog dijela meniskusa do uklanjanja rascjepa s meniskokapsularnog hvatišta. Ozljede meniskusa su najčešće ozljede koljena. One se mogu javiti kao akutne ozljede koljena kod mlađih bolesnika ili kao dio degenerativnog procesa u starijih osoba. Cilj studije bio je pokazati metodu izbora u liječenju ozljeda medijalnog meniskusa koja u dobro odabranim slučajevima dovodi do malog postotka komplikacija i brze rehabilitacije. U studiji su analizirani rezultati artroskopske parcijalne medijalne meniscektomije kod 99 bolesnika u razdoblju od 2005. do 2013. godine s praćenjem kroz 12-14 mjeseci. U našoj seriji bolesnika liječenih ovom metodom utvrđen je rascjep poput drške košarice (*bucket handle*) u 29, vertikalni nepotpuni rascjep u 14, uzdužni rascjep u 9, kosi rascjep u 13, degenerativna lezija u 11, radijalni rascjep u 10 i horizontalni rascjep u 13 bolesnika. Prosječni prijeoperacijski zbir IKDC (*International Knee Documentation Committee*) bio je 52,52%, jedan mjesec nakon parcijalne artroskopske medijalne meniscektomije IKDC je bio 81,81%, a šest mjeseci nakon parcijalne meniscektomije 92,92%. Artroskopska parcijalna medijalna meniscektomija je minimalno invazivan dijagnostički i terapijski zahvat. Ona je prihvatljiva i učinkovita kao liječenje, naročito kod bolesnika bez značajnog oštećenja zglobne hrskavice, a praćena je minimalnim pobolom.

Ključne riječi: *Meniskusi, tibijalni – kirurgija; Meniskusi, tibijalni – ozljede; Artroskopija – metode*