

Neurosurgical Procedure for Treatment of Traumatic Subdural Hematoma with Severe Brain Injury: A Single Center Matched-Pair Analysis

Dean Giroto¹, Darko Ledić¹, Vlado Đajić², Zoran Vujković² and Nenad Mihelčić³

¹Neurosurgery Clinic, Clinical Hospital Centre Rijeka, Rijeka, Croatia

²Clinic of Neurology, Clinical Centre Banja Luka, University of Banja Luka, Banja Luka, Bosnia and Herzegovina

³Department of Statistics, Pennsylvania State University, Pennsylvania, USA

ABSTRACT

Decompressive craniectomy (DC), an auxiliary neurosurgical invasive procedure, has been a part of the treatment regimen for severe brain injury (SBI). Today DC is the standard of care in patients with middle cerebral artery infarction. Our previous positive research results about effectiveness of DC procedure when applied to a specific group of SBI patients have made a solid base for a clinical evaluation of DC technique application to patients with isolated SBI with traumatic subdural hematoma (TSDH), despite controversies regarding clinical benefit of DC technique when applied to STBI patients. A matched-pair analysis has been performed to compare long-term clinical outcomes in patients with and without the DC technique applied. This study has encompassed 150 consecutive STBI patients with TSDH, aged between 18 and 82 years. One hundred patients had required application of DC procedure, while remaining 50 patients represented a matched control group in which the DC procedure had not been applied. The control group match was conducted on the basis of epidemiological and potential prognostic factors, such as age, gender, DC surface area and Glasgow Coma Score (GCS). The main reason for occurrence of STBI with TSDH was traffic accidents, with sex ration 2:1 (male/female), while 2/3 of patients were aged between 26 and 40 years. Mortality rate of 18% had occurred in the group of patients in which DC procedure was applied early in the first 24 hours after the injury, while mortality rate of 54% had occurred in the group of patients in which DC procedure was applied later than 24 hours after the injury, in comparison to mortality rate of 35% that had occurred in the control matched group of patients. Also, better control of intracranial pressure (ICP) had occurred in patients in which a DC surface was made larger than 40ccm. In addition, less computed tomography (CT) scans were made as a follow up care procedure in patients in which DC procedure was performed and especially if DC procedure had been performed within 24 hours after the injury. However, regardless of many positive results that an early application of DC procedure has had on SBI patients with TSDH, an expected increase in immediate or delayed complications had occurred, for example we had recorded an increased number of encefalocele. Significantly better outcome of clinical recovery with less cases of morbidity and deaths had occurred in patients in which TSDH was removed with the DC technique within 24 hours after the time of injury and also if a DC surface had had size over 40 ccm, in comparison to the group of patients that had TSDH removed with DC technique within longer period of time than 24 hours after the time of injury and also better than the control group.

Key words: decompressive craniectomy, elevated intracranial pressure, severe brain injury, traumatic subdural hematoma, treatment outcome

Introduction

In patients with STBI it is a very common to find accumulated extra-axial hemorrhagic mass lesion, acute subdural hematoma (ASDH), compressing brain tissue¹. When such injuries reach consciousness level of 8 or less than 8, measured by neurological Glasgow Coma Scale

(GCS), then they cause morbidity and mortality in patients. Nowadays STBI with ASDH is the leading cause of morbidity and mortality of young and middle aged population of people and therefore one of the top public health concerns^{1–6}. Despite modern technology and also a high

level of neurosurgical and medical research science, ASDH patients have great mortality rate^{2–4,7}. Neurosurgeons treat ASDH with standard neurosurgical procedure craniotomy for removal of intracranial blood clots and also to prevent re-bleeding. This neurosurgical procedure is the standard in clinical procedures for treatment of ASDH⁵. However, another neurosurgical procedure the decompressive craniectomy (DC) for the treatment of patients with ASDH has been approved as a protocol-guided treatment step rather by some neurosurgeons⁴. Likewise, some neuroscientist has been unsure whether DC surgery would be beneficial⁷. But, sequentially additional extra-axial hemorrhage occurrence and also, a brain edema formation do worsen the outcome for STBI patients by producing additional increase in intracranial pressure (ICP) up to the lethal level^{8–13}.

The fact that our previous research study regarding treatment outcomes after application of DC treatment¹⁴ to STBI patients without extra-axial hemorrhage has revealed positive results and also, the fact that clinical recovery rates have not shown much of the improvement when modern neurointensive care treatments of STBI patients with ASDH had been applied, have challenged us to conduct a new research study with responsibility to confirm or disprove usefulness of DC treatment in ASDH patients¹⁵.

Materials and Methods

Our prospective case-controlled study has included 150 STBI patients with ASDH (only TSDH patients), aged from 18–82 years old, who had been treated at the Clinical Hospital Centre Rijeka, and had been followed for 10 years, from January 2002 till June 2012. Clinical benefit outcomes had been compared with a matched-pair analysis of a group of 100 patients in which DC technique had been applied and also, a matched control group of 50 patients in which DC treatment was not applied for ASDH removal. Additional requirements for three groups of patients were: group „A« had had DC treatment applied early within 24 hours from the time of injury and also, had passed standard medical neurosurgical ASDH patients care; group „B« had had initially subdural hematoma surgically removed, and then 24 hours after the primary surgical procedure and also after a head CT scan additionally the DC treatment had been applied (obviously later than 24 hours from the time of injury); and group „K« had had initially subdural hematoma surgically removed, but without application of DC treatment.

Prospective follow-up interval range have been for all groups: immediately after hospital treatment, then 6 months after that, and also 1 year from the time of injury acquiring detection of incidence of possible infections or complications during hospitalization and describing health benefit according to Glasgow Outcome Scale (GOS). Also, a 24 months clinical follow-up examination have been conducted after patients had been released from hospital.

Statistics

Calculated sample size of (n+33) has given us a power of 95%. However, to be on a safe side we have increased sample size to (n=50). The (H0) tested was that there were no difference between clinical treatment benefit outcomes of treatment groups from a sample of 150 STBI patients with ASDH, regardless of clinical neurosurgical treatment used as a sample treatment. To test (H0) the acceptance of type II error has been appropriate, because analysis has depended on the size and characteristics of the examined sample¹⁶. The experiment wise error rate $\alpha=0.05$ has been applied. Initially performed cluster analysis has revealed interesting clusters that had been further analyzed using statistical tests: two tailed repeated measures analysis of variance for one factor with two groups with Greenhouse-Geisser correction; one tailed analysis of variance (ANOVA) with Tukey-HSD test; Wilcoxon two-tailed paired test; and Fisher's exact test. Collected data set most likely has had »Poison« data distribution and also, to avoid a numerous zero's, prior to analysis a value of 0.5 was added to all data and data set was transformed with formula ($\sqrt{(X+0.5)}$) (data were back transformed for visualization and table formation).

Results

Road traffic collision were a major reason for SBI with ASDH, with sex ratio of 2:1 (male/female), while 2/3 were aged between 26 and 40 years (Table 1). Mortality of 18% had occurred in a group of patients in which DC was done early within 24 hours from injury time, while mortality of 54% had occurred in a group of patients in which DC was done after 24 hours from injury time, comparing to mortality of 35% that had occurred in a control group of patients in which DC was not done. Also, a better control of elevated intracranial pressure (ICP) had occurred in a group »A« and subgroup in which the DC surface had size over 40 ccm. In addition, less CT scans were necessary as a follow-up procedure in patients in which DC had been done, and especially in a subgroup in which an early DC had been performed. Even though many positive effects that early DC technique had showed on patients, also nu-

TABLE 1
SUMMARY OF MEAN VALUES THAT SHOWS DIFFERENT REASONS THAT CAUSED STBI WITH ASDH IN PATIENTS. PATIENTS HAVE BEEN DIVIDED, AFTER THEY HAD COME TO HOSPITAL, INTO TWO SUBGROUPS ACCORDING TO RECORDED GCS VALUES

Reasons of accident	Group A		Group B		Control group	
Traffic Accidents	0.28	0.30	0.34	0.16	0.18	0.24
Falls from height	0.08	0.20	0.20	0.12	0.22	0.34
Various Accidents	0.04	0.10	0.16	0.02	0.02	0.00
GCS value	3–5	6–8	3–5	6–8	3–5	6–8

merous complications had been recorded and one of them was increased number of encephalocele and that was expected. Also, a better survival rate had occurred in subgroups of patients with higher GCS 6–8 (Figure 1) when compared to lower GCS 3–5 (Figure 2). Increased size DC has had only statistically significant difference in a subgroup GCS 6–8 in the group »B«. As a result of our study, statistically the majority of the significant differences and the best results of clinical benefit and recovery had occurred in the group of patients aged up to 40 years, regardless of GCS value and when the DC surgical procedure has been done within first 3–4 hours from the time of injury.

Discussion

Patients with TSDH have undergone high mortality rate especially when a TSBI has been the base of the problem. On time application of invasive surgical DC procedure to treat ATSDH that has occurred after TSBI and followed up with modern neurointensive clinical treatment could reduce mortality and morbidity in a specific group of patients. We also believe that modern neurointensive care in patients that have been injured in traffic accidents must involve a clinical measure of ICP monitoring all the way from the beginning of hospitalization. In some recent studies the DC procedure has been recommended as a method of choice for external decompression and reduction of elevated ICP which at the one end should give much better clinical benefit and hospitalization outcome. Our study has had to rely only on patients from our hospital, which could be objected in regard of relatively small sample size, but also that has been the benefit because of more uniform and precise work by properly trained physicians and surgeons. Another objection could be a big number of subgroups of patients within major groups that could overlap in certain periods and also certain characteristics and could show identical values which might cause confusion of research team. However, above mentioned events that could have potently caused problems have been a very common working environment problems and coping with those problems and keeping up with rigorous research ethics could be sometimes a big challenge that should be successfully managed by well-organized research team while prioritizing patient benefits and their wellbeing.

Conclusion

Our data with confidence justify and strongly support the idea to apply the DC technique of adequate size, early from the time of injury, to a very specific group of STBI patients that have acute intracranial extra-axial hemorrhage (especially a subgroup that has GCS of 6–8), which would contribute significantly to a better clinical health benefit outcome by reducing morbidity and mortality rates. However, in patients with lower value of GCS positive effects would disappear and then the DC procedure should not be a surgical procedure of choice. Also, we recommend that the DC technique should be preferably a neurosurgical method of choice for younger STBI patients with TSDH regardless on GCS value. In addition, the DC procedure has been a standard technique that does not depend on the technique of opening the dura, but it does depend on surface size of the bone flap that gets removed, and as a consequence of the process of not closing the dura when performing decompression many more complications specific for DC procedure could occur. This mainly applies to DC procedure utilized for removal of subdural hemorrhage where after bone flap removal we can gain extra space utilizing slight elasticity of dura which will result with less complications or infections. Probability that the DC procedure will change as a neurosurgical technique in the future to provide better health benefit is very low, actually there is not much to be desired from the surgical

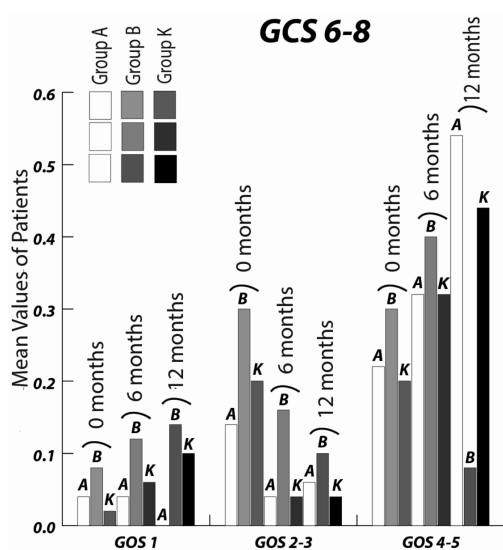


Fig. 1. Comparison of health benefit outcome of patients with GCS 6–8.

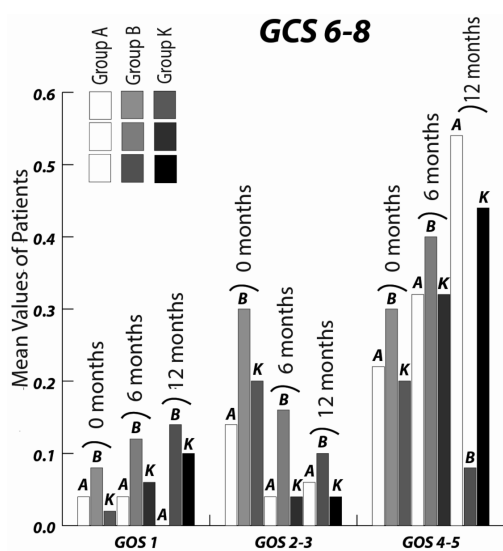


Fig. 2. Comparison of health benefit outcome of patients with GCS 3–5.

point of view, but future research has to focus on the new pharmacological therapies that will be supplement to the

DC technique providing better health benefit and survival outcome.

REFERENCES

1. THURMAN D, ALVERSON C, DUNN K, GUERRERO J, SNI-EYEK JE, *J Head Trauma Rehabil*, 14 (1999) 602. — 2. ANGERMAN A, BAUER R, NOSSEK G, ZIMMERMANN N, Kuratorium für Verkehrssicherheit – Austrian Road Safety Board Statistics summary, 2 (2007) 1. — 3. TAGLIAFERRI F, COMPAGNONE C, KORSIC M, SERVADEI F, KRAUS J, *Acta Neurochir (Wien)*, 148(3) (2006) 255. — 4. THORNHILL S, TEASDALE GM, MURRAY GD, MCEWEN J, ROY CW, PENNY K, *BMJ*, 320 (2000) 1631. — 5. POLINDER S, MEERING WJ, VAN BAAR ME, TOETH H, MULDER S, VAN BEECK EF, *J Trauma*, 59 (2005) 1283. — 6. FRIDLEY J, THOMAS J, KITAGAWA R, CHERN J, OMEIS I, *Journal of Clinical Neuroscience*, 18 (2011) 422. — 7. SHEN J, FAN Z, JI T, PAN J, ZHOU Y, ZHAN R, *Neuro Med Chir (Tokyo)*, 53 (4) (2013) 221. — 8. CHEN SH, CHEN Y, FANG WK, HUANG DW, HUANG KC, TSENG SH, *J Trauma*, 71(6) (2012) 1632. — 9. KOLIAS AG, LI LM,

CORTEEN EA, TIMOFEEV I, KIRKPATRICK PJ, HUTCHINSON PJ, *J Trauma Acute Care Surg*, 72(5) (2012) 1451. — 10. KOLIAS AG, LI LM, GUILFOYLE MR, TIMOFEEV I, CORTEEN EA, PICKARD JD, *Acta Neurochir (Wien)*, 155(1) (2013) 187. — 11. KOLIAS AG, SCOTTON WJ, BELLI A, KING AT, BRENNAN PM, BULTERS DO, *Br J Neurosurg*, 27(3) (2013) 330. — 12. ZINK BJ, *Ann Emerg Med*, 37(13) (2001) 318. — 13. MAAS AIR, HUKKELHOVEN CWPM, MARSHALL LF, STEYERBERG EW, *Neurosurgery*, 57(6) (2005) 1173. — 14. GIROTTO D, LEDIC D, BAJEK G, JERKOVIĆ R, DRAGIČEVIĆ S, *Coll Antropol*, 35(2) (2011) 255. — 15. KAWAMATA T, KATAYAMA Y, HOVDA DA, YOSHINO A, BECKER DP, *Brain Res*, 674(2) (1995) 196. — 16. BOWLEY SR, *A Hitchhiker's guide to statistics in plant biology* (Any Old Subject Books, Ontario, 1999).

D. Giroto

Neurosurgery Clinic, Clinical Hospital Centre Rijeka, Tome Strižića 3, 51 000 Rijeka, Croatia
e-mail: gdeanrow@gmail.com

NEUROKIRURŠKI POSTUPAK U LIJEČENJU TRAUMATSKOG SUBDURALNOG KRVARENJA KOD TEŠKE OZLJEDE MOZGA: ISTRAŽIVANJE JEDNE USTANOVE ANALIZOM ZAVISNIH UPARENIH POSTUPAKA

SAŽETAK

Dekompresijska kraniektomija (DC) kao pomoćni invazivni neurokirurški postupak je dio standardnog protokola u liječenju TOM-a. Danas je DK standardni postupak u liječenju oboljelih od infarkta srednje moždane arterije. Naši prijašnji pozitivni rezultati istraživanja o učinkovitosti DC procedure na specifičnu grupu bolesnika s TOM-om predstavljaju solidnu osnovu za kliničku evaluaciju primjene DC tehnike na bolesnike s TOM-om uz prisutni TSDH, unatoč kontradiktornosti u glede pozitivnog kliničkog učinka DC tehnike i njene primjene na bolesnike s TOM-om. Analiza zavisnih uparenih uzoraka je primijenjena za usporedbu dugotrajnog kliničkog ishoda bolesnika u kojih je primijenjena DC i bolesnika u kojih nije primijenjena DC tehnika. Istraživanje je obuhvatilo 150 bolesnika s TOM-a s prisutnim TSDH, starosti od 18 do 82 godine. 100 bolesnika zahtijevalo je primjenu DC procedure, dok u preostalih 50 bolesnika nije izvršena DC te su oni predstavljali upareni kontrolni uzorak. Kontrolna grupa bolesnika bila je uparena na temelju epidemioloških i kliničko prognostičkih čimbenika kao što su: starost, spol, površina DC otvora i Glasgowske ljestvice svijesti (GCS). Glavni uzrok nastanka TOM-a uz prisutno TSDH-a bile su prometne nesreće, uz odnos spolova od 2:1 (muški / ženski), dok su 2/3 ispitanika bili u dobi između 26 do 40 godine života. Smrtnost od 18% bilo je prisutno u skupini bolesnika u kojoj je DC tehnika učinjena rano u prvih 24 sata od vremena ozljeđivanja, dok je smrtnost od 54% bilo prisutno u skupini bolesnika u kojoj je DC učinjena nakon 24 sata od vremena ozljeđivanja, u odnosu na smrtnost od 35% koje je bilo prisutno u kontrolnoj skupini bolesnika u kojoj DC nije učinjena. Također, bila je prisutna bolja kontrola povišenog intrakranijskog tlaka (ICP), ukoliko je DC površina bila napravljena veća od 40 cm². Osim toga, manje CT kontrola je bilo potrebno kao kontrolni postupak u bolesnika u kojih je DC tehnika bila izvršena, a posebice ukoliko je DC tehnika bila izvedena u prvih 24 sata od ozljede. Međutim, bez obzira na mnoge pozitivne učinke koje rana primjena DC tehnike imala na bolesnike TOM-a s TSDH-om, brojne komplikacije su zabilježene i jedna od njih je povećan broj „encefalokela«, što je bilo očekivano. Značajno bolji ishod hospitalizacije s manje invalidnosti i smrtnosti je bio prisutan ukoliko je bolesnicima odstranjen TSDH, primjenom DC tijekom 24 sata od vremena ozljede te ukoliko je rana DC napravljena površine veće od 40cm² u usporedbi s bolesnicima u kojih je DC primijenjena nakon 24 sata u odnosu na vrijeme ozljede ili pak kontrolne skupine.