

# Comparison of 23 Gauge and 25 Gauge PPV in the Treatment of Epiretinal Membranes and Macular Holes

Damir Kovačević, Ivana Valković Antić and Aldo Valković

Department of Ophthalmology, Clinical Hospital Center Rijeka, Rijeka, Croatia

## ABSTRACT

*The aim of this study was to show the long term recovery after the operative procedure of pars plana vitrectomy (PPV) in patients with epiretinal membranes (ERM) and macular holes. We wanted to show if there is a difference in operative approach and results of 23 and 25 gauge PPV. Twenty eight patients underwent to operative treatment of idiopathic ERM and macular holes grade III and IV. In our study there was not a statistical significant difference in visual acuity (VA) between 23 gauge and 25 gauge operated patients, both ERM and macular holes. Although both approaches are good, morphological restitution do not always follow the functional recovery.*

**Key words:** vitrectomy, gauge, epiretinal membranes, macular holes, visual acuity

## Introduction

Vitreomacular adhesion is defined as perifoveal vitreous separation with remaining vitreomacular attachment and unperturbed foveal morphologic features. It is a finding that is almost always the result of normal vitreous aging, which may lead to pathologic conditions. Vitreomacular traction is characterized by anomalous posterior vitreous detachment accompanied by anatomic distortion of the fovea, which may include pseudocysts, macular schisis, cystoid macular edema, and subretinal fluid.

Full-thickness macular hole (FTMH) is defined as a foveal lesion with interruption of all retinal layers from the internal limiting membrane to the retinal pigment epithelium. It is primary if caused by vitreous traction or secondary if directly the result of pathologic characteristics other than VMT. FTMH is subclassified by size of the hole as determined by optical coherent tomography (OCT) and the presence or absence of VMT<sup>1,2</sup>. The vitreomacular traction syndrome represents a wide spectrum of vitreoretinal anatomic configurations that can produce visual deficit. Vitrectomy surgery to release macular traction may improve visual acuity (VA)<sup>3</sup>. Pars plana vitrectomy can relieve macular traction, improve VA and prevent a further decrease of VA<sup>4</sup>.

Pielen et al.<sup>5</sup> made a study in which 20 gauge and 23 gauge vitrectomy is compared for macular surgery due to

macular pucker or macular hole performed in 61 and 59 eyes, respectively, by 2 experienced surgeons and 2 trainees. In this homogenous large cohort, they did not find a statistically significant difference in rates of complications between 23 gauge and 20 gauge vitrectomy techniques for macular surgery. Trainees performed equally well as experienced surgeons<sup>5</sup>.

The purpose of our study was to investigate and evaluate the difference between 23-gauge and 25-gauge pars plana vitrectomy in assesment of idiopathic epiretinal membranes (ERM) and macular holes grade III and IV.

We evaluated preoperative and postoperative visual acuity, OCT and postoperative complication in both operative techniques made by one experienced surgeon.

## Patients and Methods

In this retrospective study, from May 2011 to May 2013, 28 eyes of 28 patients werw examined and surgically treated. All of our patients were examined and operated at Departement of Ophthalmology, Clinical Hospital Center Rijeka. Patients were selected in accordance with the following inclusion criteria: diagnosis of idiopathic ERM (Figure 1) and macular hole grade III and IV (Figure 2).

All of patients had visual disturbances, such as decreased VA, metamorphopsia and micropsia in a period of 4–12 months.

Age range was from 45 to 81 years. Twenty patients underwent operative treatment due to ERM (Figure 3). Twelve of them underwent 23 gauge pars plana vitrectomy and 8 patients 25 gauge pars plana vitrectomy. Mean age was 71.2 years. 8 patients underwent pars plana vitrectomy due to macular hole grade III and IV (Figure 4). Five patients underwent 23 gauge pars plana vitrectomy and 3 patients 25 gauge pars plana vitrectomy. Mean age was 76.8 years.

All patients were given a complete ophthalmological assessment prior to treatment and at following visits 12 months after.

Long distance VA in accordance of Snellen lines, slit-lamp ophthalmoscopy, tonometry, biomicroscopy of the fundus oculi and Optical Coherence Tomography were performed prior to surgery and repeated at each check-up.

Postoperatively we analyse retinal function through the examination of VA rather than through other tests used to assess the outcome of operative treatment of our patients such as OCT- which evaluate morphological restitution of macular tissue.

For statistical analysis Statistica 8 (StatSoft, Inc., USA) software was used. A p-value <0.05 was considered statistically significant. The relationship between 23 gauge and 25 gauge PPV was analyzed using Pearson correlation coefficient.

## Results

In this retrospective study the data of 28 eyes of 28 patients were analysed, 20 patients were operated due to idiopathic ERM and 8 patients were operated due to macular hole grade III and IV.

Of 20 patients with ERM, 12 patients had 23-gauge PPV procedure and 8 patients 25-gauge procedure.

Of 8 patients with macular hole grade III and IV, 5 patients had 23-gauge procedure and 3 patients 25-gauge procedure.

In a series of 20 eyes with ERM, 9 of 12 patients operated PPV and ERM peeling with 23-gauge instruments demonstrated stabilization or improvement in VA of at least 3 Snellen lines (75%) with achieving VA 0.1 or better (Figure 5). In a group 25-gauge operated, 6 of 8 patients demonstrated stabilization or improvement of VA of at least 2

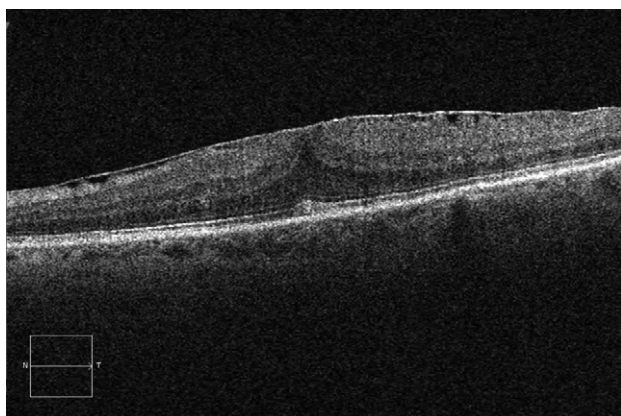


Fig. 1. Macular epiretinal membrane (ERM) before surgery.

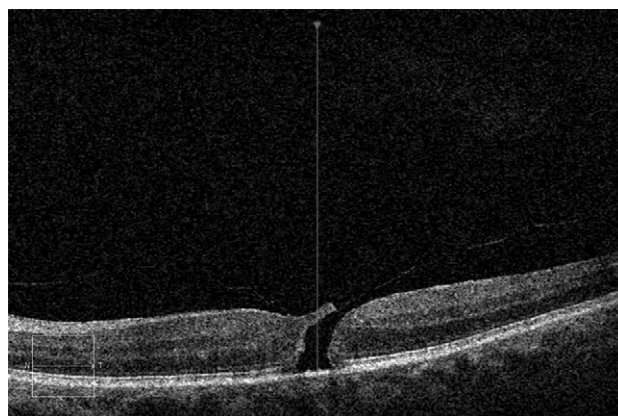


Fig. 2. Macular hole before surgery.

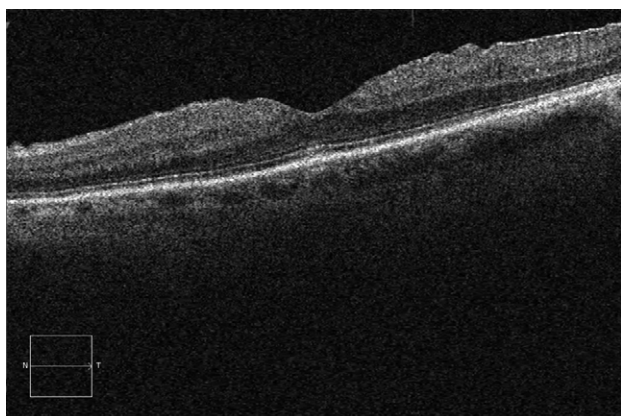


Fig. 3. Macula after epiretinal membrane (ERM) surgery.

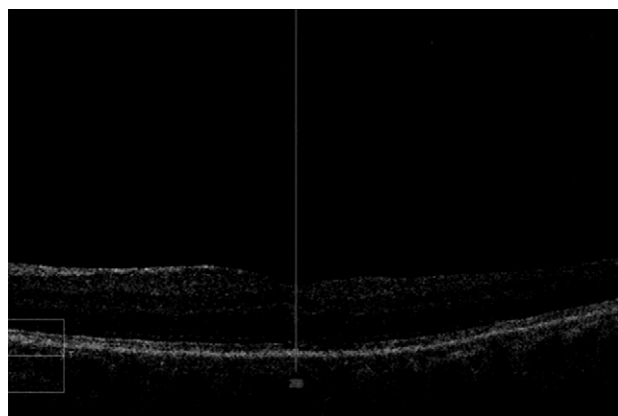


Fig. 4. Macular hole after surgery.

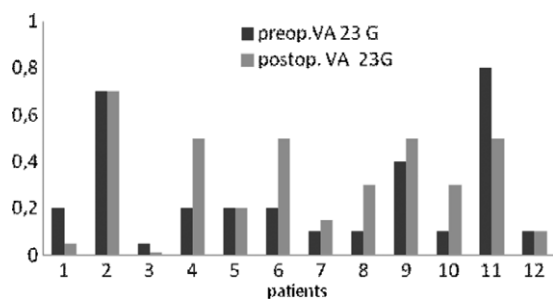


Fig. 5. Visual acuity (VA) in 23G pars plana vitrectomy (PPV) membrane peeling.

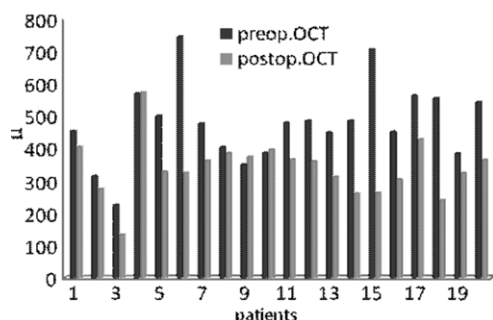


Fig. 7. Macular optical coherent tomography (OCT) in epiretinal membrane (ERM).

Snellen lines (75%) with achieving VA 0.1 or better (Figure 6).

Optical coherent tomography (Cirrus HD-OCT, Carl Zeiss Meditec) showed significant improvement in thinning of neuroretinal layer.

Mean preoperative thickness was 447,95 microns, and mean postoperative thickness was 320,35microns (Figure 7).

In a series of 8 eyes with macular hole grade III and IV, 5 of 8 patients were operated 23-gauge PPV and demonstrated stabilization or improvement in VA of at least 3 Snellen lines (62.5%) with achieving VA 0.1 or better. In a group 25-gauge PPV 3 patients were operated, 2 of 3 patients demonstrated stabilization or improvement of VA of at least 1 Snellen lines (66.7 %) with achieving VA 0.1 or better (Figure 8). Mean preoperative VA for 23-gauge PPV ERM peeling was 0.14 and postoperative VA was 0.17. In a group using 25-gauge PPV for ERM peeling preoperative VA was 0.24 and mean postoperative VA 0.28 in Snellen lines.

In our study mean preoperative VA using 23-gauge PPV for macular hole was 0.16, and postoperative VA 0.18. In a group using 25-gauge PPV for macular hole preoperative VA was 0.17 and postoperative 0.22. Poorer results of pars plana vitrectomy for macular holes are due to grade III and IV macular hole operated.

Statistical significance between VA before and after operation was observed in patients operated using

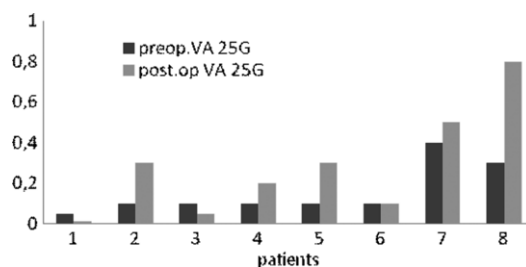


Fig. 6. Visual acuity (VA) in 25G pars plana vitrectomy (PPV) membrane peeling.

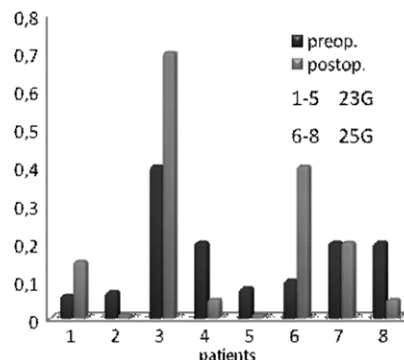


Fig. 8. Preoperative and postoperative VA in macular hole.

23-gauge pars plana vitrectomy ( $p=0.79$ ) and patients operated using 25-gauge pars plana vitrectomy ( $p=0.65$ ). There were no statistical significant difference ( $p>0.05$ ) between two groups.

There was not serious complications such as endophthalmitis or postoperative wound leakage in our patients. Suturing was required in 4 patients in the 23-gauge group and 3 patients in the 25-gauge group. Retinal haemorrhage occur in 1 patient in the 23-gauge group and 2 patients in the 25-gauge group. Peripheral retinal rupture occurred in 1 patient in 23-gauge group.

## Discussion

Majority of published studies reporting results of PPV specifically for VMT consist of small cohort studies. However, these all indicate a high success rate<sup>6</sup>.

Grosso et al.<sup>7</sup> assessed the safety, clinical effectiveness, cost and financial evaluation of 23-gauge compared with 25-gauge vitrectomies. Fifty patients entered the study; 14 patients underwent 23-gauge vitrectomy and 36 underwent 25-gauge vitrectomy. They did not find statistically significant difference in post-operative VA at 1 year between the two groups. No cases of retinal detachment or endophthalmitis were registered at 1-year follow-up. The 23-gauge technique was slightly more expensive than the 25-gauge pars plana vitrectomy<sup>7</sup>.

Other studies reported seven patients in the 23-gauge group, compared with three in the 25-gauge group, re-

quired suturing of sclerotomy at the end of the surgery. No patients in either group developed postoperative wound leakage or endophthalmitis<sup>8</sup>.

Gupta et al.<sup>9</sup> reported the incidence of hypotony after 25-gauge pars plana vitrectomy on the first postoperative day 8.1%. The rate of hypotony was 16.7% in uveitis cases and 0% in routine macular surgery<sup>9</sup>.

Witkin et al.<sup>10</sup> reported a significant improvement in VA and central foveal thickness postoperatively. Eyes with lamellar separation of the inner and outer foveal layers preoperatively had worse visual results, whereas eyes with cystoid macular edema or perifoveal VMT had better visual results. A subgroup analysis was performed based on preoperative OCT appearance. Improvement in vision was not significant in eyes with lamellar separation between the inner and outer fovea, but was significant in eyes with cystoid macular edema or perifoveal traction<sup>10</sup>.

## REFERENCES

1. KOVAČEVIĆ D, MARKUŠIĆ V, Coll Antropol, 37 (2013) 271. — 2. MCDONALD HR, JOHNSON RN, SCHATZ H, Ophthalmol, 101 (1994) 1397. — 3. JIANG YR, MA Y, LI XX, 40 (2004) 670. — 4. DUKER JS, KAISER PK, BINDER S, DE SMET MD, GAUDRIC A, REICHEL E, SADDI SR, SEBAG J, SPAIDE RF, STALMANS P, Ophthalmol, 120 (2013) 2611. DOI: 10.1016/j.ophtha.2013.07.042. — 5. PIELEN A, GUERRA NI, BÖHRINGER D, JUNKER B, BÜHLER AD, STAHL A, AGOSTINI HT, EHLKEN C, Eur J Ophthalmol, (2014). DOI: 10.5301/ejo.5000461. — 6. STEEL DH, LOTERY AJ, Eye 27, (2013). — 7. GROSSO A, CHARRIER L, LOVATO E, PANICO C, MARIOTTI C, DAPAVO

## Conclusion

Theoretically, the 25-gauge system should be superior to the 23-gauge because of smaller wound, less risk of leakage and faster healing.

However, the 23-gauge system has a better cutting efficiency, stiffer instruments and still offers suturless approach.

Although morphological postoperative restitution is good, it does not always follow functional recovery of vision.

Our retrospective study suggests that (limited to macular surgery) both 23- and 25-gauge micro incision vitreoretinal surgery for idiopathic ERM and macular holes are equally effective, with similar safety profiles. There was no difference between-group in the degree of postoperative visual recovery. Gauge selection thus may be made according to a surgeon's preference and the availability of appropriate instruments.

G, CHIUMINATTO R, SILIQUINI R, GIANINO MM, Int Ophthalmol, 34 (2014) 217. DOI: 10.1007/s10792-013-9818-3. — 8. NAM Y, CHUNG H, LEE JY, KIM JG, YOON YH, Eye, 24 (2010) 869. DOI 10.1038/eye.2009.206 — 9. GUPTA N, PUNJABI OS, STEINLE NC, SINGH RP, Ophthalmic Surg Lasers Imaging Retina, 44 (2013) 155. DOI: 10.3928/23258160-20130215-01. — 10. WITKIN AJ, PATRON ME, CASTRO LC, REICHEL E, ROGERS AH, BAUMAL CR, DUKER JS, Ophthalmic Surg Lasers Imaging, 41 (2010) 425. DOI: 10.3928/15428877-20100525-07.

D. Kovačević

Department of Ophthalmology, Clinical Hospital Center Rijeka, Krešimirova 42, 51000 Rijeka, Croatia  
e-mail: oftalmologija@kbc-rijeka.hr

## USPOREDBA 23 GAUGE I 25 GAUGE PPV U LIJEČENJU EPIRETINALNIH MEMBRANA I MAKULARNIH RUPTURA

### SAŽETAK

Cilj ove studije bio je prikazati dugoročni postoperativni oporavak poslije zahvata pars plana vitrektomije (PPV) kod bolesnika sa epiretinalnom membranom (ERM) i makularnom rupturom. Htjeli smo pokazati postoji li razlika u operativnom pristupu i ishodu s obzirom na veličinu instrumenata 23-gauge i 25-gauge PPV. Dvadeset i osam bolesnika podvrgnuto je operativnom liječenju idiopatske ERM i rupture makule III i IV stupnja. U našoj studiji nije bilo statistički značajne razlike u vidnoj oštini između 23-gauge i 25-gauge operiranih bolesnika. Iako su obje metode sigurne i dobre, morfološka restitucija ne prati uvijek i funkcionalni oporavak.