

## Recipient Site Necrosis After Tumescent Infiltration with Adrenaline in Hair Transplantation

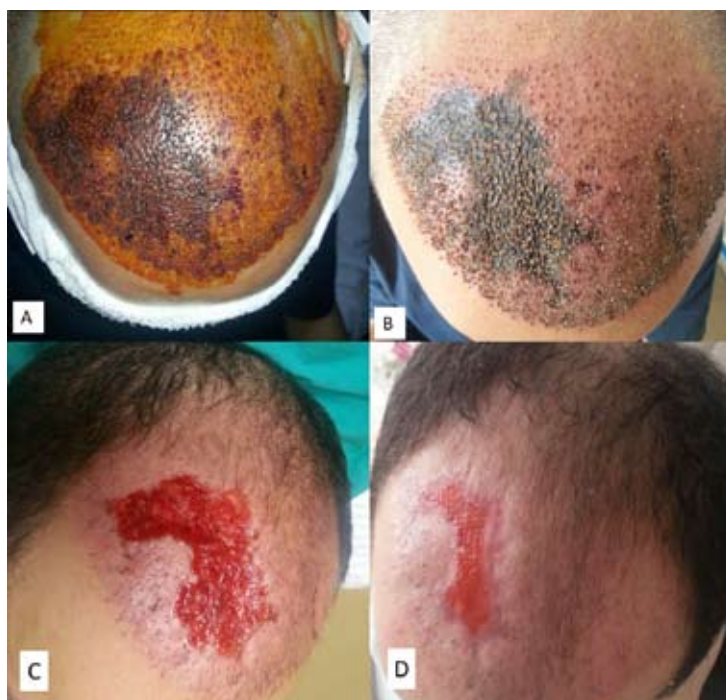
Follicular unit extraction (FUE) is a recent and widely used surgical procedure for hair restoration (1,2). Complications are rarely reported in literature. Herein, we report the first case of recipient site necrosis. We used hyperbaric oxygen therapy (HBOT) as an adjunctive therapy in this patient in order to restrict necrosis area in length and depth and increase wound healing.

A 33-year-old man, referred to our hyperbaric medicine department from a different private hospital due to a scalp necrosis after the hair transplantation surgery, which appeared on the first day after the operation. The plastic surgeon who performed the surgery provided us with the patient history. The patient had suffered hair loss localized to the frontal and vertex areas and was diagnosed with androgenic

alopecia Norwood grade III. He underwent hair transplantation surgery with the FUE technique.

The ring block was administered in the frontal and occipital scalp by using a 31-gauge needle, infiltrating 2% prilocaine hydrochloride with 1:100 000 adrenaline. After ring anesthesia, tumescent saline solution with adrenaline 1:100 000 (1 mL adrenaline / 100 mL saline) was then injected in the entire recipient site to make it turgid.

Approximately 1800 grafts were harvested with a 1 mm punch and were transplanted to the frontal site. Three hours after the surgery, the patient suffered from a pain in the recipient site, and cyanosis was found on examination. The cutaneous lesion then rapidly evolved into a necrotic appearance (Figure 1, a).



**Figure 1.** (a) Appearance of the ischemic findings of the scalp 24 hours after the operation. (b) Recipient site necrosis on the 10<sup>th</sup> day after hyperbaric oxygen therapy (HBOT). (c) Eschar was totally debrided after 3 weeks of treatment with HBOT. (d) The wound was left to secondary healing.

The patient was referred to our hospital for HBOT on the first day after the surgery. On examination, dark purple lesions with irregular borders were observed, especially on the right side of the frontal region. The patient was not a cigarette smoker; standard laboratory tests were normal. The patient was given adjunctive HBOT and topical wound care (wet dressings, antiseptics, and moisturizers). The patient received a total of 10 sessions of HBOT until the end of the second week. A typical 120 minutes HBOT session was comprised of 3×25 minutes of oxygen periods at 2.4 atmospheres absolute (ATA).

Tumescence in the recipient area can be useful to widen the distance from the follicles residing in fat to the nerves and larger blood vessels lying just above the fascia, provide hemostasis, and decrease bleeding. Effective recipient tumescence can be achieved with adrenaline in saline without anesthetic (3). In our case, saline with adrenaline 1:100 000 was used with tumescent infiltration to recipient site after regional block anesthesia.

Adrenaline has potential side effects. Procaine with epinephrine has been reported to cause tissue necrosis in "non-end artery" locations such as the upper lip, scalp, face, leg, buttock, scrotum, abdomen, and patella. Therefore, its use must be carefully considered in patients. Necrosis is a very rare complication of FUE. There is only a single published case report of a necrosis of a donor site (1). Our case shows that the necrosis of recipient site owing to exaggerated vasoconstrictor response to adrenaline in tumescent infiltration. Thus, the patient's previous responses to epinephrine or adrenaline should be checked before the procedure in order to avoid ischemia or necrosis of the scalp.

HBOT, which involves the inhalation of pure oxygen at higher atmospheric pressures, is suggested to have anti-hypoxic, anti-edema, and anti-infective properties (4). In ischemic tissue, HBOT corrects tissue hypoxia by increasing partial oxygen tensions in tissues up to 400-500 mmHg at 2.4 atmospheres absolute (ATA) treatment pressure. Urgent HBOT is needed in ischemia to prevent necrosis or decrease necrotic tissue size in length and depth (5).

In our patient, wound care, topical antibiotic treatment, and adjunctive HBOT were performed over 10 days (Figure 1, b). HBOT may be beneficial in restricting the length and depth of the necrosis. Prospective randomized controlled trials are needed to confirm this hypothesis.

Dry, dark, and leathery eschar was totally debrided after 3 weeks of treatment with HBOT (Figure 1, c). The wound was left to secondary healing (Figure 1, d). Conventional wound care therapy was resumed.

We concluded that necrosis is very rare but serious problem of hair transplantation procedures. Even if seen rarely, possible emergence of ischemic complications must be considered. Doctors and patients need to be aware of this risk.

**ACKNOWLEDGMENTS:** The authors thank Ibrahim Rencüzoğulları, MD, for his contribution while preparing this article.

## References

1. Karaçal N, Uraloğlu M, Dindar T, Livaoğlu M. Necrosis of the donor site after hair restoration with follicular unit extraction (FUE): a case report. *J Plast Reconstr Aesthet Surg* 2012;65:87-9.
2. Gökrem S, Baser NT, Aslan G. Follicular unit extraction in hair transplantation: personal experience. *Ann Plast Surg* 2008;60:127-33.
3. Bernstein RM, Rassman WR. Limiting Epinephrine in Hair Transplant Sessions. In: Unger WP, editor. *Hair Transplantation*, 4th Ed. New York: Marcel Dekker, Inc., 2004:245-250
4. Uzun G, Ozdemir Y, Mutluoğlu M, Gülec B. Hyperbaric oxygen therapy as an adjunct to surgical treatment of extensive hidradenitis suppurativa. *World J Surg* 2010;34:861-2.
5. Jain KK. *Textbook hyperbaric medicine* fourth edition. Range of tissue oxygen tensions (mmHg) with HBO Therapy. Göttingen: Hogrefe & Huber Publishers, 2004. pp. 151-2.

**Hamza Yildiz<sup>1</sup>, Erdinc Ercan<sup>2</sup>, Doğan Alhan<sup>3</sup>, Mehmet Sezgin<sup>4</sup>**

<sup>1</sup>*Department of Dermatology, Eskisehir Military Hospital, 26020 Eskisehir, Turkey*

<sup>2</sup>*Department of Hyperbaric Medicine, Eskisehir Military Hospital, 26020 Eskisehir, Turkey*

<sup>3</sup>*Department of Plastic and Reconstructive Surgery, Eskisehir Military Hospital, 26020 Eskisehir, Turkey*

<sup>4</sup>*Department of Plastic and Reconstructive Surgery, Private Eskisehir Sakarya Hospital, 26020 Eskisehir, Turkey*

## Corresponding author:

Hamza Yildiz, MD  
Department of Dermatology  
Eskisehir Military Hospital  
26020 Eskisehir  
Turkey  
[hamzayildiz@gmail.com](mailto:hamzayildiz@gmail.com)

Received: August 6, 2014  
Accepted: August 10, 2015