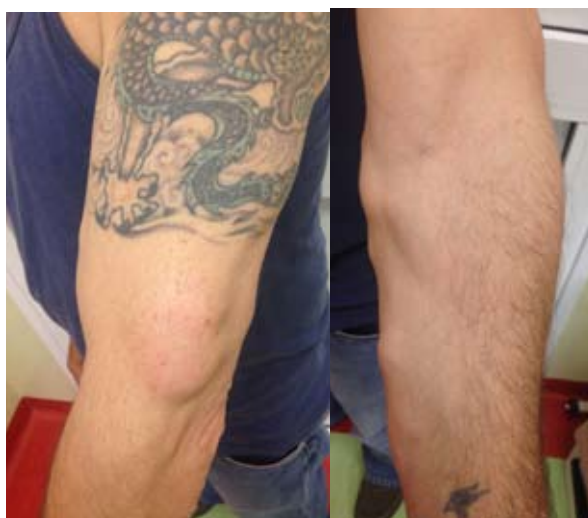

## A Case of Iatrogenic Cutaneous Lipomatosis

Lipomas are the most common type of soft tissue benign tumor with a prevalence of 2.1 per 1000 people (1). They generally occur in adult patients between the ages of 40 and 60 years as solitary lesions. In some cases, however, there can be multiple lipomas involving several members of a family or associated with other systemic manifestations as in some syndromes. Cases of iatrogenic lipomatosis have been reported only rarely (2,3).

We report the case of a man that developed multiple lipomas after making a tattoo. A 45-year-old man presented with multiple, subcutaneous, soft, and mobile skin lesions on the left upper limbs, which had appeared about 2 years earlier (Figure 1). They were of various dimensions, were not painful, and had not recently increased in size. Physical examination found a BMI of 25.9. An ultrasound examination of cutaneous lesions showed multiple oval hyperechoic neoformations with smooth margins between 15 and 35 mm in size. Histological examination of one of the nodules showed mature adipocyte depositions in the subcutaneous tissue (Figure 2).

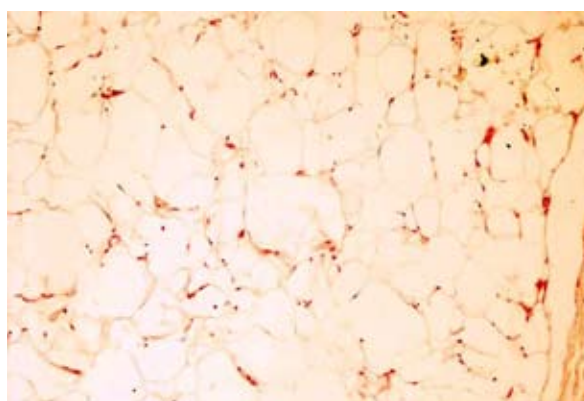
The patient said that these lesions appeared after making a tattoo on his arm. The tattoo was admin-



**Figure 1.** a: Lipomas and tattoo of the arm; b: Lipomas of the arm

istered in a professional studio 2.5 years ago. The familial history was negative for multiple lipomas. He had no significant past medical history. He was a non-smoker and consumed only a moderate amount of alcohol. Complete blood count, liver and kidney function tests, serum protein level, plasma glucose level, triglycerides, and cholesterol were all normal. We excluded pharmaceutical causes such as corticosteroid treatment, prior chemotherapies, and use of other drugs. On the basis of the clinicopathologic findings, the diagnosis of lipomatosis was made.

Lipomas can be either isolated entities or involved in multiple lipomatosis, which are most often associated with specific congenital, familial, or idiopathic syndromes such as Madelung's syndrome (characterized by an accumulation of adipose tissue significantly and symmetrically in the neck, head, and upper trunk which affects mainly males with a history of alcohol abuse) (4), Cowden syndrome (characterized by multiple lipomas and an increased risk of malignancies of the breast, thyroid, endometrium, kidney, and colorectum) (5), Dercum's disease (characterized by painful multiple lipomas which affect mainly women, especially postmenopausally) (6), and familial lipomatosis (characterized by regional excess of subcutaneous adipose tissue in members of the same family) (7).



**Figure 2.** Histological findings of the soft tissue tumor.

Our case had none of the aforementioned etiologies; it was likely an acquired condition induced by some exogenous factors stimulating fat development and subcutaneous accumulation.

The association between lipomas and tattoos may be coincidental, given the great number of people with tattoos nowadays. However, these two conditions may have been linked because the skin was free of any type of lesion before the tattoo and there was a clear chronology between the development of lipomas and the tattoo. Furthermore, lipomas appeared only on the arm where the tattoo was made.

A review of the literature revealed no similar cases of onset lipomatosis. Cases of iatrogenic lipomatosis have been reported after chemotherapy and therapy with Peroxisome proliferator-activated receptor (2,3). In 1998, Signorini and Campiglio suggested the differentiation of mesenchymal precursors (preadipocytes) to mature adipocytes by trauma (8). The inflammatory processes with local release of growth factors, inflammatory mediators, and degradation products could trigger these differentiations. Skin tattooing is a common procedure among different cultures with possible serious complications, such as transmission of hepatitis C and B, AIDS, leprosy, and lupus vulgaris. Other possible complications include mild localized infections and inflammatory responses, generalized inflammatory skin eruptions, and other chronic conditions (9). In our case, the tattoo may have been the trigger for the formation of lipomas of the arm.

Even though this is a preliminary report and further studies are needed, we emphasize the importance of taking a careful clinical history in patients with lipomatosis.

### References

1. Ronan SJ, Broderick T. Minimally invasive approach to familial multiple lipomatosis. *Plast Reconstr Surg* 2000;106:878-80.
2. Bracaglia R, D'Ettoire M, Gentileschi S, Mingrone G, Tambasco D. Multiple lipomatosis after stem cell transplant and chemotherapy: a case report. *Eur Rev Med Pharmacol Sci* 2014;18:413-5
3. Femia A, Klein PA. Letter: Iatrogenic lipomatosis: a rare manifestation of treatment with a peroxisome proliferator-activated receptor gamma agonist. *Dermatol Online J* 2010;16:15.
4. Bergler-Czop B, Wcisło-Dziadecka D, Brzezińska-Wcisło L. Madelung's disease in a patient with chronic renal insufficiency: a case report and review of literature. *Postepy Dermatol Alergol* 2014;31:121-4.
5. Porto AC, Roider E, Ruzicka T. Cowden Syndrome: report of a case and brief review of literature. *An Bras Dermatol* 2013;88:52-5.
6. Miraglia E, Visconti B, Bianchini D, Calvieri S, Giustini S. An uncommon association between Lipomatous Hypertrophy of the Interatrial Septum (LHIS) and Dercum's disease. *Eur J Dermatol* 2013;23:406-7
7. Lee CH, Spence RA, Upadhyaya M, Morrison PJ. Familial multiple lipomatosis with clear autosomal dominant inheritance and onset in early adolescence. *BMJ Case Rep* 2011;17:2011.
8. Signorini M, Campiglio GL. Posttraumatic lipomas: where do they really come from? *Plast Reconstr Surg* 1998;101:699-705.
9. Juhas E, English JC 3rd. Tattoo-associated complications. *J Pediatr Adolesc Gynecol* 2013;26:125-9

**Emanuele Miraglia, Stefano Calvieri,  
Sandra Giustini**

*Sapienza University of Rome, Department of Dermatology, Policlinico Umberto I, Rome, Italy.*

### Corresponding author:

Emanuele Miraglia, MD  
Sapienza University of Rome  
Department of Dermatology  
Policlinico Umberto I  
Viale del Policlinico  
00161 Roma  
Italy  
*emanuele.miraglia@hotmail.it*

Received: January 17, 2015

Accepted: May 20, 2015