



# The application of paravertebral block in high-risk patient with cardiorespiratory, liver and kidney problems: a case report

MIROSLAV ŽUPČIĆ<sup>1</sup>  
SANDRA GRAF ŽUPČIĆ<sup>2</sup>  
ANA BRUNDULA<sup>1</sup>  
IVA KOREČIĆ ZRINJŠČAK<sup>1</sup>  
JASMINKA PERŠEC<sup>1</sup>  
INO HUSEDŽINOVIĆ<sup>1</sup>

<sup>1</sup> Clinic of Anesthesiology, Resuscitation and Intensive Care Medicine, University Hospital Dubrava, Zagreb, Croatia

<sup>2</sup> Clinic of Neurology, University hospital "Sv. Duh", Zagreb, Croatia

## Correspondence:

Miroslav Župčić, MD.  
Clinical Department of Anesthesiology, Resuscitation and Intensive Care Medicine, University Hospital Dubrava, Zagreb, Croatia  
E-mail: [miro\\_zupcic@yahoo.com](mailto:miro_zupcic@yahoo.com)

## Abstract

**Background and Purpose:** We present a case report of a patient of the American Society of Anesthesiologists' (ASA) IV scheduled for a modified radical mastectomy (MRM) due to malignant disease. The patient was a high risk patient for general anesthesia and we opted for the application of unilateral paravertebral block on several levels. **Case report.** A 86-year-old female was scheduled for a surgery due to recurrent malignant process on her right breast. She was an ASA IV patient with chronic obstructive pulmonary disease (COPD GOLD A), respiratory failure, diabetes mellitus, diabetic nephropathy, cirrhosis and chronic laryngitis. Echocardiography showed diastolic dysfunction and pulmonary hypertension of moderate degree. During the preparation for the surgery, an invasive blood pressure measurement was set while the paravertebral space was identified with the neurostimulator using the linear ultrasound probe of 8 Hertz (Hz). The anesthetic [0.5% Levobupivacaine (Chirocaine®, Abbott Laboratories)] was applied in levels of Thoracic (Th) 2, Th3, Th4 and Th5 (5 milliliters (ml.) per level). We used 2% lidocaine [Lidocaine®, FC] for local infiltration at the site of the block.

**Results:** Sensory blockade occurred after 32 minutes (min.) and lasted for about 8 hours (h) with normal perioperative period and hemodynamic parameters without accompanying complications.

**Discussion and Conclusion:** This case report shows that the application of paravertebral block with lower doses of long-acting local anesthetic at several levels leads to a satisfactory anesthetic and analgesic effect while maintaining hemodynamic stability.

## INTRODUCTION

Breast surgeries which involve modified radical mastectomy (MRM) with dissection of the axilla are usually performed under general endotracheal anesthesia with the use of mechanical ventilation. Patients with present significant cardiac and pulmonary problems have a very high risk for the use of general anesthesia. Here we show the American Society of Anesthesiologists' (ASA) IV patient scheduled for modified radical mastectomy (MRM) with malignant disease present. Due to a high risk of general anesthesia, we decided to apply unilateral paravertebral blocks on several levels.

Case report: A 86-year-old, 84 kilograms (kg) in weight and 157 centimeters high (cm.) female was scheduled for a surgery due to a recur-

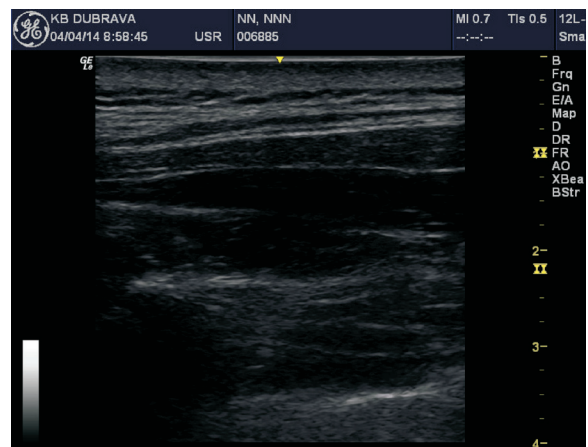
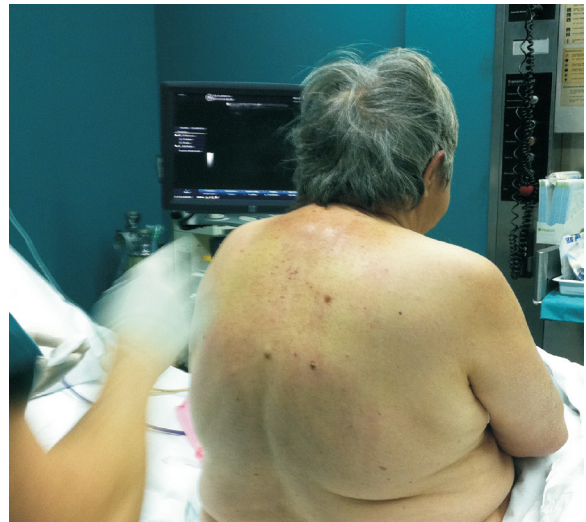rent malignant process on her right breast. She was an ASA IV patient with chronic obstructive pulmonary disease (COPD GOLD A), respiratory failure, diabetes mellitus, diabetic nephropathy, adipositas, cirrhosis and chronic laryngitis. Auscultationally, she had prolonged expiratory phase with basal groan on both sides. Arterial blood gas analysis and spirometry showed obstructive disorders of moderate degree. The X-ray of the heart and lungs showed pronounced interstitial pattern on both sides with shallow lateral phrenicocostal sinuses. Echocardiography showed diastolic dysfunction with ejection fraction of about 50%, with pulmonary hypertension of medium degree. Electrocardiogram showed left ventricular hypertrophy. The patient has a long history of diabetes with insulin therapy accompanied by diabetic nephropathy and liver cirrhosis.

## MATERIALS AND METHODS

Upon the arrival in the perioperative monitoring unit (with prior midazolam medication of 5 milligrams (mg.) intramuscularly (i.m.) in the department) a non-invasive monitoring of heart rate (HR), non-invasive arterial blood pressure (BP), fingertip arterial oxygen saturation (SpO<sub>2</sub>), and the needle cannula were placed on a patient. Then, the arterial cannula was placed with the infiltration of 1ml. 2% lidocaine [Lidocaine®, FC] using the ultrasound surveillance with in plane technique in the left radial artery for invasive pressure measurements. After the adjustment of the patient in the sitting position and aseptic washing of dorsal surface we detected paravertebral space using linear probe of 8 Hz and a depth of 4.5 cm. The skin and subcutaneous tissue were infiltrated with 1 ml. 2% lidocaine [Lidocaine®, Belupo] per level. In order to perform a paravertebral block we used an ultrasound and a neurostimulator with neurostimulating needle [Stimuplex D®, BBraun Melsungen] 22 G, 10 cm in length. We used neurostimulators for the detection of paravertebral space of the initial values of 2 Hz and lowered them to 0.5 Hz with the persistence of muscle contraction. After that, we applied local anesthetic 0.5% Levobupivacaine [Chirocaine®, Abbott Laboratories] with the aspiration on the four levels of Th2, Th3, Th4 and TH5 (5 ml. per level) for analgesic and anesthetic effects.

## RESULTS

Following the administration of a block, the sensory blockade occurred after 32 min and surgical anesthesia in 40 min. The testing of the block was done with pick prick and warm - cold test from the right side of Th 2 to Th 6 dermatoma. During the operative procedure, the patient was sedated with 3 mg. midazolam intravenously (iv) and 50 micrograms (mcg.) of fentanyl iv. All measured vital parameters: heart rate (HR), fingertip arterial oxygen saturation (SpO<sub>2</sub>), invasive arterial blood pressure (BP) were of proper values. The surgical procedure lasted 90



**Figure 1.** Patient position and ultrasound image of local anesthetic spread. N = Neurostimulator needle [Stimuplex D®, BBraun Melsungen]; TP = transverse process; EICM = external intercostal membrane; LA = local anesthetic; PL = pleura

min. without accompanying complications after which the patient was sent in the unit for perioperative monitoring with continuous monitoring of hemodynamic parameters and saturation. After 60 min. of normal hemodynamic parameters, arterial cannula was removed and with the instructions to the staff, the patient was sent to the clinic for plastic surgery. During the first 24 postoperative hours, the patient's pain level was visually monitored using analgesic scales (VAS, 0 = no pain, 10 = worst pain imaginable) every three hours. Sensory blockade lasted 8 hours from the application of the block with VAS = 1. After 8 hours VAS = 3 diclofenac 75 mg. iv was applied once, which results after 30 min. in coupling pain and lowering VAS to 1 without a need for re-application of analgesia in any form. At postoperative interviews 48 h after the operation, the patient was very satisfied with the anesthesiologist treatment and no complications occurred.

## DISCUSSION AND CONCLUSION

This case report shows the application of paravertebral block on ASA IV patient with present significant cardiac, pulmonary, liver and kidney problems. The patient was scheduled for MRM with dissection of the axilla. After the full examination of the patient's condition, we wanted to avoid endotracheal intubation and mechanical ventilation because of possible cardiorespiratory complications. Some of the techniques of regional anesthesia can adequately replace the general endotracheal anesthesia in breast surgeries. One of them is a thoracic epidural anesthesia (TEA) (1,2). This technique can result in bilateral symmetrical anesthesia but also in a sympathetic block and frequent hemodynamic instability (3). Very important side effects such as nausea, vomiting and hypotension were more common in TEA than thoracic paravertebral block (TPVB) (4). There are many papers in favor of anesthesia in breast surgery only in the TPVB or in a combination with general anesthesia (5-7). Tahiri et al. show the results of 11 studies that compared paravertebral blocks with general anesthesia. The research has proven significantly lower pain scores during the first 6 postoperative hours and less requirements for pain relief in patients who had paravertebral block applied (6). Paravertebral blocks proved to be very useful in reducing the development of chronic postoperative pain (8). Although there are many techniques performing paravertebral blocks (9-11), we have, in order to achieve a better precision in sensory blockade, decided to give blocks on several levels using the ultrasound and neurostimulators in plane technique. Therefore, it should be noted that in a single shot block administration the occurrence of very significant problems described as a failed block or epidural spread of local anesthetic (12) is possible. With the frequent use of ultrasound, the application of paravertebral blocks in high-risk patients as a method of choice (13, 14) is becoming more common. We had to take into consideration cardio-respiratory problem in our patient, together with the cirrhosis of the liver. It is known that amino - amide local anesthetics are metabolized in the liver and the worse the perfusion and function of the liver (15, 16) is, the longer their elimination half-life is. In conclusion, by cautious administration of small doses of local anesthetics (5 ml.) at four thoracic paravertebral levels we achieved successful unilateral anaesthetic effect without accompanying cardiorespiratory and metabolic complications.

## REFERENCES

- GROEBEN H<sup>1</sup>, SCHÄFER B, PAVLAKOVIC G, SILVANUS MT, PETERS J 2002 Lung function under high thoracic segmental epidural anesthesia with ropivacaine or bupivacaine in patients with severe obstructive pulmonary disease undergoing breast surgery. *Anesthesiology* 96(3): 536-41
- LYNCH E P<sup>1</sup>, WELCH K J, CARABUENA J M, EBERLEIN T J 1995 Thoracic epidural anesthesia improves outcome after breast surgery. *Ann Surg* 222(5): 663-9
- HORLOCKER T T, WEDEL D J 2000 Neurologic complications of spinal and epidural anesthesia. *Reg Anesth Pain Med* 25(1): 83-98
- DAVIES R G, MYLES P S, GRAHAM J M 2006 A comparison of the analgesic efficacy and side effects of paravertebral vs epidural blockade for thoracotomy—a systematic review and meta-analysis of randomized trials. *Br J Anaesth* 96(4): 418-26
- KARMAKAR M K 2001 Thoracic paravertebral block. *Anesthesiology* 95: 771-80
- TAHIRI Y, TRAN DE Q H, BOUTEAUD J, XU L, LALONDE D, LUC M, NIKOLIS A 2011 General anaesthesia versus thoracic paravertebral block for breast surgery: A meta-analysis. *J Plast Reconstr Aesthet Surg* 64: 1261-9
- SCHNABEL A, REICHL S U, KRANKE P, POGATZKI-ZAHN E M, ZAHN P K 2010 Efficacy and safety of paravertebral blocks in breast surgery: a meta-analysis of randomized controlled trials. *Br J Anaesth* 105(6): 842-52
- KAIRALUOMA P M, BACHMANN M S, ROSENBERG P H, PERE P J 2006 Preincisional paravertebral block reduces the prevalence of chronic pain after breast surgery. *Anesth Analg* 103(3): 703-8
- ABDALLAH F W<sup>1</sup>, MORGAN P J, CIL T, McNAUGHT A, ESCALLON J M, SEMPLE J L, WU W, CHAN V W 2014 Ultrasound-guided multilevel paravertebral blocks and total intravenous anesthesia improve the quality of recovery after ambulatory breast tumor resection. *Anesthesiology* 120(3): 703-13
- NAJA M Z, ZIADE M F, LÖNNQVIST P A 2003 Nerve-stimulator guided paravertebral blockade vs. general anaesthesia for breast surgery: a prospective randomized trial. *Eur J Anaesthesiol* 20(11): 897-903
- MARHOFER P<sup>1</sup>, KETTNER S C, HAJBOK L, DUBSKY P, FLEISCHMANN E 2010 Lateral ultrasound-guided paravertebral blockade: an anatomical-based description of a new technique. *Br J Anaesth* 105(4): 526-32
- NAJA M Z, ZIADE M F, EL RAJAB M, EL TAYARA K, LÖNNQVIST P A 2004 Varying anatomical injection points within the thoracic paravertebral space: Effect on spread of solution and nerve blockade. *Anaesthesia* 59: 459-63
- SERPETINIS I, BASSIAKOU E, XANTHOS T, BALTATZI L, KOUTA A 2008 Paravertebral block for open cholecystectomy in patients with cardiopulmonary pathology. *Acta Anaesthesiol Scand* 52(6): 872-3
- PERSEC J, ZUPCIC M, KORUSIC A, TUDORIC DENO I, HUSEDZINOVIC I 2013 Paravertebral blockade as indication, not as anesthesia choice—two case reports. *Period Biol* 115(2): 275-277
- ROSENBERG P H, VEERING B T, URMEY W F 2004 Maximum recommended doses of local anesthetics: a multifactorial concept. *Reg Anesth Pain Med* 29(6): 564-75
- HADZIC A 2011 Hadzic's Peripheral Nerve Blocks and Anatomy for Ultrasound-Guided Regional Anesthesia (New York School of Regional Anesthesia), 2nd ed. McGraw-Hill Professional.